ANTIFIBROTIC IN GLAUCOMA SURGERY

EHAB M NAFIE; MD
Prof. Ophthalmology
Mansoura University
Egypt

Aim

- The problem (glaucoma, and surgical failure)
- Modulationg of wound healing following glaucoma surgeery
- Antimetabolites and its use in glaucoma surgery
- Complications and adverse effects of MMC

The problem

- Glaucoma is not a static disease.
- It changes over time, and we need to consider this continuum throughout the patient's lifetime.
- We have many options for disease control, from noninvasive medications and laser treatments to minimally and moderately invasive surgical procedures.

Wound Healing After trabeculectomy

- In glaucoma surgery we need to overcome the healing process that threatens surgically created drainage fistulae.
- In functioning blebs, the bleb wall consists of intact conjunctival epithelium overlying a loose collection of connective tissue composed of scattered collagen fibrils, in which clear spaces thought to be microcysts were seen.

Histopathology of filtering blebs

- The microcysts seen in functioning blebs are thought to play a key role in aqueous filtration.
- Aqueous in these microcysts may flow across the conjunctival epithelium into the tear film or may gain direct access to sub-epithelial blood vessels and reenter the systemic circulation in this way.

Clinical Sciences FREE

August 2006

In Vivo Confocal Microscopy of Filtering Blebs After Trabeculectomy

Elisabeth M. Messmer, MD; Daniel M. Zapp; Marc J. Mackert; et al.

The JAMA Network

JAMA Ophthalmology

Filtering bleb with good function.

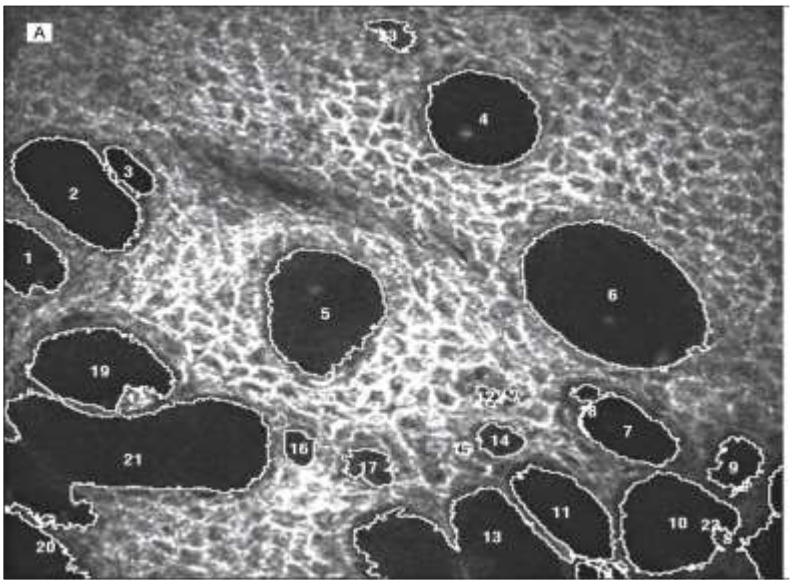

Confocal microscopy of epithelial microcysts

Flat filtering bleb with absence of conjunctival microcysts

Predisposing factors of filtering bleb failure:

- Previous surgery and resulting subconjunctival fibrosis
- Aphakia
- Inflammation
- Previous filtering bleb failure
- Long-term medical therapy
- Neovascular glaucoma
- Intraoperative complications (e.g. iris or ciliary process incarceration in the trabeculectomy fistula).

In contrast, nonfunctioning blebs demonstrate

- dense, thickened collagen, with fibroblasts
- blood vessels,
- no microcysts in the connective tissue underlying the epithelium.

Early signs of a failing filtering bleb:

Gradual IOP elevation during the first 2-4 weeks

- Excessive vascularization of the bleb
- Flattening of the bleb with the disappearance of microcysts in the bleb.

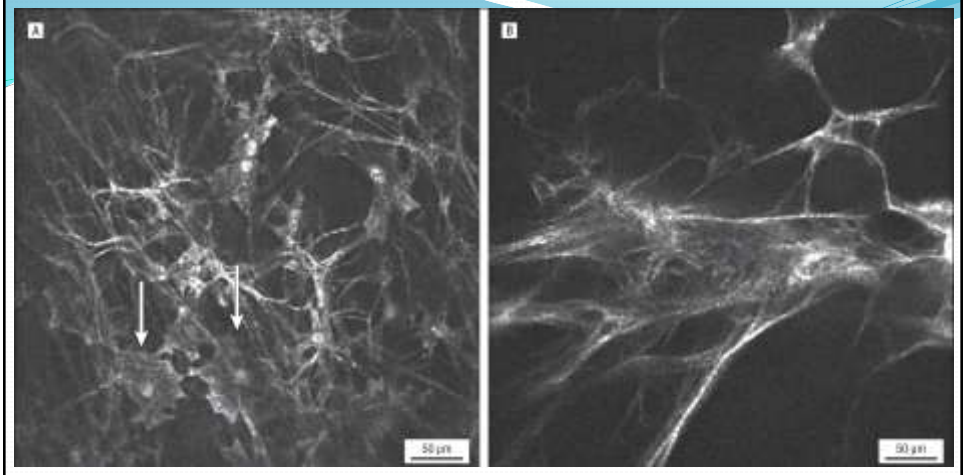

Loose collagen-like meshwork with single fibroblasts (arrows).
B, Rarified collagenlike network with large cystic spaces;

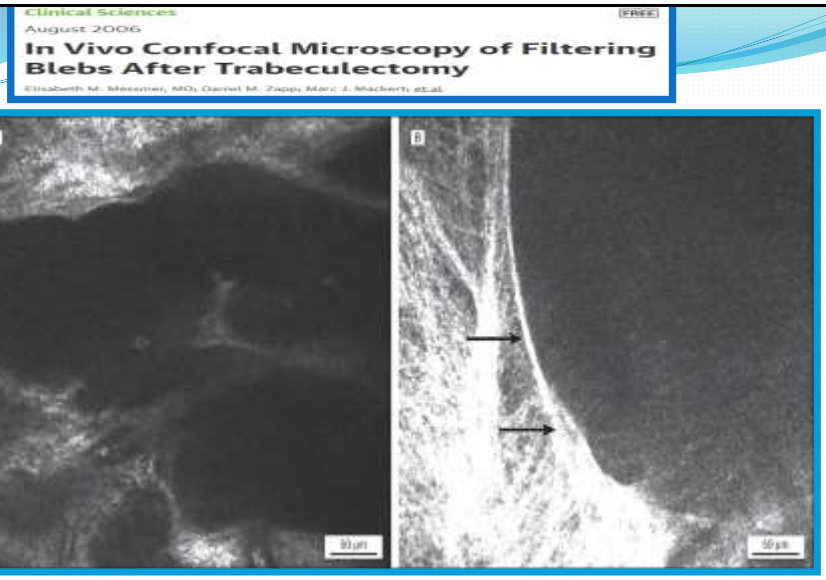

A, Unencapsulated stromal cystic space;
B, Encapsulated cystic space (arrows);

Clinical Sciences

FREE

August 2006

In Vivo Confocal Microscopy of Filtering Blebs After Trabeculectomy

Elisabeth M. Messmer, MD; Daniel M. Zappi; Marc J. Mackert; et al.



Failed filtering bleb,
Condensed and hyper-reflective stroma;

Infammatory Phase (First 4 Days)

- **Tissue trauma resulting from glaucoma filtering surgery leads to constriction of blood vessels and leakage of plasma proteins and blood cells to the extracellular space.**
- **This results in an accumulation of fibrinogen, fibronectin, and platelets.**
- **Owing to the effect of tissue factors like histamine, serotonin, prostaglandins, leukotrienes, and complement factors, a clot of fibrin, fibronectin, platelets, and trapped blood cells is formed.**

Proliferative Phase (5–14 Days)

- Inflammatory cells, including monocytes and macrophages, migrate into the clot.
- The macrophages release factors that stimulate fibroblast migration and proliferation.
- Most fibroblasts secrete procollagen, which in turn is transformed into collagen stabilized by mucopolysaccharides.
- Angiogenesis and fibroblast proliferation result in granulation tissue.

Remodeling Phase (Begins at Day 5)

- This is the last phase of wound healing that begins during the fibroblastic phase and can last for more than a year.
- During this phase, collagen matures and the number of fibroblasts and blood vessels decreases.
- A dense collagenous subconjunctival scar is formed.

Management:

- **Intra- or postoperative anti proliferative therapy (such as 5-fluorouracil or mitomycin-C) to decrease the likelihood of an aggressive postoperative fibroblast-mediated scarring process.**
- **Sub-tenon's corticosteroid injections may be administered intra- or post-operatively.**
- **Selective applications of digital pressure to the bleb should also be considered to promote aqueous flow into the subconjunctival space, thereby elevating the filtration bleb.**

Indications for Antimetabolite Usage in Glaucoma Filtering Surgery

Low-Risk

- No risk factors •
- Long term use of topical medications (β-blockers/pilocarpine) .
- African race.

Intermediate-Risk

- Young age •
- Long term use of topical (adrenaline) •
- Previous conjunctival surgery (cataract extraction, squint/retinal detachment surgery) •
- Several low–risk factors.

High -Risk

- Aphakic glaucoma •
- Neovascular glaucoma •
- Chronic conjunctival inflammation.
- Inflammatory eye disease: uveitis, ocular pemphegoid, Stevens- Johnsons syndrome.
- Previous failed trabeculectomy, or tube.
- Multiple risk factors.

Antimetabolites in Use

- 5 – Fluorouracil (5-FU)
- Mitomycin C (MMC)

5-Fluorouracil (5-FU)

- 5-FU is a pyrimidine analogue that interferes with DNA synthesis, thus blocking cell division, which inhibits fibroblast proliferation and enhances bleb formation and function.
- It can be administered intra or postoperatively.

Intraoperative use

- Administered on bare sclera on a sponge •
- 25 or 50 mg/ml solution,
- Time of exposure should be 3-5 minutes,
- Rinse the surface thoroughly with saline or BSS.

Postoperative use

- Relative contraindication in the presence of corneal epithelial problems,
- 5 mg injections (0.1 ml of 50 mg/ml of undiluted solution.
- Adjacent to the bleb, (but not into the bleb directly), or 180 degree away from the bleb.

- The Fluorouracil Filtering Surgery Study demonstrated lower
- trabeculectomy failure rates with 5-FU compared with controls (51% vs 74%; P < .001), but with a higher rate of bleb leaks (9% vs 2%; P = .032).

Mitomycin C (MMC)

- Mitomycin C is an antimetabolite used as systemic chemotherapy.
- In tissue culture, MMC induces apoptosis of Tenon fibroblasts.
- It is much more potent than 5–FU.

Drug Availability

- MMC is available as powder in strengths of 2, 10, 40 mg.
- It can be administered intra- or postoperatively.
- Intraoperative use
- Concentration: 0.1 to 0.5 mg/ml
- Administered to bare sclera on a sponge,
- Duration of application: 1-5 minutes,
- Avoid contact with cut edges of the conjunctival flap,
- Rinse the surface thoroughly after use,

- Delivery of MMC via a subconjunctival injection prior to fashioning the conjunctival peritomy has recently been described.
- For the first 2 decades of its use to augment glaucoma surgery, MMC was available only as the off-label use of formulations intended for systemic use.
- Recently , the US Food and Drug Administration has approved Mitosol, a commercially available formulation of MMC for ophthalmic use.
- It is supplied as a 0.2-mg/vial dose that can be diluted with sterile water to the desired concentration before use.

Clinical Sciences FREE

August 2006

In Vivo Confocal Microscopy of Filtering Blebs After Trabeculectomy

Elisabeth M. Messmer, MD; Daniel M. Zapp; Marc J. Mackert; et al.

Cystic filtering bleb with good function after trabeculectomy with mitomycin C.

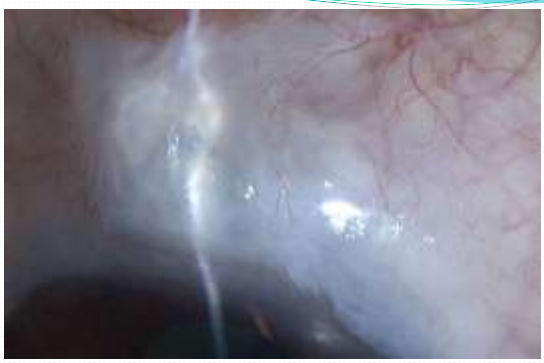

- **Characteristics of antiproliferative-associated filtering blebs:**
  - **Pale**
  - **Avascular (ischemic),**
  - **Localized cystic bleb with surrounding zone of increased vascularity**

Ophthalmology
AMERICAN ACADEMY OF OPHTHALMOLOGY
Protecting Sight. Empowering Lives.

Efficacy and safety of mitomycin-C in primary trabeculectomy

Five-year follow-up

Rajiv Bindlish, MD, Garry P Condon, MD, James D Schlosser, MS, Joyce D'Antonio, PhD, Karen B Lauer, MD, Richard Lehrer, MD

July 2002 Volume 109, Issue 7, Pages 1336–1341

All patients received standard trabeculectomy performed, using a Weck cell-soaked pledget of MMC, 0.25, 0.33, or 0.5 mg/ml, for 0.5 to 5 minutes.

- Mean preoperative and year 5 postoperative (IOP) were 25 and 10 mmHg.
- Hypotony (IOP < 6) occurred in 42.2% of eyes after a mean follow-up of 26 months.
- Hypotony maculopathy occurred in 9% of eyes at mean follow-up of 33 months.
- Bleb leak occurred in 14.6% of eyes at a mean follow-up of 27.9 months.
- Blebitis occurred in 5.7% of eyes at a mean follow-up of 35 months,
- Endophthalmitis occurred in 0.8% of eyes at 15 months; and
- Loss of 4 lines of visual acuity occurred in 14.9% of eyes.

The mean IOP decreased from 27.3 to 15.5 mmHg in group 1 and from 29.0 to 17.5 mmHg in group 2.

The average number of medications decreased from 2.3 and 2.4 to 0.9 and 0.8 ($P = 0.68$; t test) in groups 1 and 2, respectively, at the 12-month visit.

Hypotony was more frequent in group 2.

There was a tendency of more eyes with lower IOP values in group 2.
The rate of loss of visual acuity of more than 2 lines was higher in group 2.
Failures were more frequent in group 2 (7 of 24) compared with group 1 (1 of 24).

Graefe's Archive for Clinical and Experimental Ophthalmology
February 2003, Volume 241, Issue 2, pp 106–110 | Cite as

Five-year results of trabeculectomy with mitomycin C

Authors Authors and affiliations
Henny J. M. Beckers, Katja C. Kinders, Carroll A. B. Webers

Mean reduction in IOP decreased from 22.3±9.3 preoperatively to 12.6±3.5 mmHg postoperatively.
With success defined as an IOP level of 15 mmHg or less, a success rate of 83.3% was obtained in the 1st year, dropping to 60% in the 6th year following trabeculectomy.

Trabeculectomy with Mitomycin C

Outcomes and Risk Factors for Failure in Phakic Open-Angle Glaucoma

Presented at: Association for Research in Vision and Ophthalmology Annual Meeting, May 2005, Ft. Lauderdale, Florida

Hector Fontana, MD, Kouros Nouri-Mahdavi, MD, Joanna Lumba, MD, Monica Ralli, BS, Joseph Caprioli, MD

June 2006 Volume 113, Issue 6, Pages 930–936

- **Mean IOP decreased from 18.8 mmHg (±6.1 mmHg) before surgery to 11.3 mmHg (±4.5 mmHg) at 1 year and 11.1 mmHg (±4.2 mmHg) at 3 years (P<0.001 for both).**
- **The mean number of medications decreased from 2.8 (±1.0) to 0.4 (±0.7) at 1 year and 0.7 (±1.0) at 3 years (P<0.001 for both).**
- **The success rates were 85% at 1 year ; and 62%, at 3 years.**

Journal of Glaucoma

Long-term Follow-up of Initial Trabeculectomy With Mitomycin C for Primary Open-angle Glaucoma in Japanese Patients

Shigeeda, Takashi MD*; Tomidokoro, Atsuo MD*; Chen, Yi-Ning MD*; Shirato, Shiroaki MD†; Araie, Makoto MD*

Journal of Glaucoma: June 2006 - Volume 15 - Issue 3 - p 195-199

The mean follow-up time was 6.8±1.4.
At 8 years, bleb leak occurred in 7.9% of eyes, long-standing hypotony in 8.3%, and, bleb-related infections in 5.9±2.4%.

British Journal of Ophthalmology BMJ

PMC full text: Br J Ophthalmol. 2004 Jul; 88(7): 873–876.
doi: 10.1136/bjo.2003.034256

Figure 1

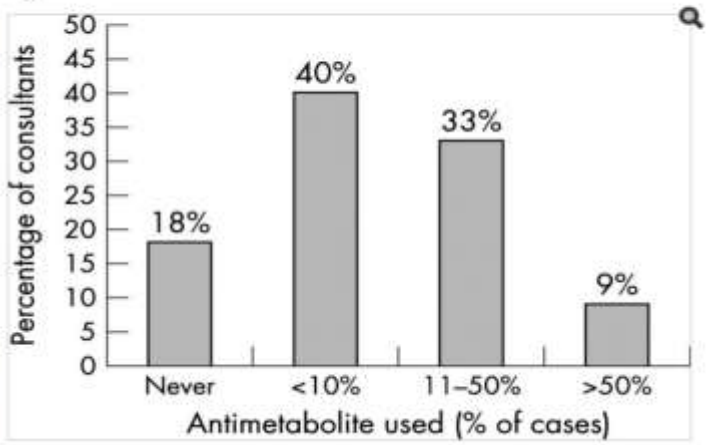

Frequency of antimetabolite use in trabeculectomy.

British Journal of Ophthalmology
BMJ

PMC full text: Br J Ophthalmol. 2004 Jul; 88(7): 873–876.
doi: 10.1136/bjo.2003.034296

Figure 2

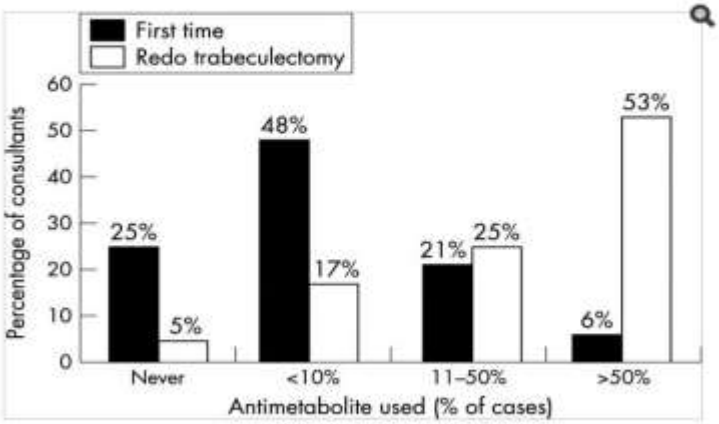

Frequency of antimetabolite use in first time and redo trabeculectomy.

British Journal of Ophthalmology
BMJ

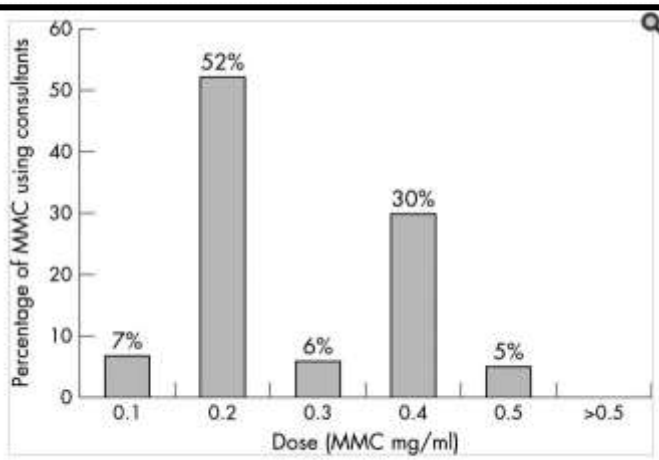

Concentration of MMC used.

British Journal of Ophthalmology
BMJ

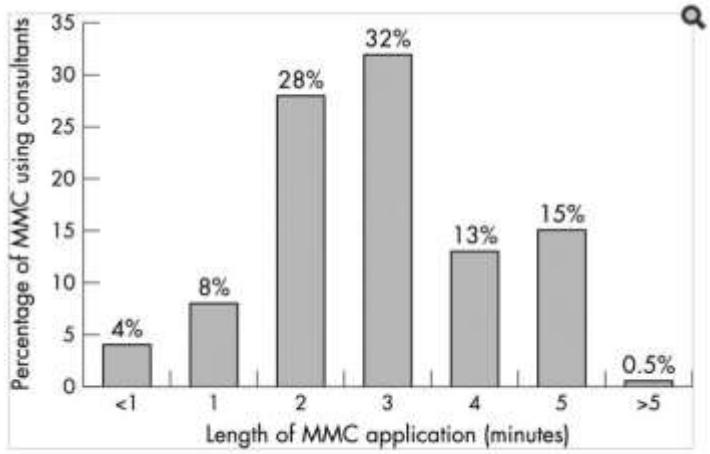

Time of MMC application.

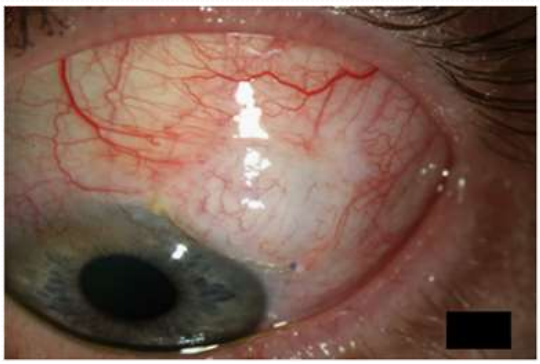

Filtering bleb of a (MMC) trabeculectomy 12 months after surgery.
The bleb shows abortive vessels and some avascular areas typical for MMC blebs.

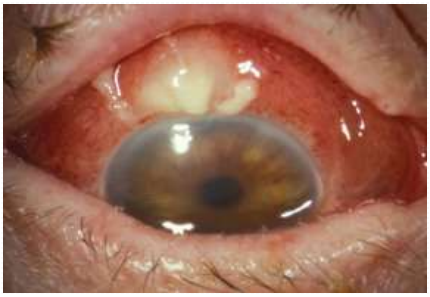

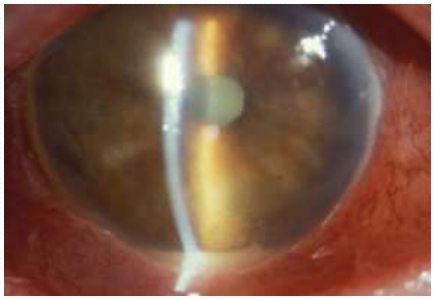

Blebitis with decreased vision after 3 months following trabeulectomy with MMC

Ophthalmology

AMERICAN ACADEMY™ OF OPHTHALMOLOGY
Protecting Sight. Empowering Lives.

Trabeculectomy with intraoperative mitomycin C versus 5-fluorouracil☆

Kuldev Singh, MD, Kala Mehta, DSc, Nazli M Shaikh, MD, James C Tsai, MD, Marlene R Moster, MD, Donald L Budenz, MD, David S Greenfield, MD, Philip P Chen, MD, John S Cohen, MD, George S Baerveldt, MD, Saad Shaikh, MD the Primary Trabeculectomy Antimetabolite Study Group

December 2000 Volume 107, Issue 12, Pages 2305–2309

5-Fluorouracil and MMC were found to be equally safe and effective adjuncts to primary trabeculectomy in the short- and medium-term postoperative periods.

Ophthalmology
AMERICAN ACADEMY OF OPHTHALMOLOGY

Cystic bleb formation and related complications in limbus-versus fornix-based conjunctival flaps in pediatric and young adult trabeculectomy with mitomycin C☆

Anthony P Wells, FRANZCO, M Francesca Cordero, PhD, FRCOphth, Caley Bunce, MBBS, Peng T Khaw, PhD, FRCOphth

November 2003 Volume 110, Issue 11, Pages 2192–2197

In pediatric and young adult trabeculectomy with high doses of MMC, limbus-based flaps may be more likely to develop serious bleb-related complications and may develop these earlier than fornix-based flaps.
The higher rates of complications could be attributable to the differences in bleb morphology, with limbus-based flap cases more likely to develop cystic blebs.

IJO Indian Journal of Ophthalmology

Indian J Ophthalmol. 2018 Jan; 66(1): 66–70. PMCID: PMC5778585
doi: 10.4103/ijo.IJO_543_17

Comparison of surgical outcomes between canaloplasty and trabeculectomy with mitomycin C at 2-year follow-up: A longitudinal cohort study

Winston J Garris, Crystal Le, David Zurakowski,[1] and Ramesh S Ayyala

Canaloplasty and trabeculectomy both achieved significant reduction in IOP with comparable success rates.
Trabeculectomy patients had a greater mean reduction of IOP compared to canaloplasty patients (12.2 vs. 4.7) and also achieved lower IOP at 24 months (12.2 vs. 14.9).

IJO Indian Journal of Ophthalmology

Postoperative glaucoma medication use was less in the trabeculectomy group compared to those in whom canaloplasty was performed,

VA showed no statistical change in either group over 2 years.

Overall failure rates at 2 years were comparable between the two groups: 32% for trabeculectomy and 26% for canaloplasty.

Subgroup analysis revealed a lower failure rate in Caucasions (15%) when compared to Blacks (42%) and Hispanics/others (50%).

Ophthalmology AMERICAN ACADEMY OF OPHTHALMOLOGY

Comparison of Surgical Outcomes Between Canaloplasty and Trabeculectomy at 12 Months' Follow-Up

Ramesh S. Ayyala, Amina L. Chaudhry, Carola B. Okogbaa, David Zurakowski
Ophthalmology, Vol. 118, Issue 12, p2427–2433

The mean percentage reduction in IOP from preoperative values at 12 months after surgery was 32% for the canaloplasty group compared with 43% for the trabeculectomy group .

The median reduction in the number of medications at 12 months' follow-up was 3 in the trabeculectomy group and 2 in the canaloplasty group.

A higher percentage of patients treated with canaloplasty than trabeculectomy (36% vs. 20%) required postoperative medications.

Failure based on IOP was 12.1% for the canaloplasty group and 4.3% for the trabeculectomy group.

Ophthalmology
AMERICAN ACADEMY OF OPHTHALMOLOGY
Protecting Sight. Empowering Lives.

Long-term follow-up of initially successful trabeculectomy with 5-fluorouracil injections[1] ☆

Ricardo Suzuki, MD, Christopher J Dickens, MD, Andrew G Iwach, MD, H Dunbar Hoskins Jr, MD, John Hetherington Jr, MD, Richard P Juster, PhD, Patricia C Wong, MD, Martha T Kiuttas, BS, Clifford J Leong, BS, Ngoc Nguyen, MD

October 2002 Volume 109, Issue 10, Pages 1921–1924

If an eye is considered successful by IOP at 1 year, the probability of successful control is 61% at 5 years, 44% at 10 years, and 41% at 14 years.

Ophthalmology
AMERICAN ACADEMY OF OPHTHALMOLOGY
Protecting Sight. Empowering Lives.

Intraocular Pressure Outcomes and Risk Factors for Failure in the Collaborative Bleb-Related Infection Incidence and Treatment Study

Osaku Sugimoto, MD, PhD, Hideki Mochizuki, MD, PhD, Shinji Ohkubo, MD, PhD, Tomomi Higashide, MD, PhD, Kazuhisa Sugiyama, MD, PhD, Yoshiaki Kiuchi, MD, PhD

November 2015 Volume 122, Issue 11, Pages 2223–2233

**Trabeculectomy with mitomycin C is an effective and safe procedure for reducing IOP.
The number of previous glaucoma surgeries, preoperative lens status and IOP, the needling procedure, and cataract surgery after trabeculectomy influenced the success rate, as determined by the target IOP.**

Ophthalmology
AMERICAN ACADEMY OF OPHTHALMOLOGY

Intraocular Pressure Outcomes and Risk Factors for Failure in the Collaborative Bleb-Related Infection Incidence and Treatment Study

Osaku Sugimoto, MD, PhD, Hideki Mochizuki, MD, PhD, Shinji Ohkubo, MD, PhD, Tomomi Higashide, MD, PhD, Kazuhisa Sugiyama, MD, PhD, Yoshiaki Kiuchi, MD, PhD

November 2015 Volume 122, Issue 11, Pages 2223–2233

- The improved efficacy of trabeculectomy augmented with antifbrotic agents comes at a cost.
- Suppression of the fibroblastic response to surgical trauma can produce a thinner bleb and lower IOP, but the thin-walled bleb is prone to leaks, which in turn increases the risk of hypotony, hypotony maculopathy, and infections, including blebitis and endophthalmitis.

British Journal of Ophthalmology

British Journal of Ophthalmology 2008;92:1666-1670.

Nine-year follow-up of trabeculectomy with or without low-dosage mitomycin-c in primary open-angle glaucoma

A Reibaldi, M G Uva, A Longo

MMC-treated eyes had a lower mean IOP (13.33 vs 14.72); in this group, an higher percentage of eyes had IOP⩽18 mm Hg (73.1% vs 51.1%,) and,
IOP⩽14 mm Hg (56.7% vs 31.9%,);
a lower rate had further glaucoma surgery (9% vs 25.5%,), and
visual-field damage progression (21.1% vs 48.6%,).
No difference was seen in the complication rate: one MMC-treated eye developed blebitis.

Ophthalmology

AMERICAN ACADEMY OF OPHTHALMOLOGY

The 5-Year Incidence of Bleb-Related Infection and Its Risk Factors after Filtering Surgeries with Adjunctive Mitomycin C

Collaborative Bleb-Related Infection Incidence and Treatment Study 2

Tetsuya Yamamoto, MD, PhD, Akira Sawada, MD, PhD, Chihiro Maeyama, MD, PhD, Makoto Araie, MD, PhD, Shiro Ohkubo, MD, PhD, Kazuhisa Sugiyama, MD, PhD, Yasuaki Kuwayama, MD, PhD on behalf of The Collaborative Bleb-Related Infection Incidence and Treatment Study Group

May 2014 Volume 121, Issue 5, Pages 1001–1006

The incidence of bleb-related infection was 2.2% at the 5-year follow-up in eyes treated with mitomycin C–augmented trabeculectomy

No differences were found between the trabeculectomy cases and the combined surgery cases or between cases with a fornix-based flap and those with a limbal-based flap

A history of bleb leakage and younger age were risk factors for infections.

Take-Home Points

- The use of antimetabolites such as MMC can favorably modulate wound healing and improve surgical success rates.
- Surgical failure due to excessive wound healing is a common complication of all bleb-based procedures.
- The use of MMC can increase the risk of complications associatedwith bleb-based procedures, so it must be used with caution.

Complications of Antimetabolite use In glaucoma surgery

Corneal epithelial toxicity

- The most common side effect of post-operative use of 5-FU is corneal epithelial toxicity.
- It occurs in 50% of eyes.

Complications related to bleb morphology

- The use of MMC is associated with thin, cystic, avascular conjunctival blebs.
- Excessive filtration appears to be related post-operative hypotony
- Aqueous hyposecretion is another cause of ocular hypotony followint use of MMC,

Intraocular Toxicity of MMC

- Marked corneal endothelial loss,
- Corneal stromal necrosis,
- Anterior chamber reaction,
- Hemorrhagic iris stromal necrosis.
- Long-onset bleb leak

Long- onset bleb leaks

- It is more common with the use of MMC than with 5-FU,
- They are more commonly associated with endophthalmitis,

Recent advances

- Of all the growth factors involved in the wound-healing cascade, transforming growth factor-beta (TGF-β) has been shown to be one of the most potent stimulators of conjunctival fibroblast proliferation.
- ***lerdelimumab***, a monoclonal antibody to TGF-β2 has shown to be effective in preventing progression of fibrosis in patients undergoing first-time trabeculectomy for primary open-angle or chronic angle closure glaucoma.