Puncto-Canalicular Microsurgery

By
Ossama T Nada

Lecturer of Ophthalmology Ain Shams University
MD, PhD, FRCSG

Egyptian Ophthalmological Society Meeting 2018

Anatomy of the Lacrimal system

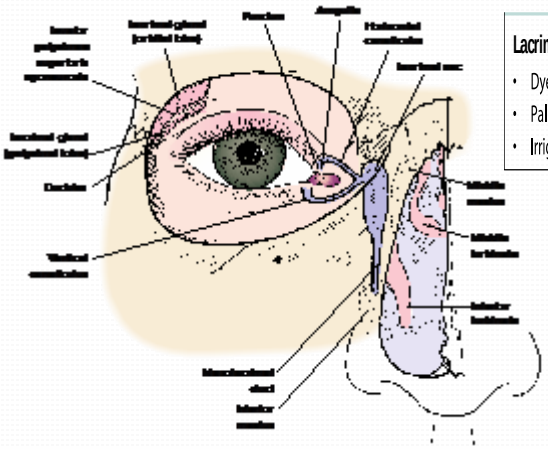

Lacrimal System Vital Signs

- Dye disappearance test
- Palpation of canaliculi
- Irrigation of lacrimal system

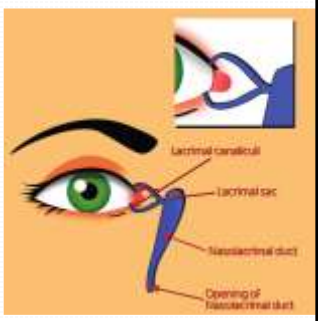

Normal Punctal Appearance

Table 1. Score scale of epiphora.

Score	Description	Clinical findings
0	No epiphora	No tearing
1	Mild epiphora	Tearing sometimes in windy days
2	Moderate epiphora	Always tearing, but sometimes need to wipe
3	Permanent epiphora	Always tearing and need to wipe

Table 2. Grading of punctal orifice.

Grade	Clinical findings
0	No punctum(agenesis)
1	Papilla is covered with a membrane(difficult to recognise)
2	Less than normal size but recognisable
3	Normal (easily recognised)

Table 3. Grading of fluorescein dye disappearance test.

Grade	Fluorescein dye disappearance time
1	<3 min
2	3–5 min
3	>5 min

Punctal Stenosis:

Definition:

Punctal diameter less than 0.3 mm or the inability to intubate the punctum with a 26 G cannula (outer diameter 0.47 mm) without dilation requiring probing with a punctal finder, followed by a standard punctal dilator, in order to insert a 00 Bowman probe.

Measurement of the punctal size

- Photographing via Slit lamp Biomicroscopy coupled with microruler standardized photography of the puncti. Punctal area is determined by software- driven computer analysis.
- Fitting different gauge cannulae (20–32 G)
- Anterior segment OCT.
- Punctal diameter range from 0.2 mm to 0.5 mm (average 0.33mm)

Research Article

Evaluation of the Lower Punctum Parameters and Morphology Using Spectral Domain Anterior Segment Optical Coherence Tomography

Riham S. H. M. Allam and Rania A. Ahmed

Ophthalmology Department, Kasr El Aini School of Medicine, Cairo University, Cairo, Egypt

Correspondence should be addressed to Rania A. Ahmed; ransalam@gmail.com

Received 11 February 2015; Revised 13 April 2015; Accepted 20 April 2015

Academic Editor: Majid M. Moshirfar

Table 1: Punctal and lower lacrimal parameters in both eyes of the examined group.

Parameter	Rt		Lt		*P* value
	Mean (um)	±SD	Mean (um)	±SD	
Clinical measurement	496.45	105.207	492.68	93.945	0.365
Outer diameter	424.65	170.546	404.25	159.139	0.416
Inner diameter	234.35	144.375	238.80	134.416	0.819
Depth	250.44	109.880	249.56	142.599	0.965
TMH	286.13	176.631	295.90	194.949	0.091
TMA (mm^2)	0.04201	0.056719	0.05393	0.181726	0.070

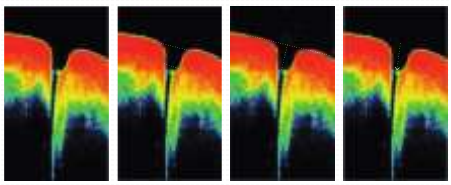

(a) (b) (c) (d)

Published 2015

Characterizing the lacrimal punctal region using anterior segment optical coherence tomography

Hannah M. Timlin,[1] Pearse A. Keane,[2] Alexander C. Day,[2] Tahrina Salam,[1] Mohammed Abdullah,[1] Geoffrey E. Rose[1,2] and Daniel G. Ezra[1,2]

[1]Lacrimal Clinic, Moorfields Eye Hospital, London, UK
[2]NIHR Biomedical Research Centre for Ophthalmology, Moorfields Eye Hospital NHS Foundation Trust and UCL Institute of Ophthalmology, London, UK

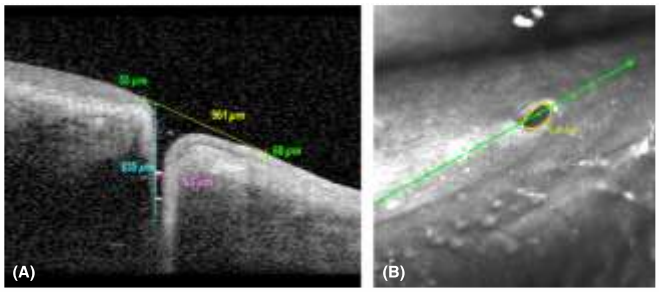

Fig. 3. The punctum dimensions measured were as follows: (A) External punctum opening (yellow line), internal punctal opening at 500 μm depth (purple line), punctum depth (blue line) and epithelial thickness (green lines) from the optical coherence tomography (OCT) image. (B) Punctum opening area (yellow circle) and maximum punctum diameter from the infrared image.

Published 2016

Clinical Grading Of Punctal Stenosis

Grade	Clinical signs
0	No papilla and punctum (punctal atresia) Surgery is needed to create a papilla
1	Papilla is covered by a membrane; Exudative or true membrane or fibrosis difficult to recognize with a standard punctum dilator, a 25-G needle, followed by a punctal finder
2	Less than normal size, but recognizable A punctal finder, followed by a standardized punctum dilator required
3	NormalRegular punctum dilator required
4	Small slit (<2 mm) No intervention required
5	Large slit (≤2 mm) No intervention required

Grade clinical finding on slit-lamp examination; insertion method for a Bowman probe number 00.

Incidence:

Still unknow from 8% to 54.3%, depending on setting, demographics, and probably interob- server variability.

Risk Factors:

- Old age (mean age at diagnosis was 69.4 years)
- Female gender (Postmenopausal Hormone Changes)
- Chronic Blepharitis

Etiology of Acquired punctal stenosis

- Involutional
- Inflammatory: Chronic Blepharitis, Malposition
- Infectious: Chlamydia T, Actinomycis I, HSV, HPV
- Topical Medications: Antiglaucoma drops,Tobramycin, Naphazoline, Mitomycin C
- Systemic Medications: 5FU, Docetexal
- Neoplastic: Peripunctal tumours
- Systemic diseases: Porphyria cutanea tarda
- Others: Irriadiation, Photodynamic therapy
- Trauma:
- Idiopathic

Treatment

Stenting

- Perforated Punctal Plugs
- Mononcanalicular stent
- Bicanalicular stent

Surgical (Punctoplasty)

- One Snip Punctoplasty
- Two Snip punctoplasty
- Three Snip Punctoplasty
- Canalicular Reconstruction

Perforated Punctal Plugs:

- Success rate 84.1%
- Plugs extracted after 2-6 months
- PVP are superior to silicone

Management of acquired punctal stenosis with perforated punctal plugs
Ozlen Rodop Ozgur; Levent Akcay; Nesrin Tutas; Onur Karadag.

Minimonoka Puncto-canaliculoplasty:

- Reduce the rate of stent migration
- For cases of combined punctal and canalicular stenosis (45% of patients)
- Had 85% functional success and 96.2% anatomical success

Balloon dilation:

- The method of balloon dilation has been described for the treatment of common canalicular stenosis.

Puncto-canalicular Snip Procedures

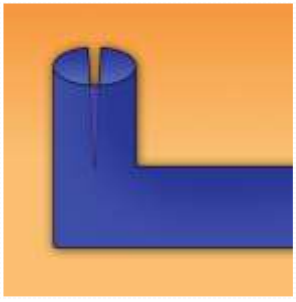

One Snip

does not yield long-term success in alleviating symptoms.

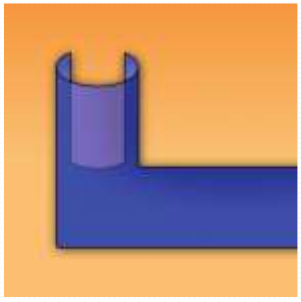

Two Snip

Anatomical success rate 91%
Functional success rate: 71.4%

Three Snip

Anatomical success rate 94.1%
Functional success rate: 62.5%

Punctal stenosis: definition, diagnosis, and treatment. Uri Soiberman,Hirohiko Kakizaki,Dinesh Selva, Igal Leibovitch.

Canalicular reconstruction

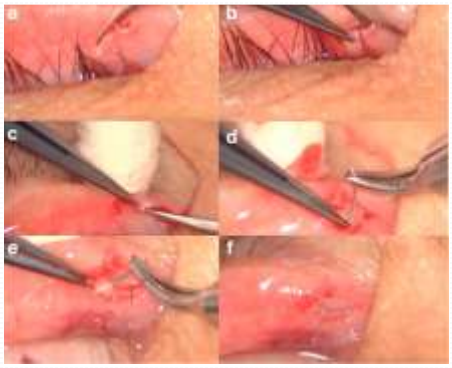

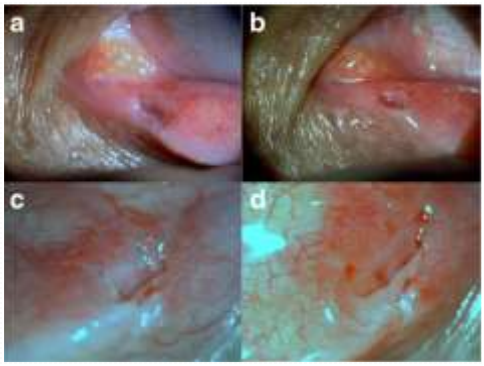

Functional Success Rate 91.7%

A novel surgical technique for punctal stenosis: placement of three interrupted sutures after rectangular three-snip punctoplasty.
Seong Jun Park, Ju Hee Noh, Ki Bum Park, Sun Young Jang,and Jong Won Lee.

THANK YOU

Acknowledgement to:

- Prof Dr. Sherif Elwan
- Dr Yasser Khan McMaster Oculoplastic fellowship director
- Jeffrey Nerad's: Techniques in Ophthalmic Plastic Surgery: A Personal Tutorial.