

# OPTIC NERVE DISORDERS

## OPTIC NEUROPATHIES

### INFLAMMATORY OPTIC NEUROPATHIES

- Cat scratch disease.
- Lyme disease.
- Viral infections of childhood (measles, mumps, chicken pox) with or without encephalitis
- Immun- mediated (Postviral, paraviral).
- Infectious mononucleosis
- Herpes zoster
- Contiguous inflammation of meninges, orbit, sinuses
- Granulomatous inflammations (syphilis, tuberculosis, cryptococcosis, sarcoidosis)
- Intraocular inflammations.

## INFLAMMATORY OPTIC NEUROPATHIES

- Many different inflammatory conditions afflict the optic nerves, confounding nonchalant differential considerations beyond simple MS.
- These causes embrace an exhausting range of possibilities that tax determinations of specific clinical diagnosis (Joel Glaser) .

## IMMUNE MEDIATED OPTIC NEUROPATHIES

## Parainfectious Optic Neuritis

- It is associated with different viruses.
- It follows viral infections onset by 1-3 weeks.
- It is more common in children than in adults.
- It is felt to occur by an immunologic process that produces demyelination of the optic nerve.
- Neuropathy may be unilateral, but often bilateral.
- The optic discs may appear normal or swollen

## Parainfectious Optic Neuritis

- Retinal involvement (neuroretinitis) is common when the disc is swollen.
- It may be associated with a meningo-encephalitis that may be seen on MRI with CSF pleocytosis.
- Visual recovery neuritis usually is excellent, even with no treatment.
- The value of steroids is unknown, but should be considered, particularly if visual loss is bilateral and severe.

## Parainfectious Optic Neuritis

- It is associated with chickenpox, rubella, rubeola, mumps, herpes zoster, and mononucleosis and may simulate acute disseminated encephalomyelitis.
- They are referred to as parainfectious, as opposed to direct tissue infiltration by microbial agents.

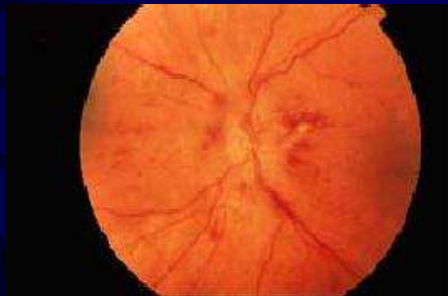
## Postvaccination Optic Neuritis

- Encephalitis with optic neuritis may develop subsequent to **vaccination for polio, measles-mumps-rubella, hepatitis, or diphtheria-tetanus-pertussis.**
- Of special interest are reports of optic neuritis after **influenza vaccination**, attributed to allergic cross-reaction to viral antigens or to immune-mediated vasculitis.

## Bee Sting Bilateral Optic Neuritis.

- It is an undoubtedly immune-mediated form of bilateral optic neuritis reported following bee sting.
- In such instances, visual loss is typically **bilateral and severe**, occurring 10 days to 2 weeks after dermatologic signs (or envenomization), such delay suggesting an autoimmune cascade mechanism.
- In general, complete visual recovery is anticipated, although corticosteroid therapy may be indicated.

## Bee Sting Bilateral Optic Neuritis



## Optic neuritis In SLE and Other Vasculitides

- Optic neuritis may occur in systemic lupus erythematosus (SLE), polyarteritis nodosa (PAN), and other vasculitides.
- Involvement of the optic nerve occurs in about 1% of patients who have SLE.
- Rarely, the disease presents with optic neuropathy.
- The pathogenesis is related to ischemia, which may produce demyelination alone, axonal necrosis, or a combination of the two.

## Optic neuritis In SLE and Other Vasculitides

- The clinical profile takes several forms:
  - **Acute optic neuritis (both papillitis and retrobulbar neuritis),**
  - **Acute ischemic optic neuropathy, and**
  - **Chronic progressive neuropathy.**
- Diagnosis of SLE as a cause of optic neuropathy is established by identification of systemic symptoms and signs of the disease, and by serologic testing.
- Treatment with corticosteroids is indicated.

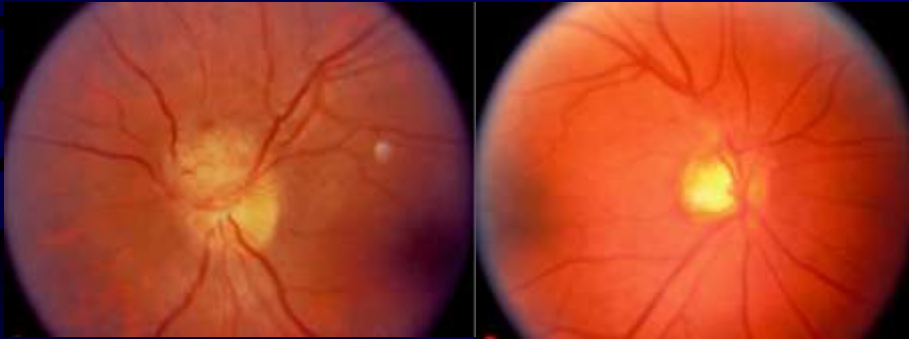
## Autoimmune Optic Neuritis?

- The term autoimmune optic neuritis has been suggested for cases of optic neuritis in which serologic evidence of vasculitis exists, such as positive antinuclear antibodies (ANA), but no signs of systemic involvement other than the optic neuropathy.
- It may be steroid responsive and steroid dependent (flares when corticosteroids are tapered)

## Sarcoidosis

- Granulomatous inflammation of the optic nerve may occur in sarcoidosis.
- Occasionally, optic nerve involvement may be the presenting sign of the disorder.
- Clinical findings may simulate from MS.
- The optic disc may have a **characteristic lumpy, white appearance, which suggests granulomatous infiltration.**
- Recovery after corticosteroid treatment has been instituted. **Subsequent deterioration with corticosteroids tapering suggests sarcoidosis.**

## Sarcoidosis



## Chronic Relapsing Inflammatory Optic Neuropathy (CRION)

- Kidd et al., 2003, described a form of bilateral and often painful inflammatory optic neuropathy characterized by relapses and remissions.
- MRI scans of the brain are normal.
- The symptoms and signs respond well to corticosteroid treatment, although long-term immuno suppression is often necessary.
- The syndrome behaves as a granulomatous optic neuropathy, but during a median follow-up of 8 (2–26) years in no case has evidence for systemic sarcoidosis been identified.



## Mediterranean Fever

- Familial Mediterranean fever (recurrent poly-serositis), an autosomal recessive disorder.
- It is reported to produce uveitis, retinal detachment, or optic neuritis.
- The optic neuritis in this disease behaves like demyelinating neuritis.

## INFECTIVE OPTIC NEUROPATHIES

## HIV-Associated Optic Nerve Disease

- The impact of HIV infection and AIDS has most palpably altered the modern etiologic spectrum of optic neuropathies associated with infectious agents.
- HIV-associated optic nerve disease may be related to **tumor compression, infiltrations such as lymphoma, vasculitides, inflammations, and especially secondary infections.**
- Opportunistic infectious agents regularly invade the retina, optic nerve, meninges, and brain, and co-existing multiple infections further confound diagnosis and management.

## HIV-Associated Optic Nerve Disease

- Optic Neuropathies in Immunodeficiency
  - Papilledema (raised ICP)
  - Cryptococcal meningitis
  - Toxoplasmosis                      - Lymphoma
  - Cryptococcosis
  - Syphilis (perineuritis form)
  - Cytomegalovirus                      - Pneumocystis carinii
  - Human immunodeficiency virus ?
  - Histoplasmosis                      - Varicella

## Optic Neuritis Associated With Syphilis

- Optic neuritis from syphilis has become more common since the increase in (HIV) infection.
- It may be unilateral or bilateral.
- **Neuroretinitis**, typically, show *some cellular reaction occurs in the vitreous*, which differentiates syphilis from demyelinating optic neuritis.
- Diagnosis is established with positive syphilis serology in the serum and usually in the CSF.
- Treatment with penicillin produces visual recovery; however, recurrences are possible.

## Optic Neuritis Associated With Syphilis

- **Syphilitic neuroretinitis, papillitis, and "perineuritis"** are clinical manifestations of secondary stage and neurorecurrence.
- *Optic "perineuritis"* involves primarily the optic meninges, with relative sparing of central core of the nerve and preservation of central function.
- Slowly progressive atrophy evolves in tertiary stage.
- Papilledema may precede meningo-encephalitis.
- Uncomplicated "retro-bulbar" neuritis, so common otherwise, must be extremely rare in syphilis

## Viral Neuritis

- Cytomegalovirus (CMV) retinitis with spread to the nerve, or as an initial papillitis, is associated with poor visual outcome even with therapy.
- Herpes Zoster Ophthalmicus, may be associated with optic neuritis, either in the retro-bulbar form or with a severe ischemic papillitis.
- In immune-compromised patients, varicella-zoster optic neuropathy may precede retinal necrosis, or it is more usually delayed.
- The efficacy of acyclovir and corticosteroids is variable. With perineuritis and perivasculitis, poor visual outcome is the rule.

## Cryptococcosis

- Cryptococcosis may be associated with chronic optic meningitis, with insidious or rapid vision loss related to severe hemorrhagic disc swelling and fulminant nerve necrosis.
- Optic nerve sheath decompression for raised CSF pressure in cryptococcal meningitis has been reported to improve function.

## Cat-Scratch Neuritis (Neuroretinitis) (CSD)

- Patients with CSD are typically young or children who develop a febrile illness several weeks after exposure to a cat.
- The disease is transmitted by a scratch from an infected cat, or may be transmitted by fleas from the cat to the human.
- Only a small percentage of patients with CSD develop neuroretinitis and visual loss.
- Visual symptoms usually begin 2 to 3 weeks after the systemic symptoms have subsided. Many patients do not recall an antecedent systemic illness.

## Cat-Scratch Neuritis (Neuroretinitis) (CSD)

- The examiner should ask specifically about **fever, malaise, cough, adenopathy, exposure to cats.**
- The course of visual loss is **similar to MS optic neuritis**, as it may progress over several days and tends to improve over several months.
- **Pain with eye movement** can occur but not nearly as frequently as with optic neuritis.
- The optic disc shows mild to moderate diffuse edema, frequently with a **focal elevation of the optic disc** that has the appearance of a granuloma.

## Cat-Scratch Neuritis (Neuroretinitis) (CSD)

- The disc edema is accompanied by white edema in the inner macula that line up radially in Henle's layer, forming a star.
- The **macular edema may be subtle and the patient may be thought to have optic neuritis.**
- The radial star pattern may completely encircle the fovea or may be limited to only one sector.
- A **few vitreous cells** may be present.
- Deep, white, **choroidal patches** are occasionally seen in the retinal periphery, **even in the fellow asymptomatic eye.**

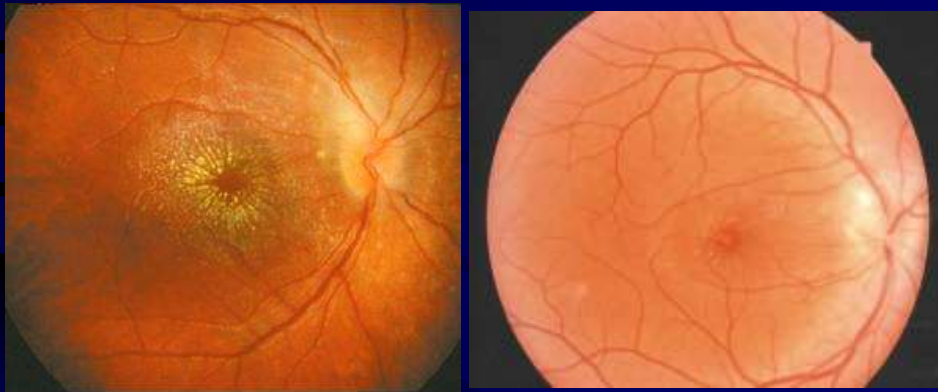## Cat-Scratch Neuritis (Neuroretinitis) (CSD)

- Patients with a classic history and examination may not require an extensive evaluation.
- Laboratory studies that may be helpful include a differential complete blood count, toxoplasmosis titer, and syphilis and Lyme disease serologies.
- A positive **serologic titer (IFA) for Bartonella henselae is specific** and thus may be helpful in confirming the suspected cause.
- However, a **negative titer does not exclude CSD.**

## Cat-Scratch Neuritis (Neuroretinitis) (CSD)

- The visual prognosis for CSD neuroretinitis is good, with most patients experiencing a significant recovery regardless of treatment.
- This natural history of recovery makes it difficult to assess the efficacy of treatment.
- Many clinicians treat CSD neuroretinitis with a course of **ciprofloxacin, doxycycline, or other antibiotics.**

## Cat-Scratch Neuritis (Neuroretinitis) (CSD)



## Optic Neuritis Associated with Lyme Borreliosis

- It is a spirochetal infection transmitted via a tick bite.
- From a neurologic standpoint, it may mimic MS.
- It is an uncommon cause of optic neuropathies.
- Follicular conjunctivitis occurs in about 10% of patients, along with the typical erythema migrans rash, in 60% to 80% of cases.
- Uveitis is rare, as is neuroretinitis.
- In the early disseminated phase, aseptic meningitis, cranial neuropathies (facial palsy being the most common).

## Optic Neuritis Associated with Lyme Borreliosis

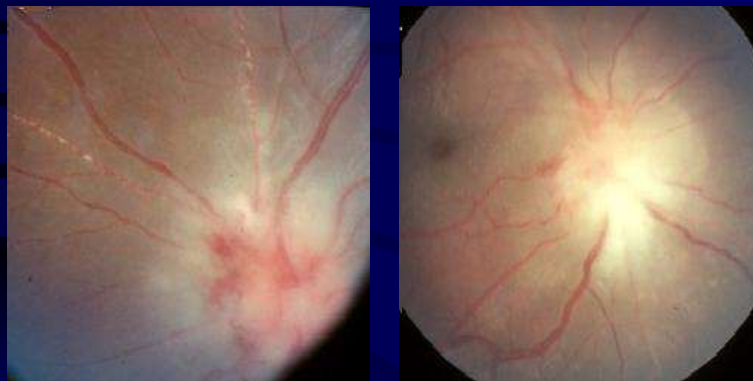
- Indirect immunofluorescence antibody (IFA) and enzyme-linked immunosorbent assays (ELISA) are used to detect antibodies
- At present, serpositivity alone does not distinguish between past exposure and active infection, and false-positive results are common.
- Polymerase chain reaction techniques are currently being evaluated.
- In the early stages, **doxycycline or penicillins are used, and ceftriaxone** is used for neurologic or ophthalmic disease.<sup>235</sup>



## Optic Neuritis Associated with Protozoal Infections

- **Toxacara canis** is documented to cause inflammatory papillitis with vitreous cellular reaction.
- **Toxoplasma gondii** (the agent of toxoplasmosis), a relatively frequent cause of posterior uveitis in USA, is an uncommon but eradicable agent that can produce **neuroretinitis** characterized by retinal edema with macular star exudates.
- Serologic tests include IFA titers and ELISA, and sulfamethoxazole, sulfadiazine, or clindamycin therapy is indicated, usually coupled with corticosteroids.

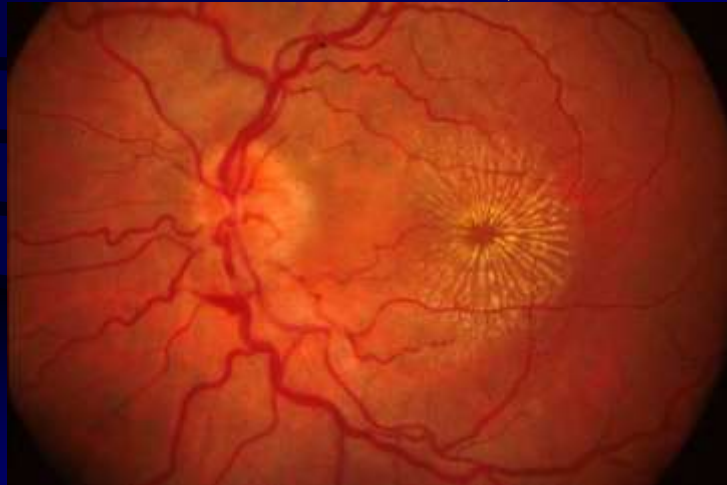
## Optic Neuritis Associated with Protozoal Infections



## OPTIC DISC EDEMA WITH A MACULAR STAR (ODEMS)

- It includes several different disease processes, characterized by the presence of optic disc edema and macular edema.
- Neuroretinitis is often used interchangeably with ODEMS, but neuroretinitis has come to specifically imply an infectious cause.
- Noninfectious entities that often produce coexistent disc and macular edema include papilledema, hypertensive retinopathy, postoperative cystoid macular edema (Irvine-Gass syndrome), DR with papillopathy, Coats' disease, capillary hemangiomas, retinal macroaneurysms.

## OPTIC DISC EDEMA WITH A MACULAR STAR (ODEMS)



## OPTIC DISC EDEMA WITH A MACULAR STAR (ODEMS)

- Hypertensive retinopathy is invariably bilateral with other retinal signs.
- CME does not usually develop a "star."
- Coats' disease and capillary hemangiomas show usually an unaffected disc.
- Diabetic papillopathy or disc neovascularization, tends to have a characteristic picture that is not likely to be confused with this entity.
- Optic disc edema from any cause, when extreme, may be associated with macular edema and a "star."

## OPTIC DISC EDEMA WITH A MACULAR STAR (ODEMS)

- This observation suggests that all causes of disc edema may need to be considered in the differential diagnosis of ODEMS when the degree of optic disc swelling is extreme.
- The precise pathophysiology of infectious neuroretinitis is not known, but it likely involves an exudative process in the vessels of the disc and macula triggered by the infectious agent or the subsequent immune response to the agent.

## OPTIC DISC EDEMA WITH A MACULAR STAR (ODEMS)

- The availability of sensitive serologic tests for the etiologic agent in cat-scratch disease (*Bartonella henselae*) demonstrates that this organism is a common cause of neuroretinitis.
- Other organisms that can cause neuroretinitis include *Toxoplasma gondii*, syphilis, Lyme disease, and viral entities.
- A bilateral, recurrent, idiopathic neuroretinitis with a poor visual outcome has been described (Purvin, 1994).

## CONTIGUOUS INFLAMMATORY NEUROPATHIES

- The optic nerve may be secondarily involved by various inflammatory lesions of adjacent tissues, including the orbit, paranasal sinuses, and intracranial meninges.
- With orbital cellulitis or nonspecific inflammatory pseudotumor, it is not clear whether true optic neuritis is present or visual deficits are caused by pressure effect.
- In orbital inflammatory pseudotumor, visual loss may be accompanied by variable degrees of disc swelling, a finding suggesting actual optic neuritis or perineuritis, as noted above. Systemic steroids are frequently beneficial.

## CONTIGUOUS INFLAMMATORY NEUROPATHIES

- Optic neuritis may accompany acute or chronic meningitis in children or adults.
- Purulent meningitis spreads to involve the optic nerve sheaths, primarily in the optic canal, or the substance of the nerve itself.
- Disc swelling may be present. Optic atrophy can follow severe neuritis, but as a rule, vision returns to functional levels, even after several months.
- In cases complicated by hydrocephalus or opticochiasmatic arachnoiditis, field loss may be progressive.