

Posterior vitreous detachment after laser in situ keratomileusis among the Egyptian population

By

Dalia Mohamed Aly Tohamy

Assistant lecturer at Ophthalmology Department, Assiut University Hospital

Prof. Kamel Abdelnaser, Prof. Hany Omar, Dr. Walid Saad

Financial disclosure

**There is no proprietary or commercial interest
in any of the materials discussed in this
presentation.**

Introduction

- Lasik nowadays is the most popular and safe method that used for treatment of refractive errors ^{1,2}.
- Eyes with myopia are considered at risk for development of PVD ^{3,4} .

1 Ahmadiéh, H. et al., 2005

2 Kohen, T. et al., 2003

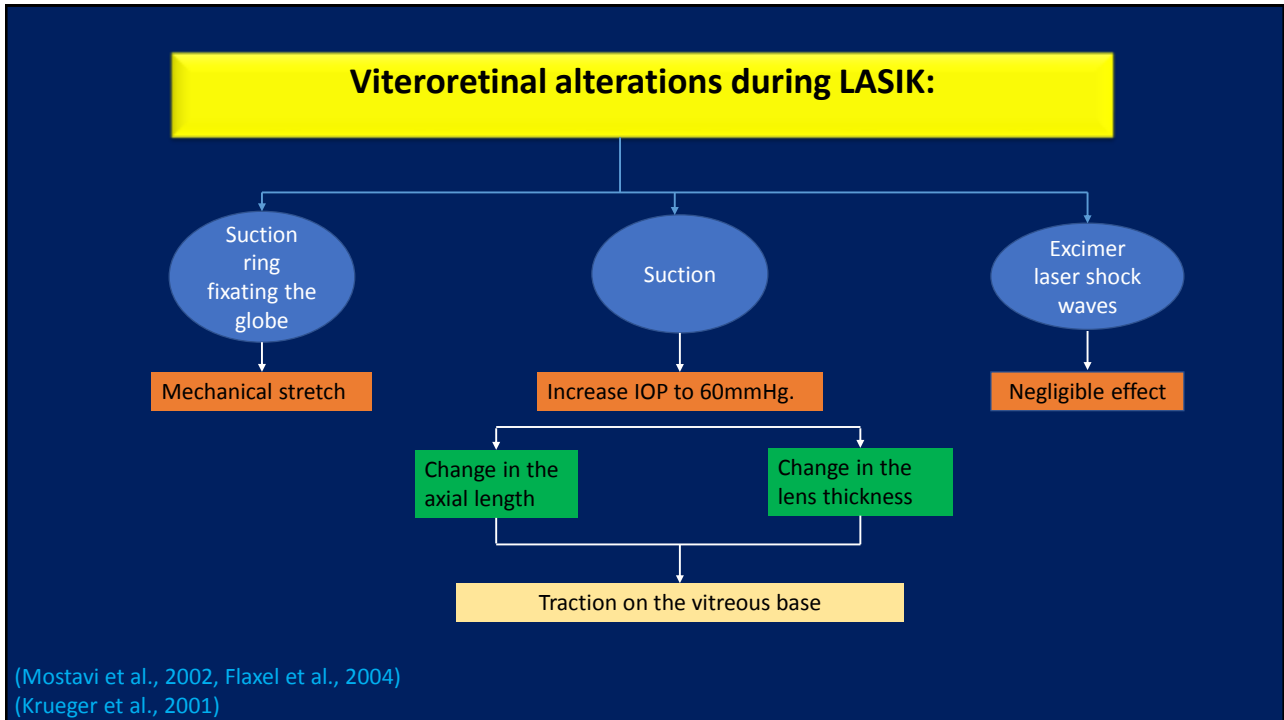
3 Kang, H.M. et al; 2014

4. Bamashmus. M.A. et al., 2013

Introduction

- Few articles of literatures discuss posterior segment complications of LASIK. As vitreoretinal disorders are usually managed by retinal specialists, refractive surgeons may not be aware of posterior segment complications and their outcome, so posterior segment examination before LASIK is mandatory.

Mirshahi, A. et al., 2009



Purpose of the study

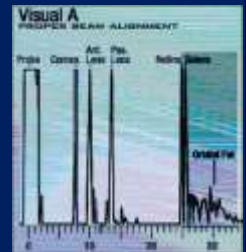
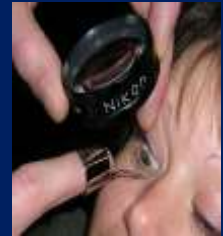To identify the possible risk factors for the development of posterior vitreous detachment post LASIK among the Egyptian population.

Patients and methods

- **Settings:**
 - Interventional case series study
 - Performed in ElNoor ophthalmic centre
 - From October 2015 to October 2016
- **Inclusion criteria:**
 - Absence of ophthalmic disease other than myopia or myopic astigmatism.
 - No family history of glaucoma or ocular hypertension.
 - Age >18 years
 - Normal kinetic ultrasound evaluation of the posterior segment.
 - No history of systemic disease(diabetes or hypertention).

Patients and methods

- **Ophthalmic assessment:**
 - Medical and ocular history.
 - Uncorrected visual acuity (UCVA), best corrected visual acuity (BCVA)
 - Slitlamp examination
 - Applanation tonometry
 - Fundus biomicroscopy
 - Manifest and cycloplegic refraction
 - Pentacam
 - A scan
- **Informed consent was obtained from each patient approved by the Faculty of Medicine Research Ethics committee.**



Patients and methods

Immediately before LASIK and 1 week post LASIK, ocular sonography was done

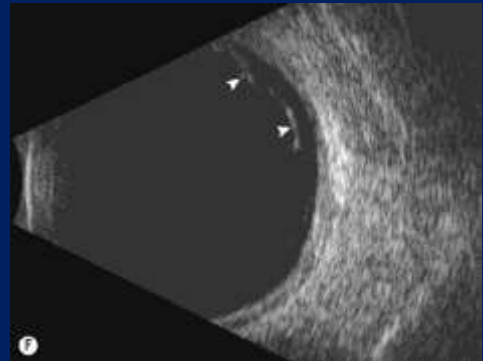
B scan

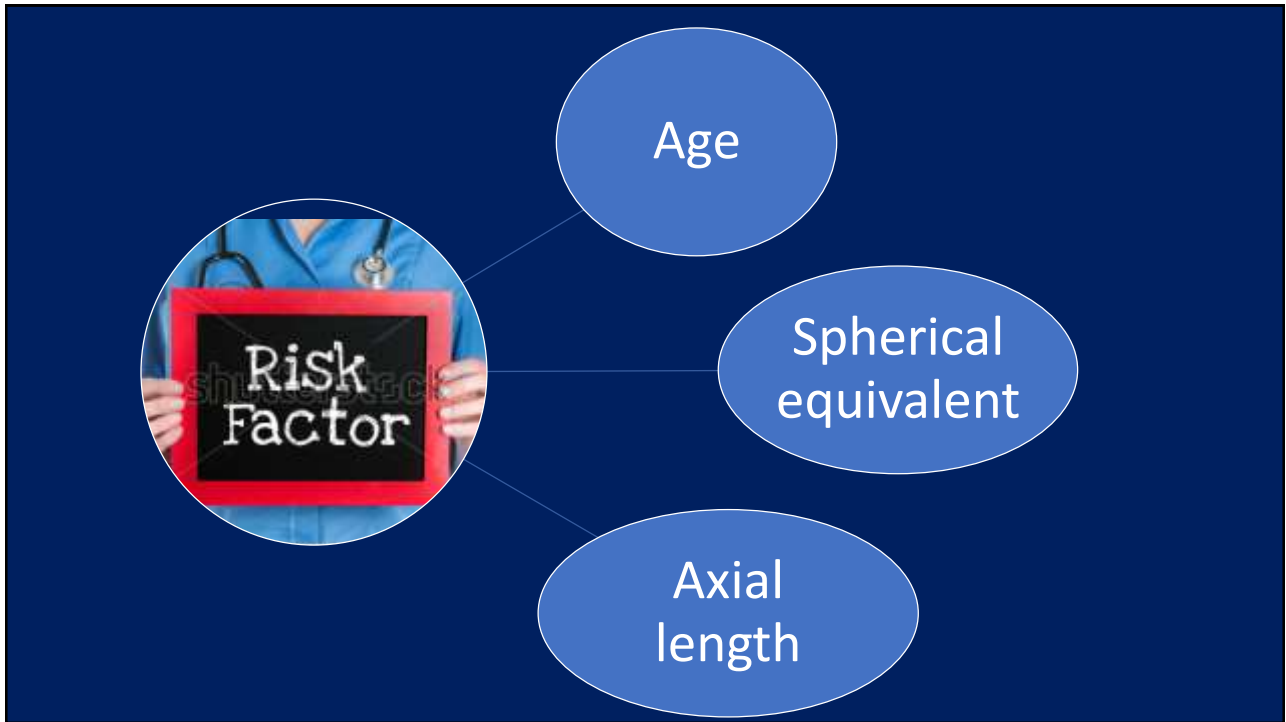
The globe scanned in both sagittal and transverse plans through closed eyelids and high maximal gain to detect PVD signs

Then all patients underwent microkeratome assisted LASIK (ALLRGREETTO device, wave light EX500, Alcon, Fortworth, TX, USA).

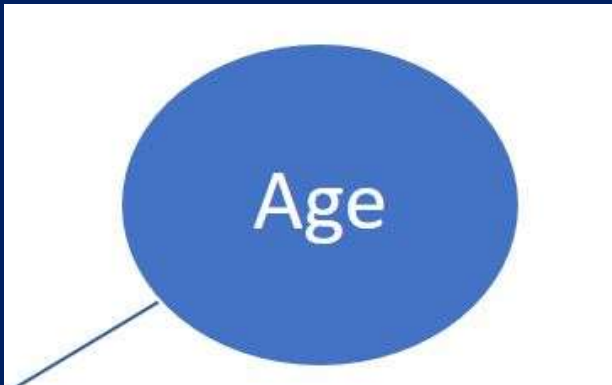
Results

- Our study included 61 eyes of 31 patients
- 21 females and 10 males
- Age range (20-41) with mean (28.1+/-5.6)
- Axial length range(21-26.3) and mean (23.5+/-1.5) mm
- Spherical equivalent range (-1.4)-(-15.1) with mean (-6.1+/-3.2) diopters
- PVD developed in 18 eyes (29.5%)





Results



- PVD developed more in eyes of patients ≥ 30 years old (odds ratio (OR) = 4.1, 95% confidence interval, CI = 1.2-14.1)

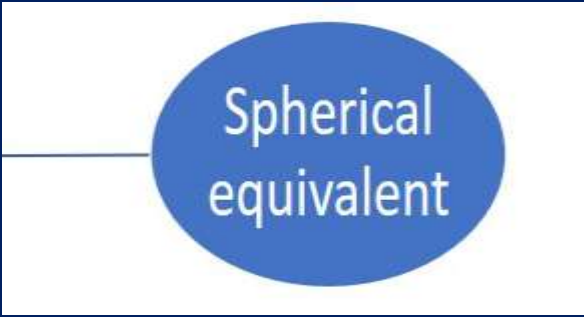
Results



Axial
length

- PVD also occurred more in those with axial length ≥ 25 mm (OR = 3.5, 95% CI= 1.1-11.7).

Results



Spherical
equivalent

- PVD developed more in S.E ≥ -6 (55.6%), however this did not reach statistical significance ($p=0.7$).

Conclusion

- Older age, longer eyes and higher spherical equivalent were associated with increased incidence of PVD among the Egyptian population.
- Patients with S.E > -6 should have Meticulous fundus examination and their axial length should be checked prior to LASIK.
- Possibility as well as symptoms of PVD should be discussed with patients undergoing LASIK especially those with high myopia.
- Researchers should pay more attention to posterior segment complications post LASIK.

