



Endophthalmitis in Children

Hala Elhilali, M.D.
Children's Hospital, Cairo University

Etiology- Developing Countries

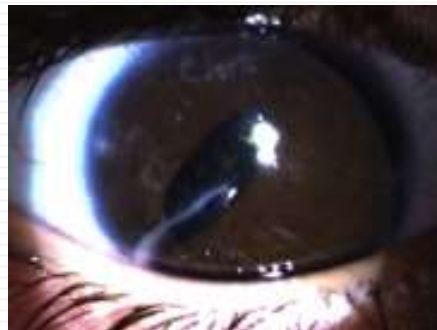1. Penetrating Ocular Trauma
2. Previous ocular surgery
3. Endogenous
4. Infected corneal ulcer

Etiology- Developed Countries

1. Penetrating Ocular Trauma
2. Previous ocular surgery
3. Endogenous
4. Infected corneal ulcer

Penetrating Ocular Trauma

- Sharp objects
- IOFB
- Incidence:
4.4%-13.0%



Essex et al., 2004

Postoperative Endophthalmitis – Cataract Surgery (Early)

Causes

- Inadequate disinfection
- Leakage of incisions
- Surgical complications
- Poor compliance to post-operative medications

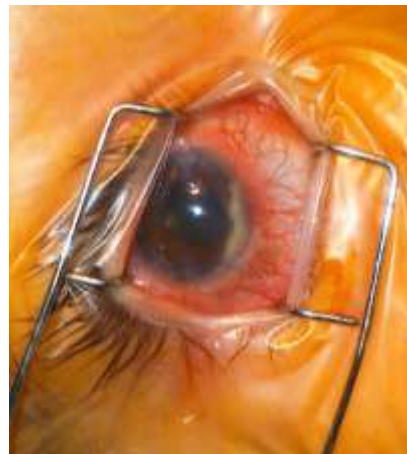Prophylaxis

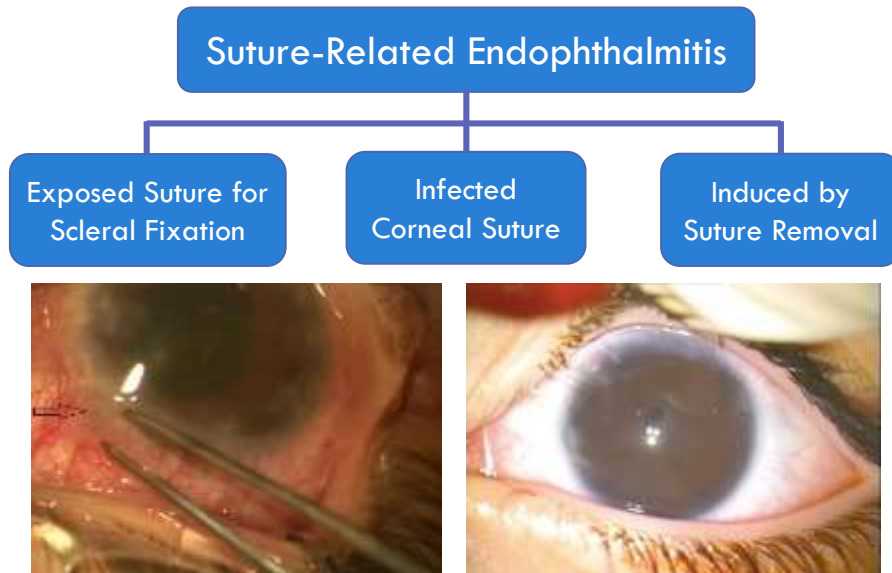
- Povidone-iodine disinfection
- Intracameral antibiotics
- Perioperative topical anti-bacterials

Postoperative Endophthalmitis – Cataract Surgery (Late)

Causes

- Indolent Organisms:
 - Propionibacterium acnes
 - Coagulase-negative staphylococcus
 - Fungal
- Suture-related:
 - Exposed suture for scleral fixation
 - Infected corneal suture
 - Induced by suture removal





Post-Cataract Endophthalmitis - Late


Causes

- ❑ Indolent Organisms:
 - Propionibacterium acnes
 - Coagulase-negative stroplylococcus
 - fungal
- ❑ Suture-related:
 - Exposed suture for scleral fixation
 - Infected corneal suture
 - Induced by suture removal


Prophylaxis

- ❑ Mandatory suture removal 4-6 weeks
- ❑ Topical antibiotics initiated before removal
- ❑ Povidone-iodine 5%
- ❑ Technique of surgical removal

Technique for Suture Removal

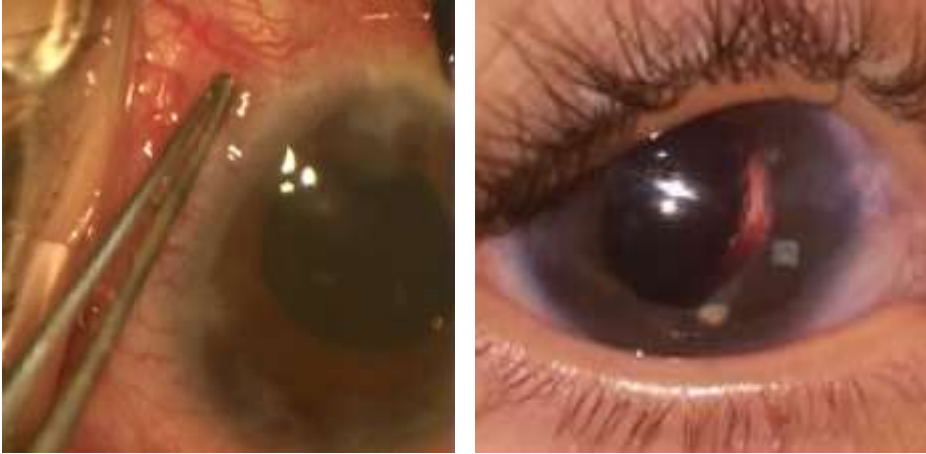

Case



Courtesy of Dr Abdel Salam Mohsen

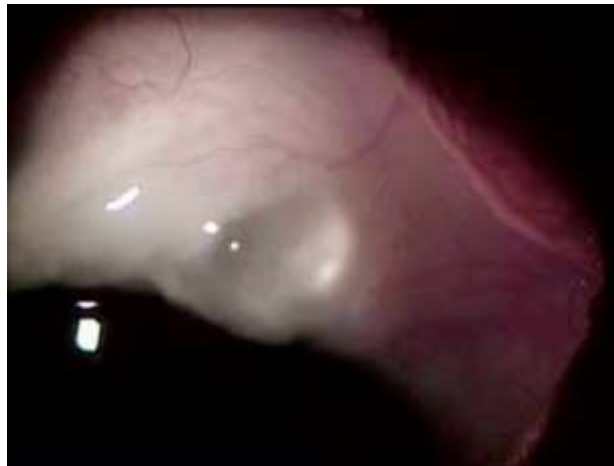Case



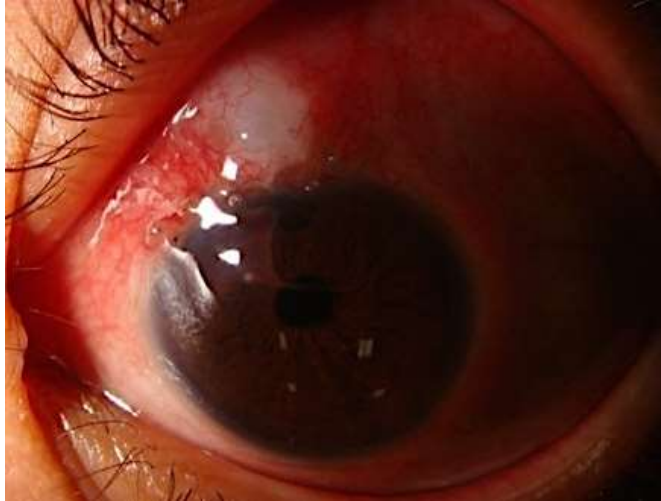
Postoperative Endophthalmitis- Glaucoma Surgery

Causes

- Thin-walled filtering blebs
- Glaucoma implants



Bleb-Related Infection



Courtesy of Dr Yasmine El Sayed

Post-Glaucoma Endophthalmitis

Causes

- Thin-walled filtering blebs
- Glaucoma implants

Prophylaxis

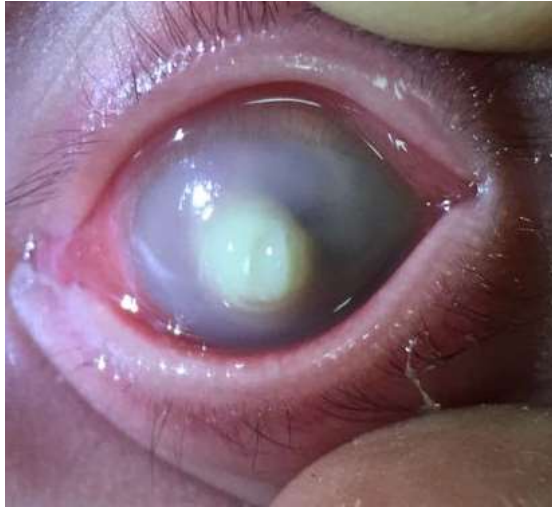- Cone sterilization
- Topical antibiotics
- Parent Education



H₂O₂: 3%
10 min

Endogenous Neonatal Endophthalmitis

- 20 days old
- 36 weeks gestational age
- 2200 g
- NICU admission: respiratory distress
- IV antibiotics for 6 days

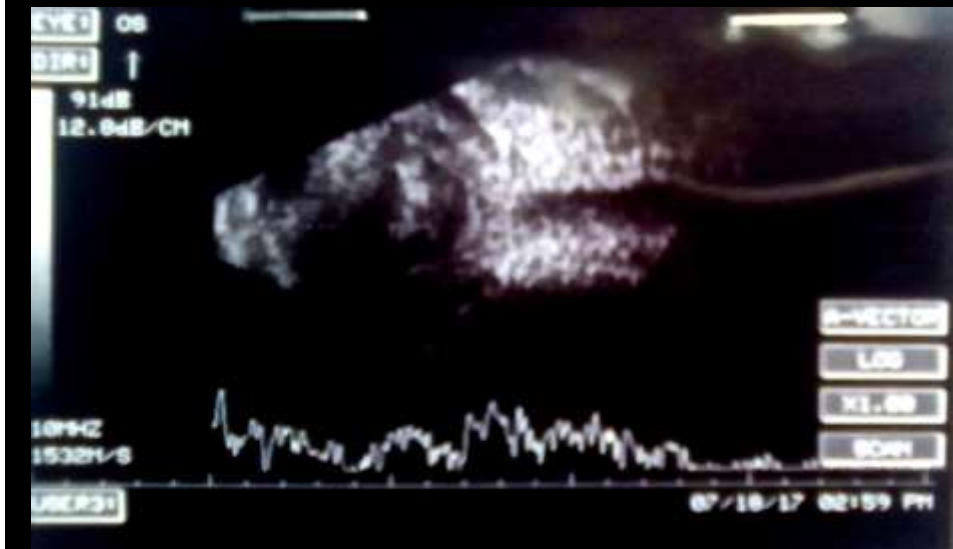


Differential Diagnosis

**Bilateral
Endogenous
Endophthalmitis**

**Masquerade
Syndrome**

Work-up: Ultrasonography



Work-up

Blood Culture

Urine Culture

**Abdominal
Ultrasonography**

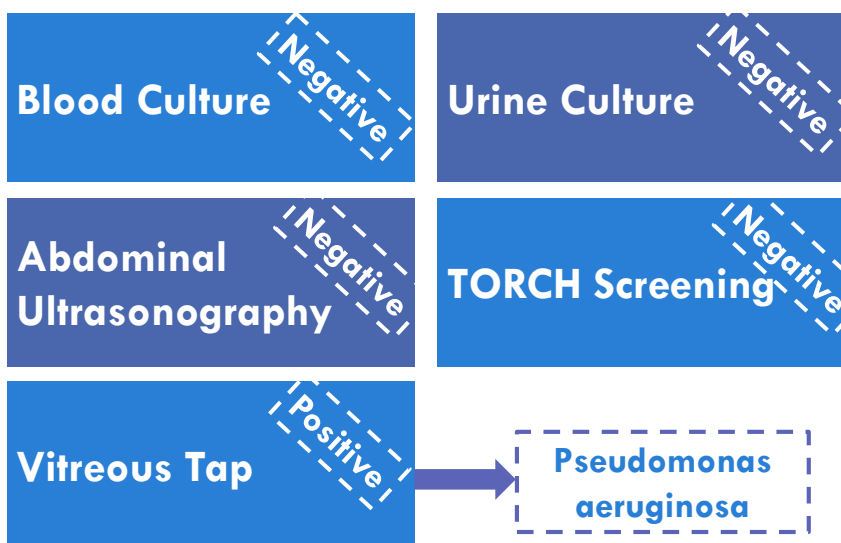
TORCH Screening

Vitreous Tap

Treatment

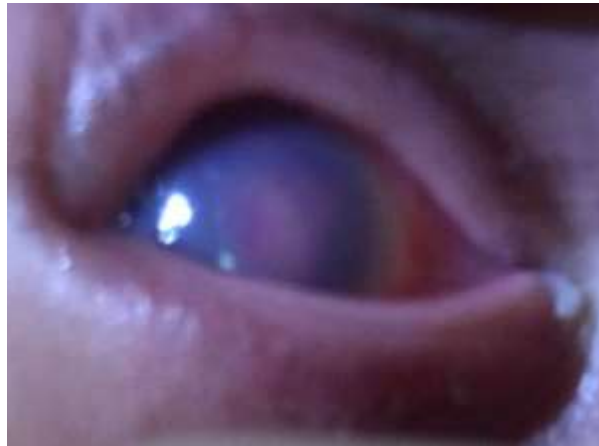- Fortified eye drops: vancomycine + ceftazidime
- Intra-vitreous antibiotics
- Intra-vitreous voriconazole

Results



Treatment

- Repeated IV antibiotics
- Intravenous Levofloxacin



Endogenous Endophthalmitis- Risk Factors

Prematurity and low birth weight

Indwelling catheters, ventilators

Compromised immune status

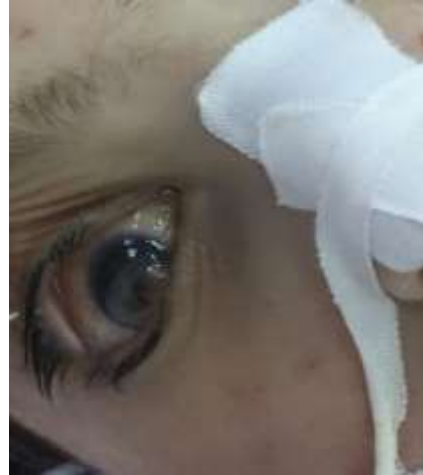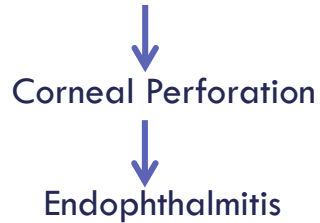
Blood Transfusion

Hospital admission

**Bacteremia/
Candidemia**

Corneal Complications in Ventilated ICU Children

- Exposure keratitis 20%-42%
- Dryness, ulceration



Rosenberg et al, 2008

Protocol for Eye Care in Pediatric ICU

- Cleaning eye with normal saline-soaked cotton balls
- Lubricant application every 4 hours
- Closure of eyelids (manually/taping)
- Tracheal suction from the side
- Redness/Exudates → Immediate ophthalmic consultation

ACKNOWLEDGMENTS