

Colored IOL

EOS 2018

Dr. Alaa Ghaith MD

Professor of Ophthalmology
Alexandria University

Financial Disclosure

I have no financial interest in any product •
mentioned in this presentation.

Acknowledgement

Ahmed Amr, MD
Ahmed Samir El Sheikh, MD

Case Presentation

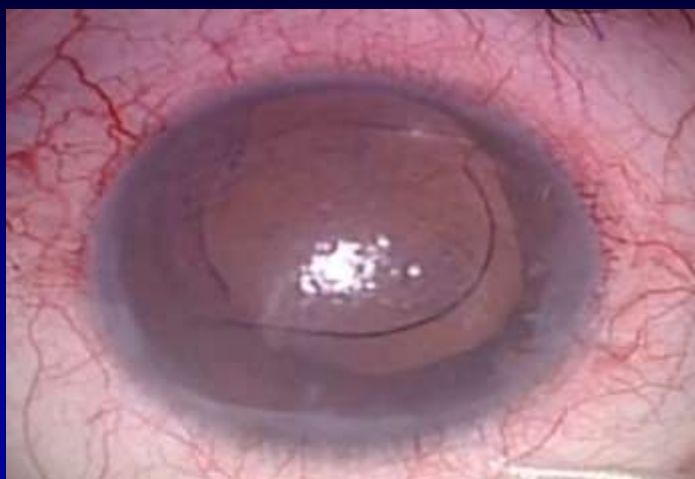
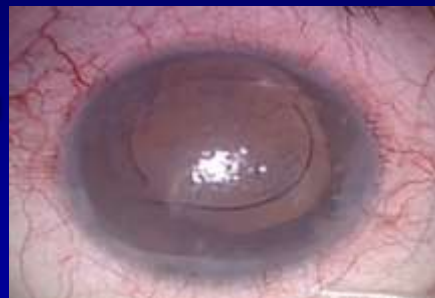
History

- 34 yrs old male
- Blunt trauma to the left eye in 2001
 - Traumatic mydriasis and lens dislocation
- Secondary AC IOL implantation in 2014
 - corneal decompensation and glaucoma

Case Presentation

Examination at presentation

- Moderate diffuse corneal edema (PBK)
- AC IOL
- Widely dilated irregular fixed pupil
- IOP: +++ digitally
- VA: CF 50 cm
- Other eye: free with VA: 1.2



Case Presentation

Initial Treatment

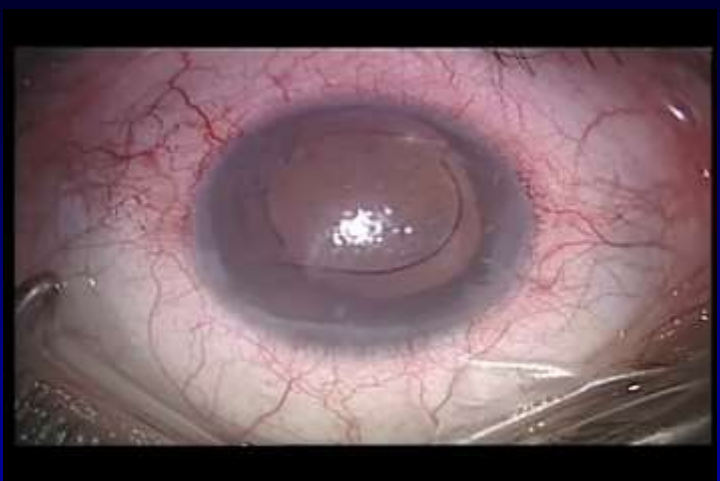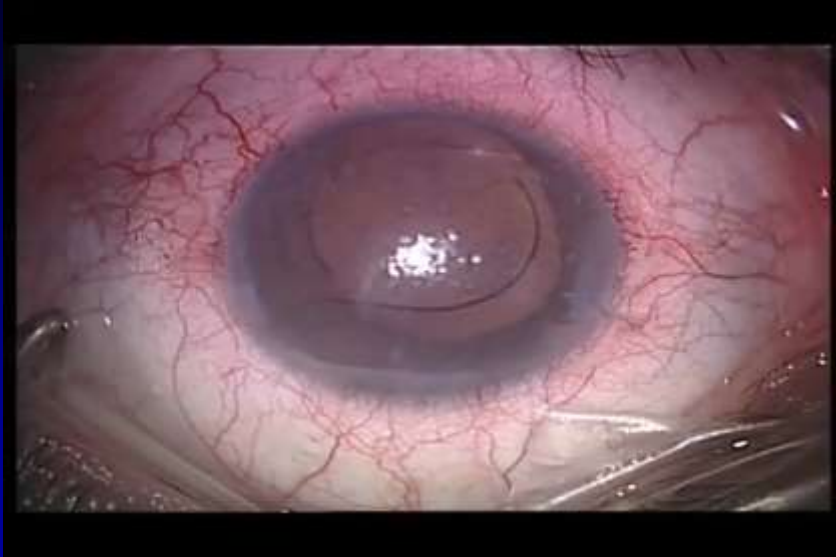
- BCL
- Topical antibiotics, IOP-lowering drops, lubricants, and NaCl 5% eye drops
- Patient felt better and VA improved to CF at 2 m
- Next visit, pt complained of recurrence of pain & discomfort after losing the BCL → asks for a permanent solution

Case Presentation

Surgical Plan

- Reduction of IOP medically
- Ordering VEP and ERG
- PKP + AC IOL explantation + Scleral fixation of Coloured IOL after

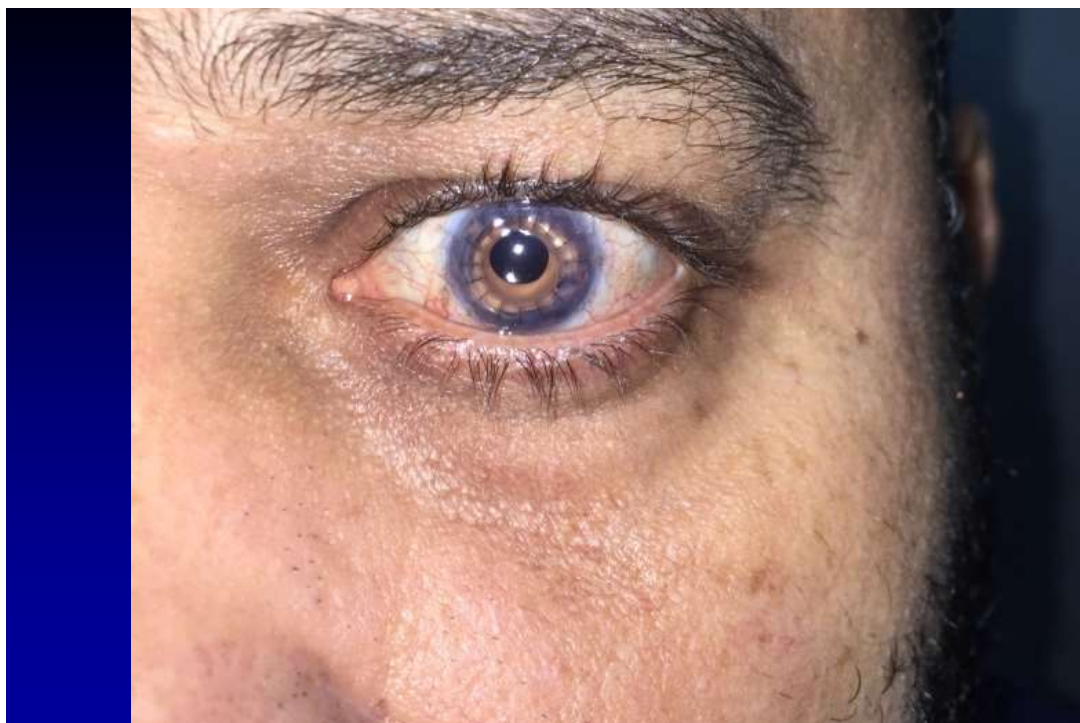Case Presentation

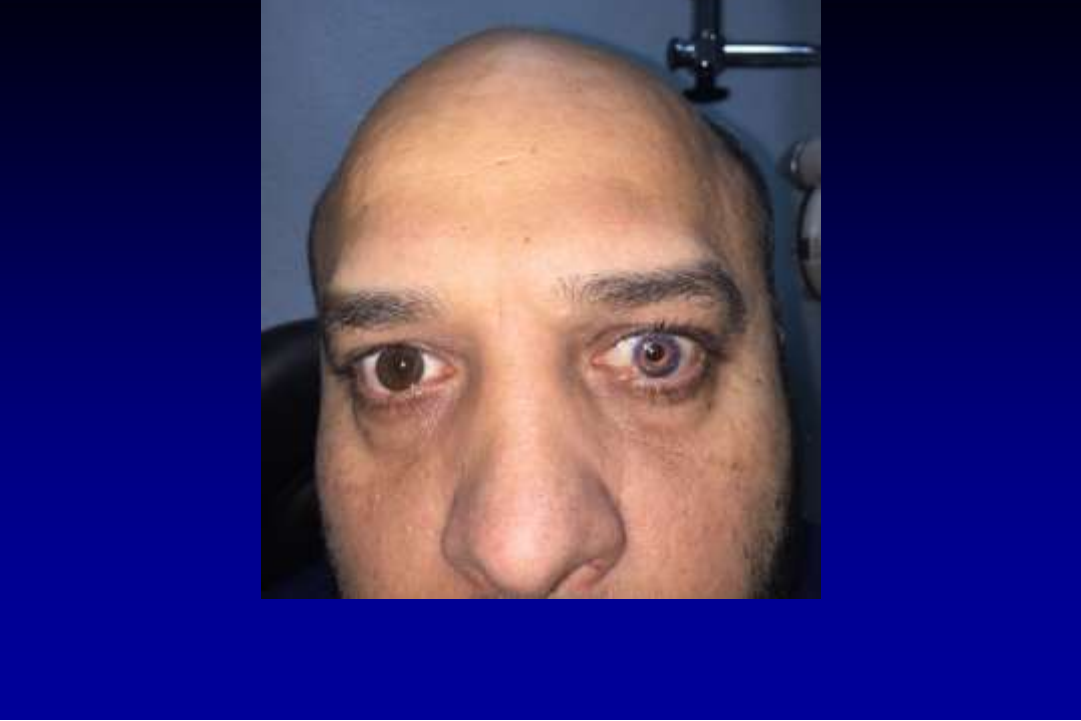

Case Presentation

Postoperative Result (2 weeks)

- Clear graft, IOL in place, VAsc 0.05, eye is quite and IOP is 60 mmHg
- IOP lowering drugs → 15 mmHg
- Patient is content





Thank You

FOR KENNETH