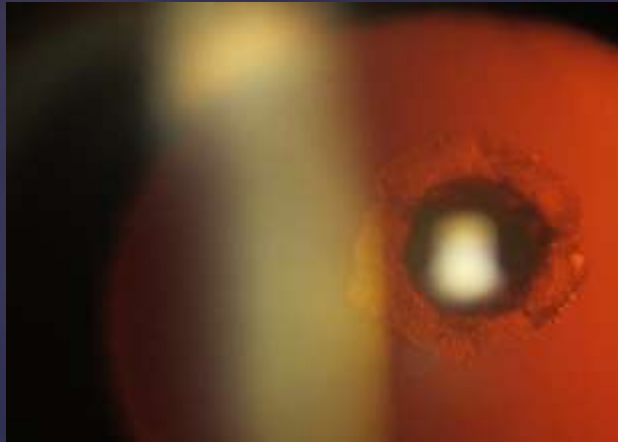


POSTERIOR POLAR CATARACT

AMR HASSAN EL SAMRA
PROF. OF OPHTHALMOLOGY
RESEARCH INSTITUTE OF
OPHTHALMOLOGY

**POSTERIOR POLAR CATARACT
IS RARE FORM OF
CONGENITAL CATARACT**

**IT IS USUALLY INHERITED AS
AN AUTOSOMAL DOMINANT
DISEASE, YET IT CAN BE
SPORADIC**



Posterior polar cataract presents as a distinctive discoid lens opacity situated posteriorly, adjacent to the posterior capsule



It is usually associated with remnant of the hyaloid system. Duke-Elder mentioned that it can be stationary as well as progressive cataracts

**WHAT IS THE PROBLEM WITH
THIS TYPE OF CATARACT
DURING SURGERY ?**

THE ANSWER

**IT IS HIGHLY ASSOCIATED WITH
COMPLICATIONS DURING
SURGERY**

**1- POSTERIOR CAPSULE
RUPTURE**

2- NUCLUES DROP

**THE REASON FOR THIS HIGH
COMPLICATION RATE IS:**

**THE STRONG ADHERENCE OF
THE OPACITY TO THE WEAK
POSTERIOR CAPSULE**

**IMPORTANT SURGICAL
STEPS WE SHOULD TAKE
CARE OF**

1. Capsulorhexis

2 . Hydrodissection

SURGERY

