


# Echographic Evaluation of Posterior Segment

Presented By: Professor Dr. Hala El Chewekh

*May 2023*

1



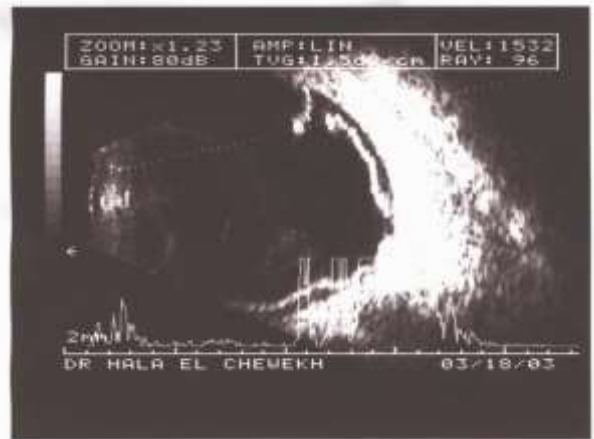## Echographic Evaluation of the Retina

- Retinal tear
- Retinal detachment (rhegmatogenous, tractional or exudative )
- Retinoschisis

2

## Retinal Tear

- It may be the cause of spontaneous V.hge
- Examiner should look for a PVD
- Tear appears as echo dense membrane extending from the surface of the retina to posterior hyaloid

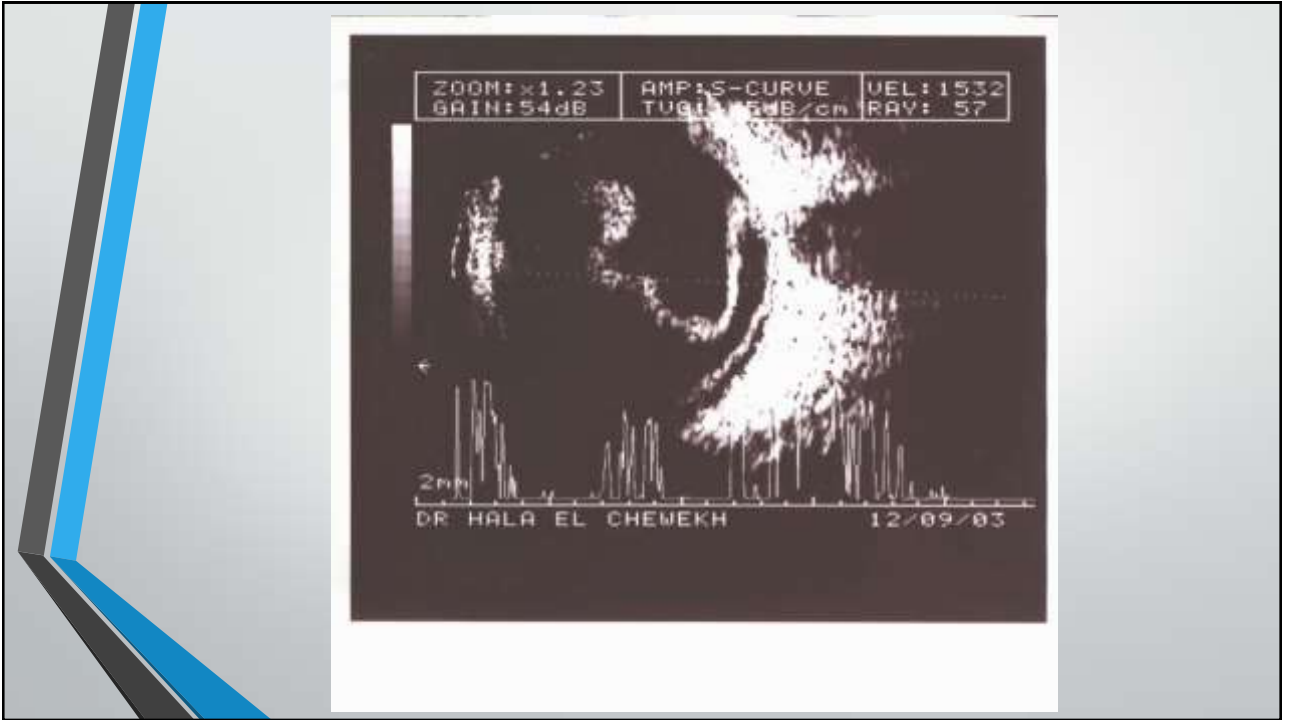


3

## Retinal Detachment

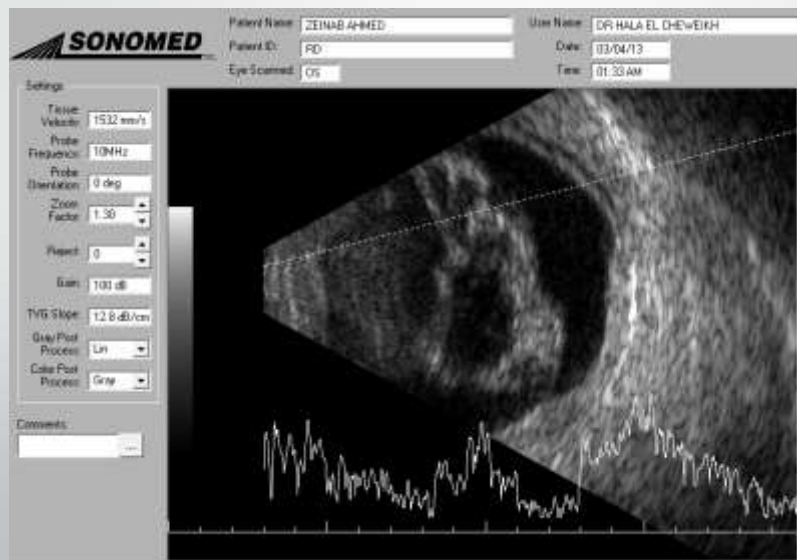
- Continuous membrane from the optic disc to ora serrata with v-shaped appearance and undulating movements on kinetic scan
- High spike on A-scan (aiming beam should be perpendicular to the surface).

4



5

## Retinal Detachment & Choroidal Detachment



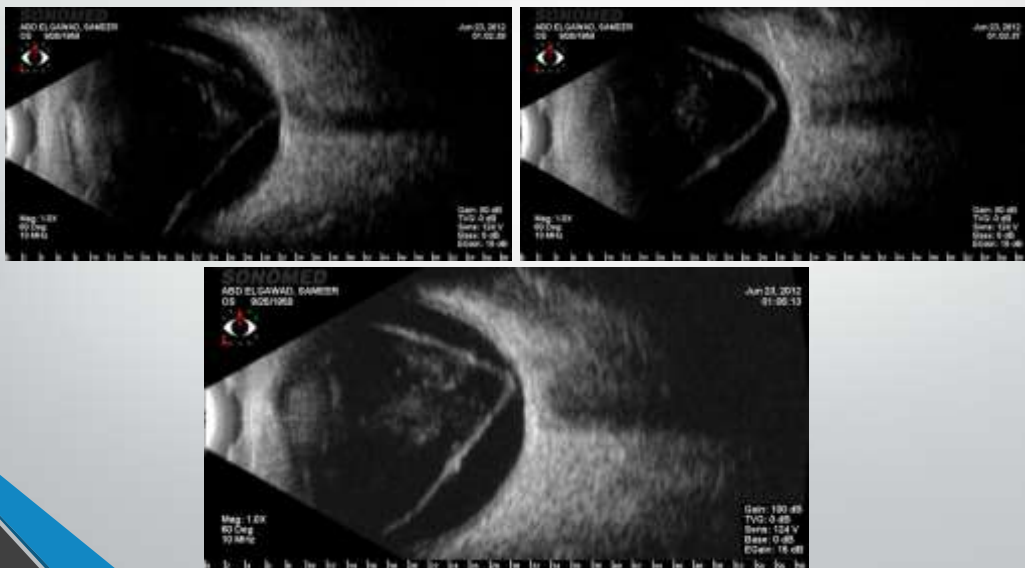
6

## Long Standing Retinal Detachment

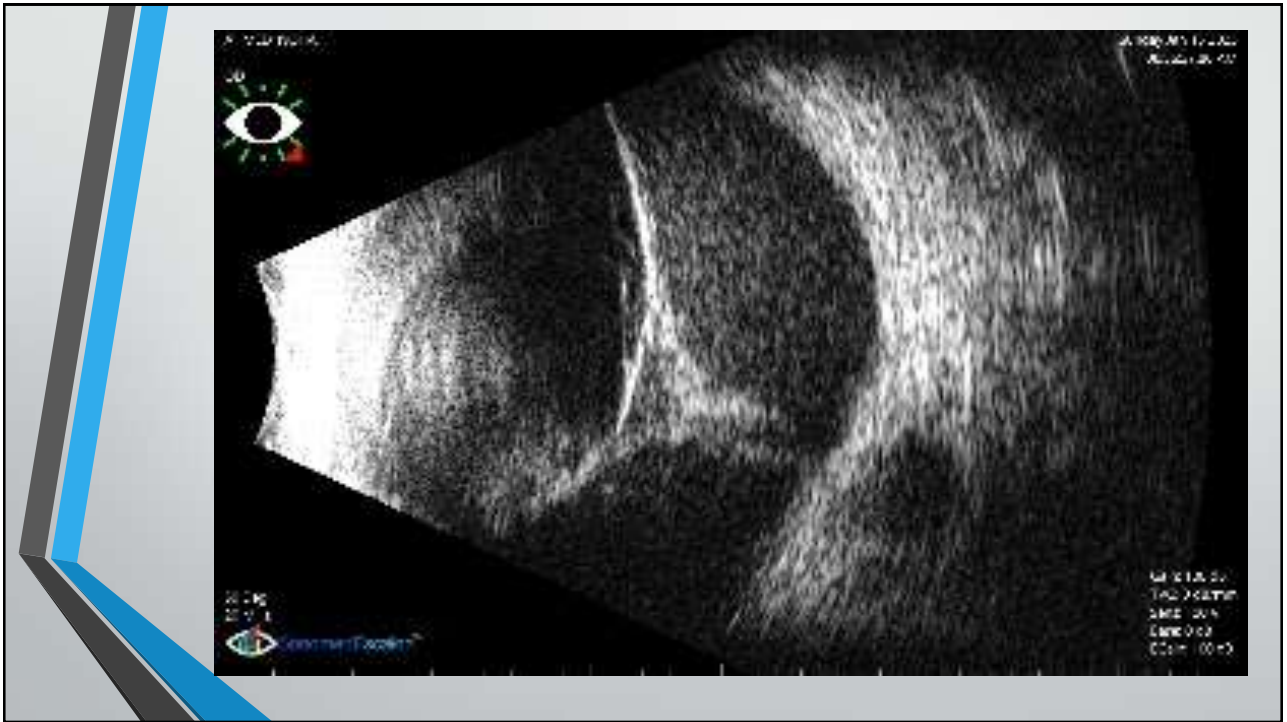
- Mobility is highly restricted
- Retinal cysts
- Calcification
- Echolucent space when surrounded on both sides by dense opacities

7

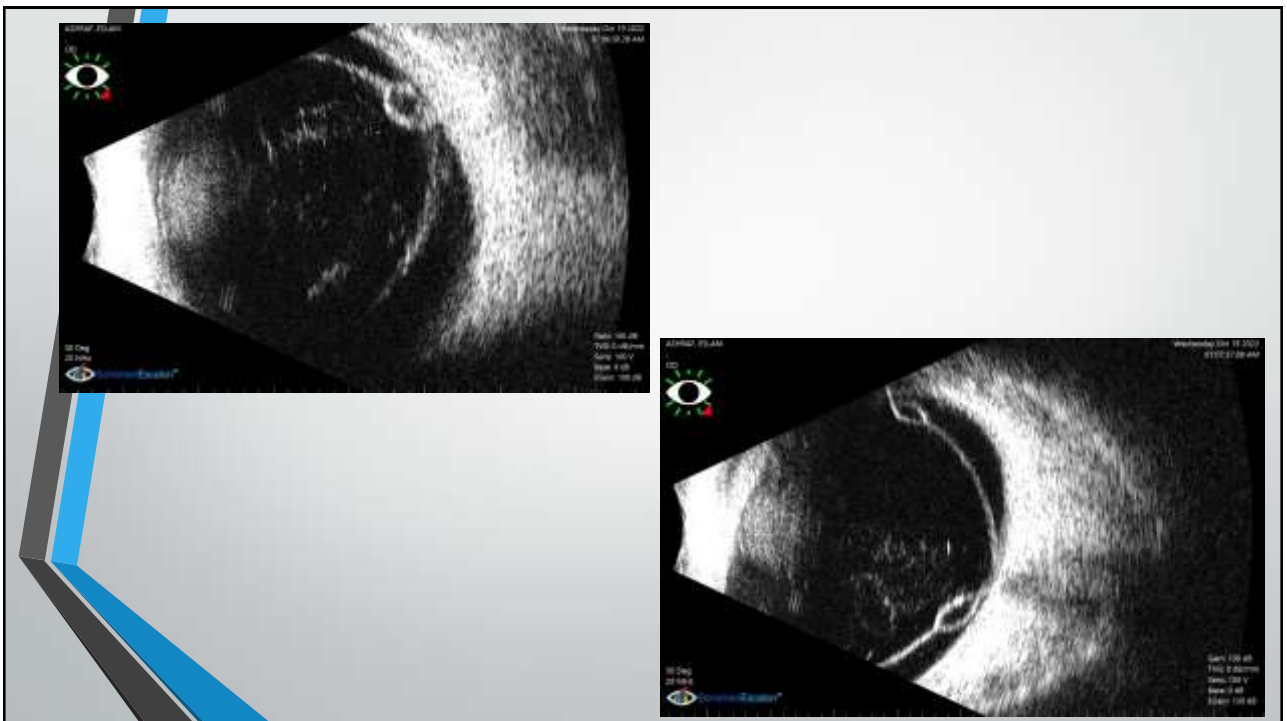
## Long Standing Retinal Detachment with PVR



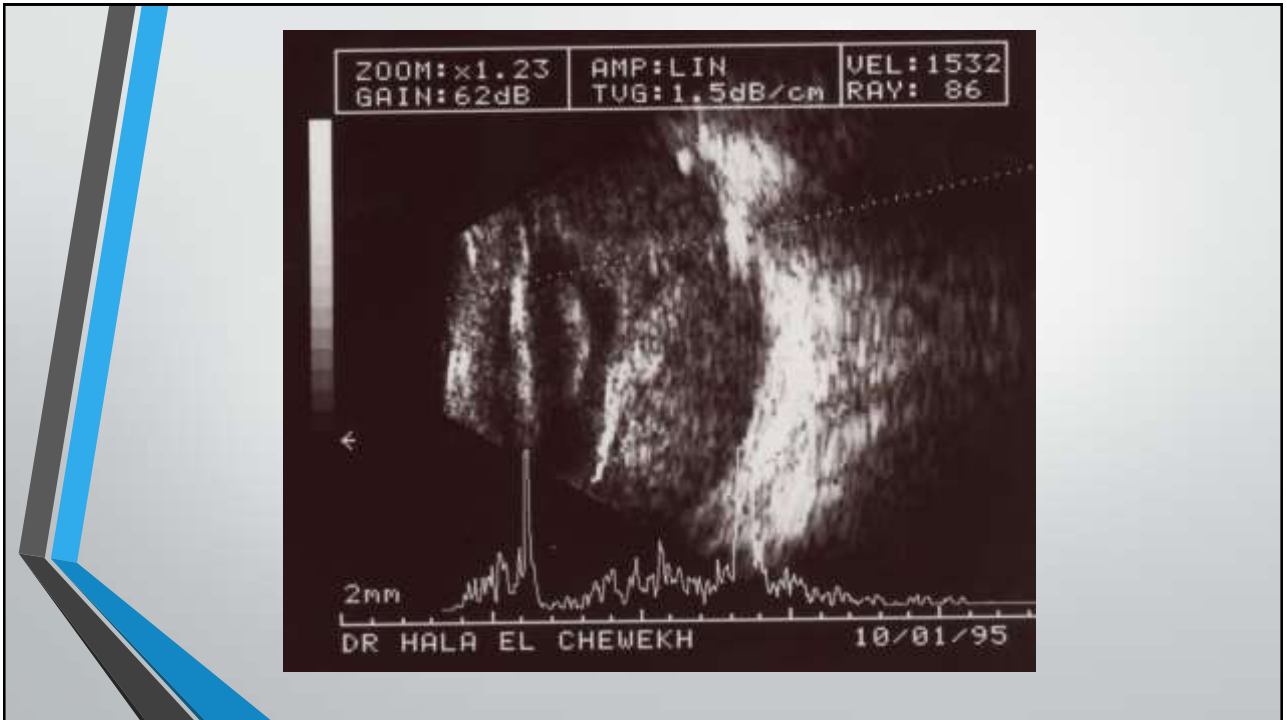
8



9

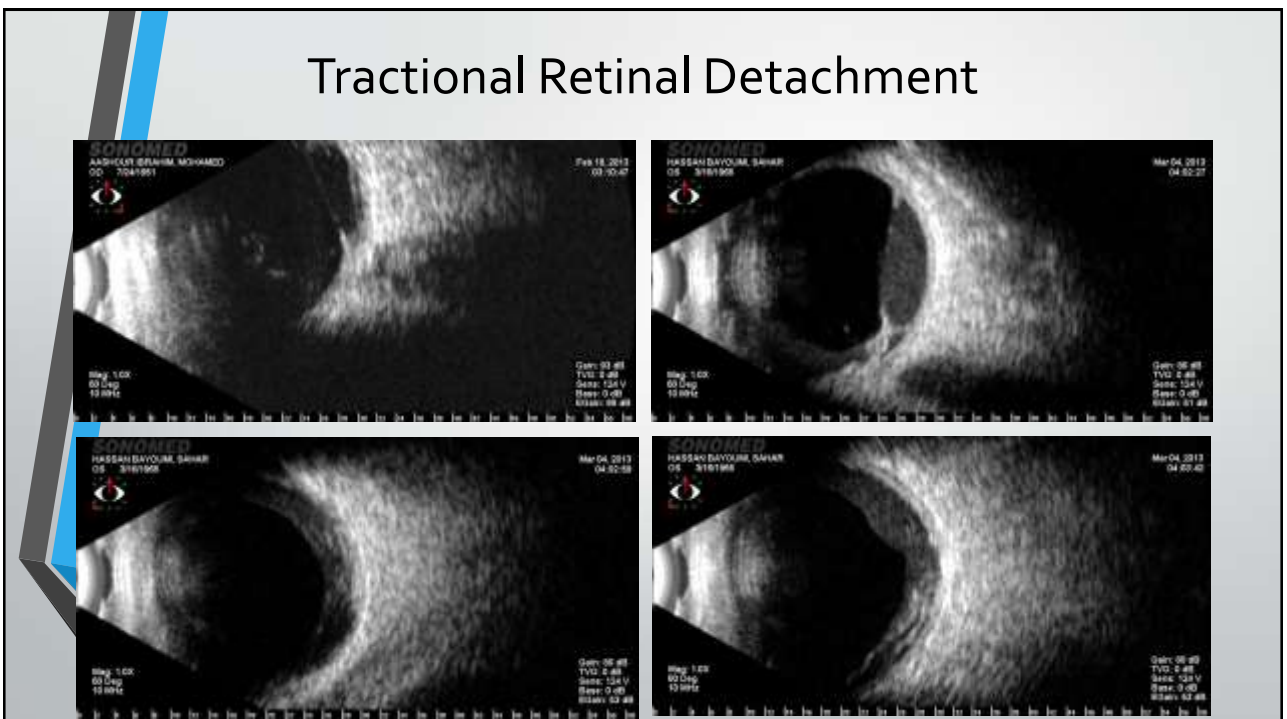


10



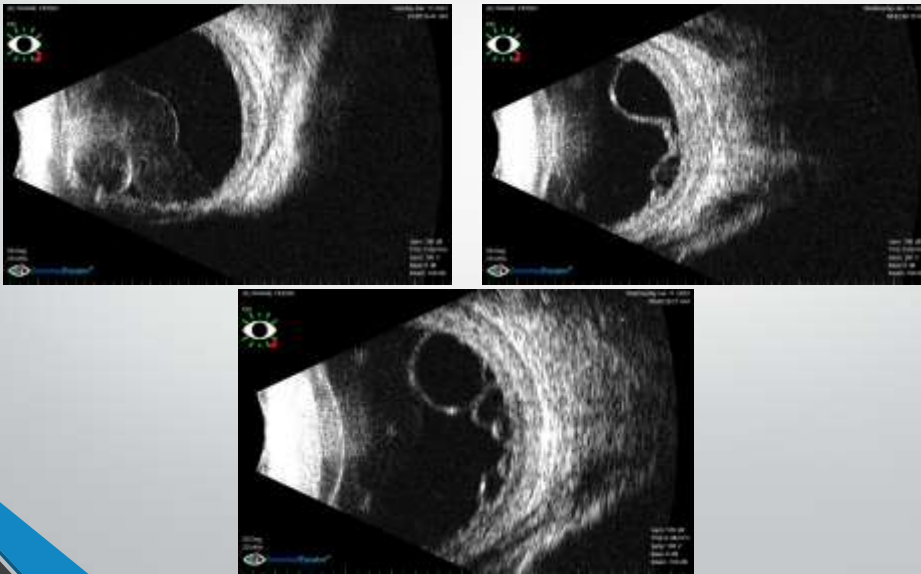
11

## Tractional Retinal Detachment



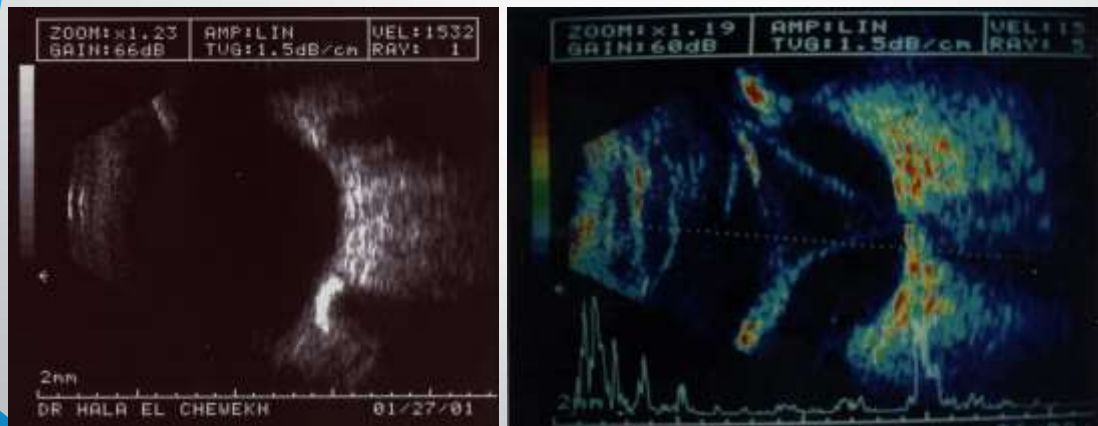
12

## Exudative RD

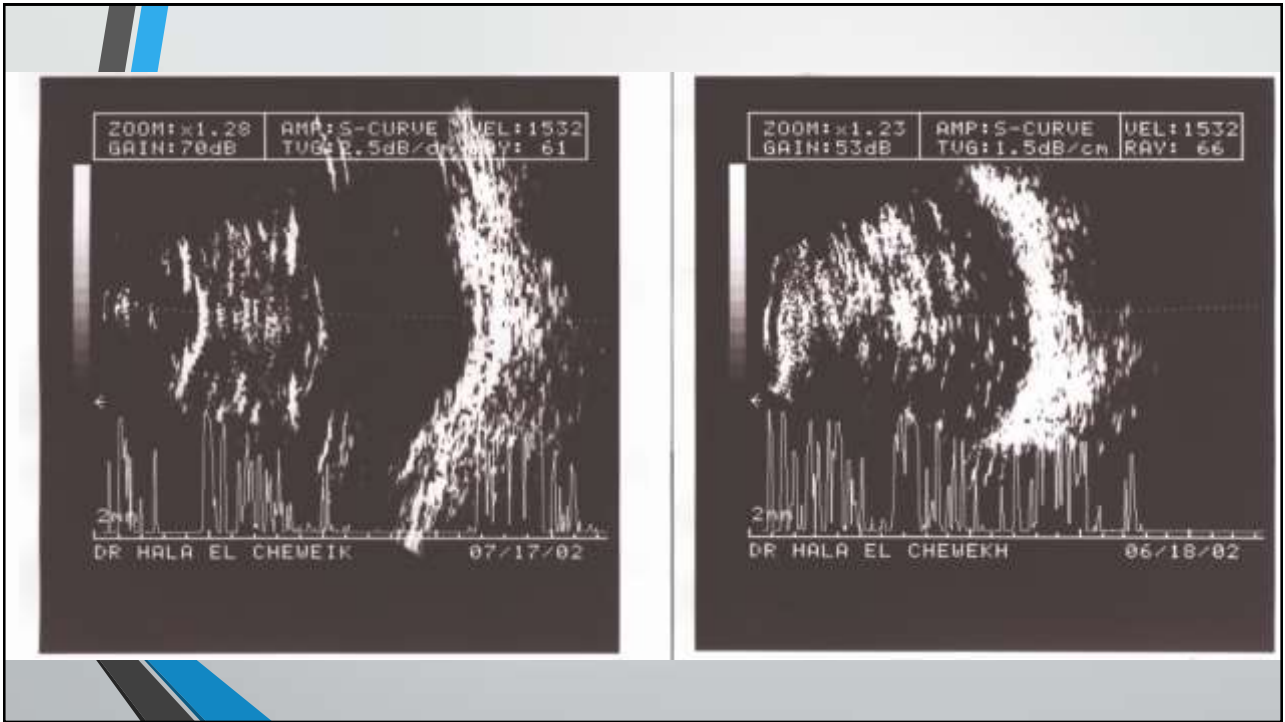


13

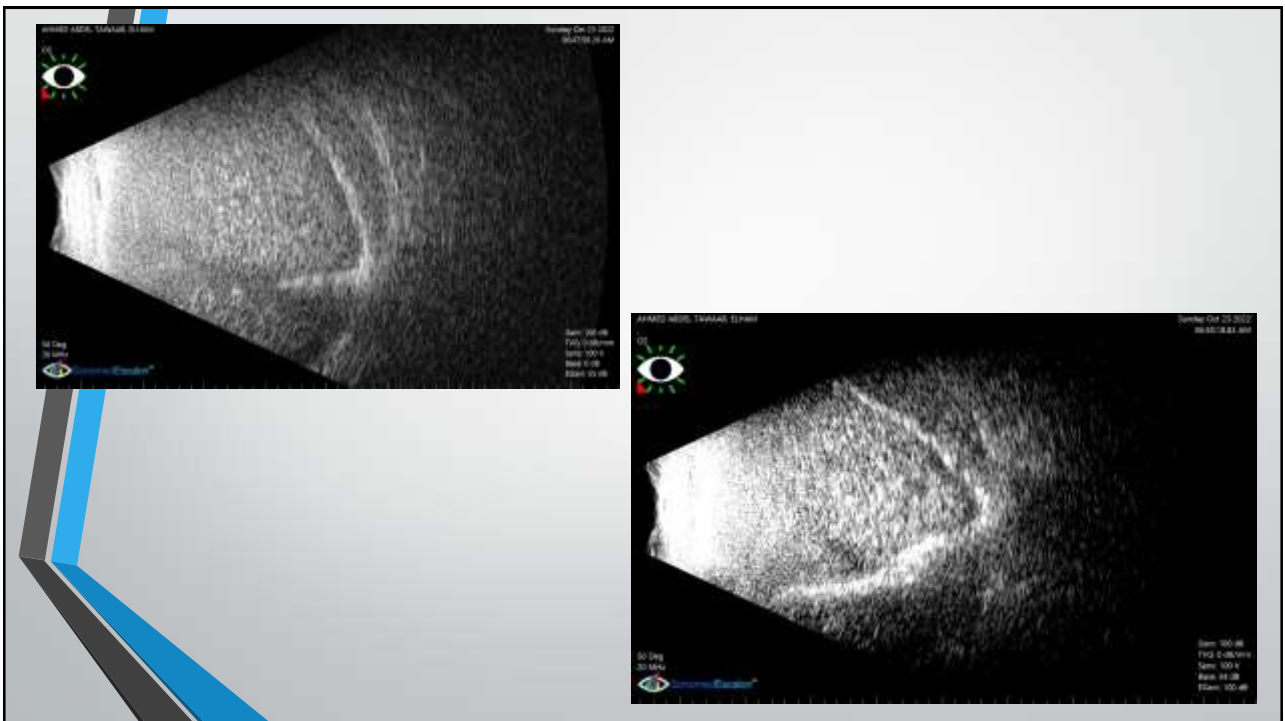
## Retinal Detachment Surgery



14



15



16

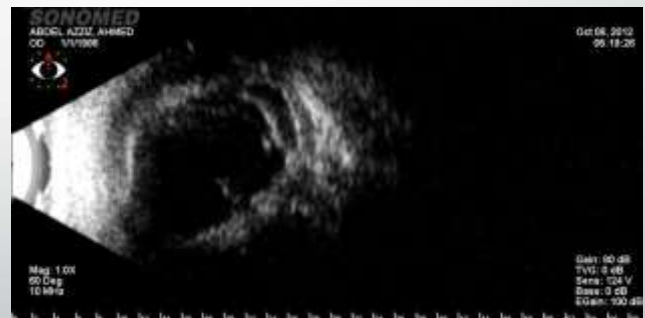
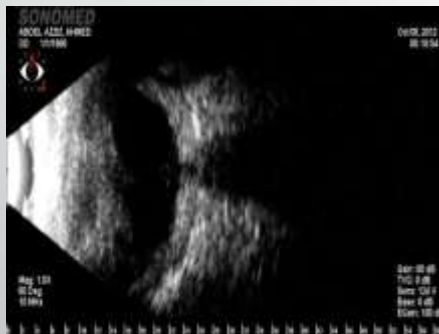

## Evaluation of Choroidal Layer

- In the normal eye using 10MHz probe generally it is difficult to differentiate the choroid from overlying retina and underlying sclera
- When the choroid and/or suprachoroidal space are expanded by fluid or infiltration ultrasound is able to image this region

17

## Hypotony with Choroidal thickening & Choroidal Detachment



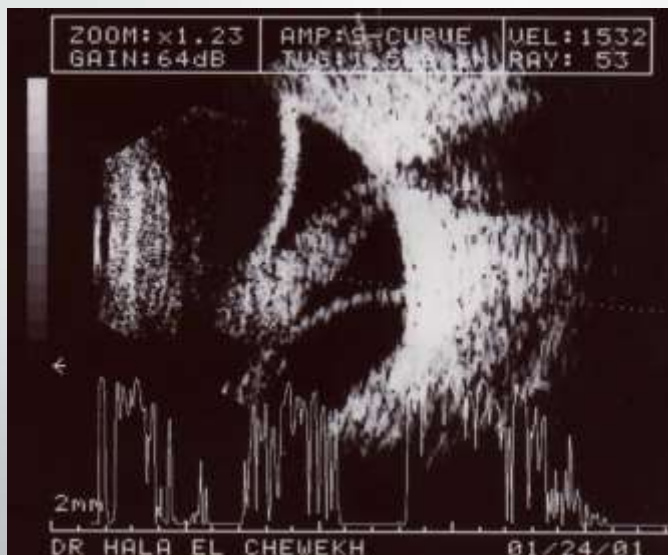18

## Choroidal Detachment

- Smooth ,thick dome shaped membrane on B-scan
- High spike steeply rising on A-scan
- Little or no after movements

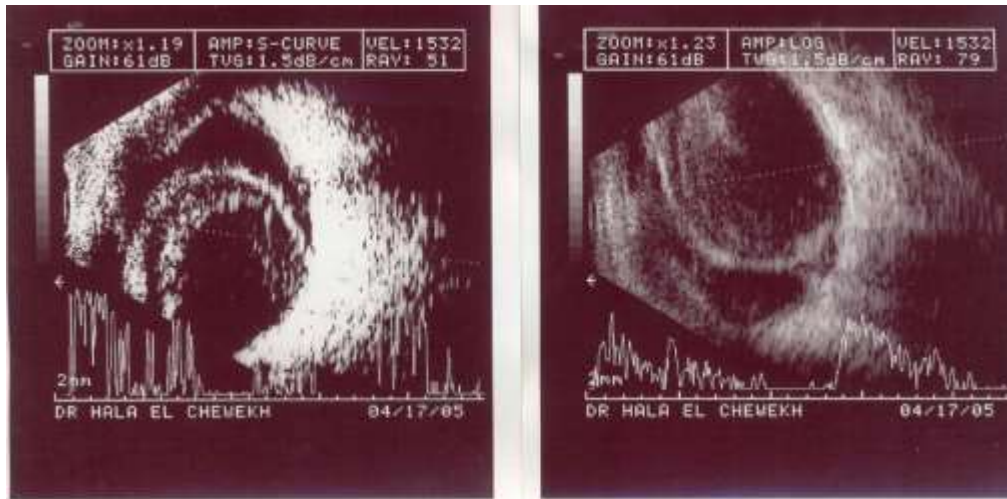
19

Choroidal Detachment may be serious with Clear  
Suprachoroidal Space



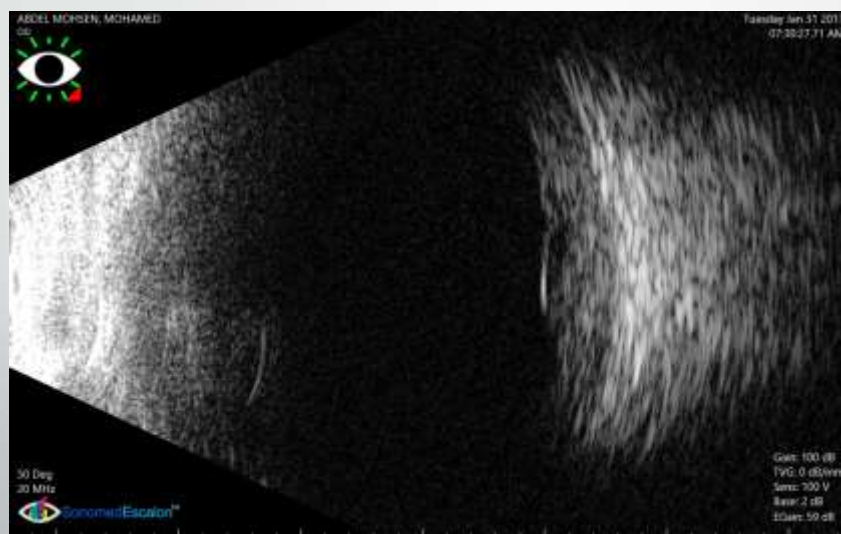
20

## Hemorrhagic Choroidal Detachment may be Traumatic or Post-operative



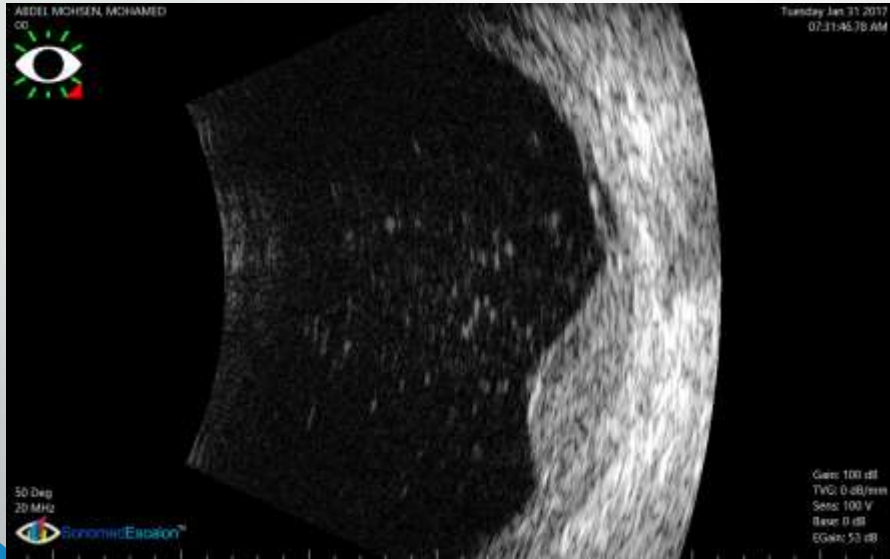
21

## Spontaneous Choroidal Hge



22

## Spontaneous Choroidal Hge



23

## How do we differentiate intraocular masses?

- When scanning we have to assess different echographic features to help us differentiate one mass from another
  - **B-scan:** shape, subretinal fluid, extrascleral extension
  - **A-scan:** Internal structure & acoustic reflectivity and sound attenuation

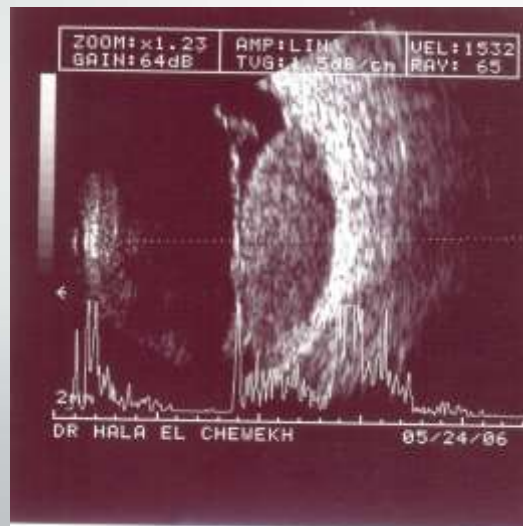24

## Key Acoustic Criteria of Malignant Melanoma of the Choroid

- Collar Button shape
- Regular internal Structure
- Low-Medium Internal Reflectivity
- Solid Consistency
- Choroidal Excavation

25

## Internal Reflectivity



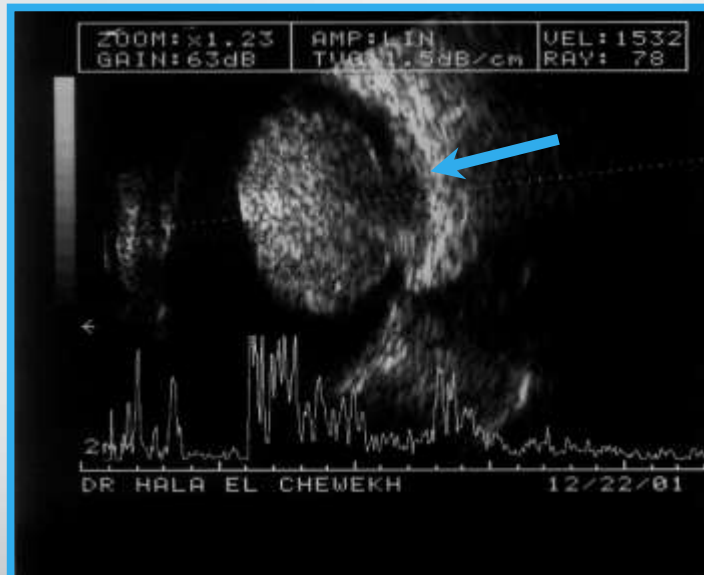
Because of their cellular homogeneous histologic architecture they are regular with internal low to medium reflectivity

26

## Different Shapes of M.M

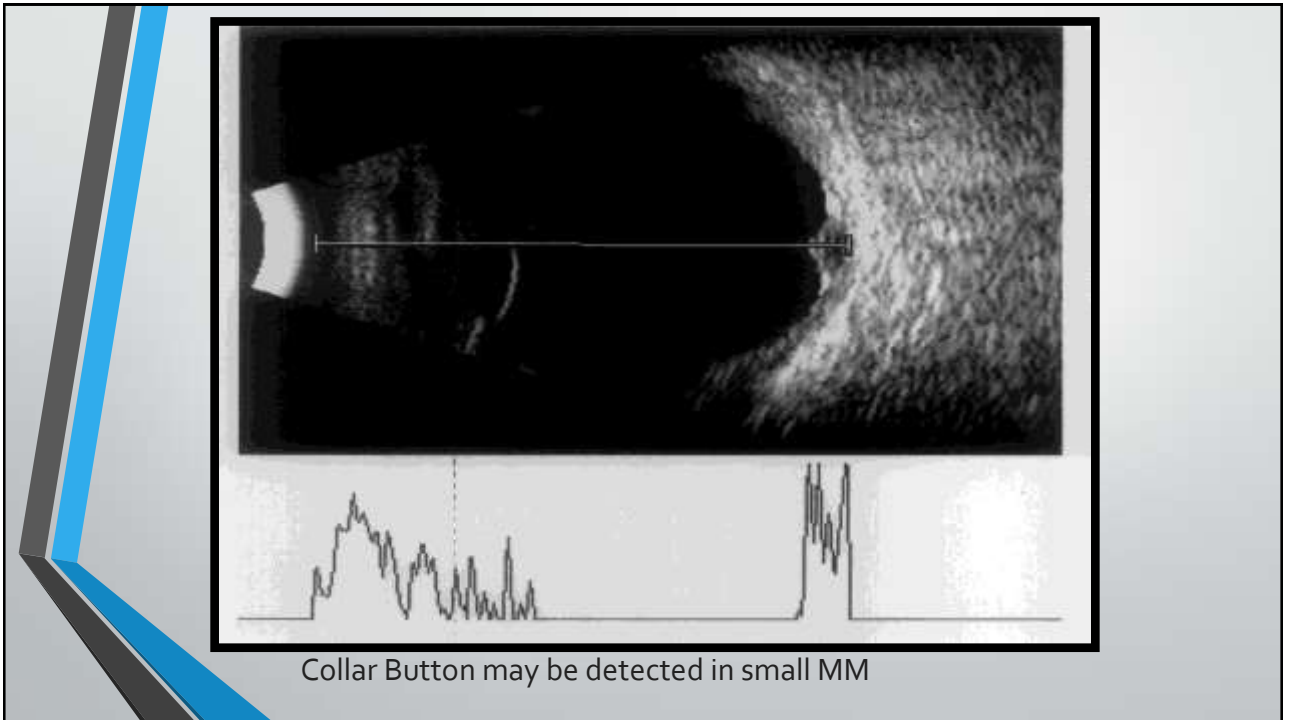
- Collar Button
- Dome Shaped
- Lobulated Surface
- Diffuse Melanoma

27

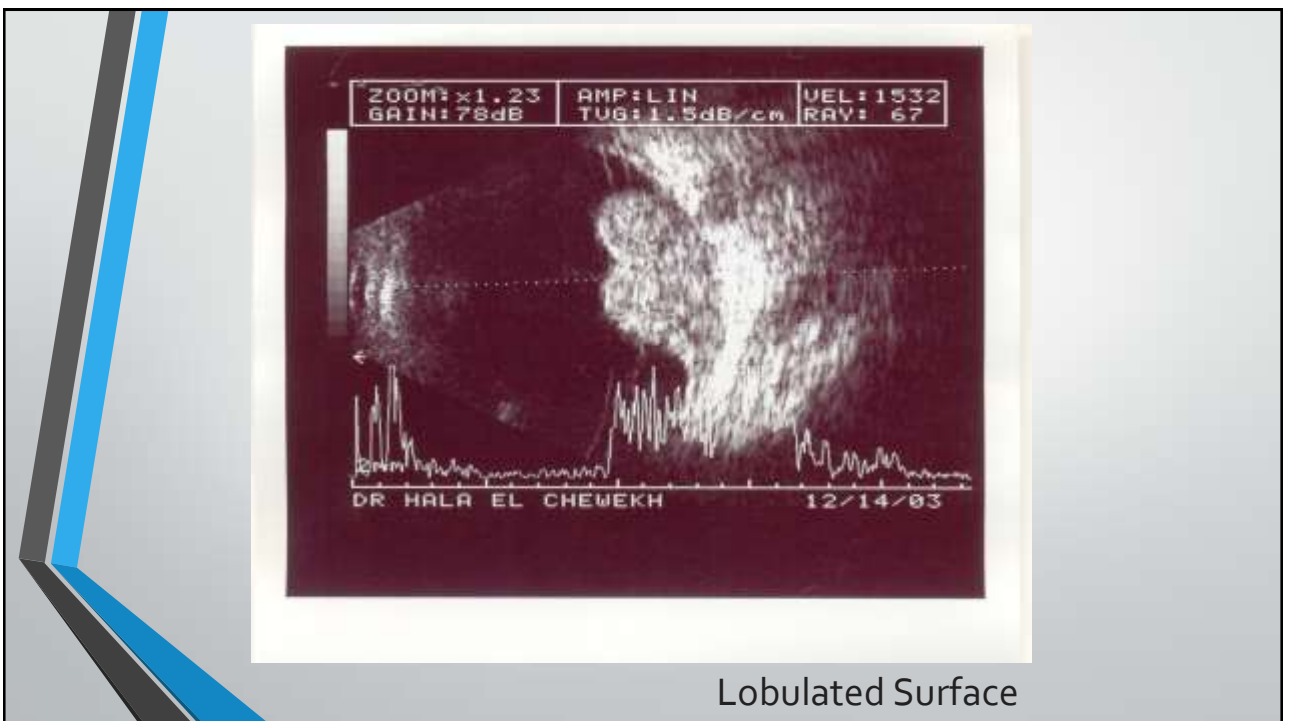


- ▶ Collar Button is an indication that the tumor has broken into Bruch's membrane

28

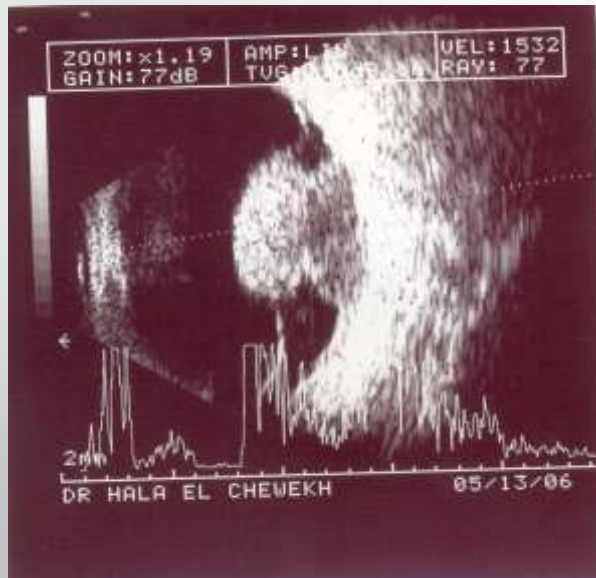

29



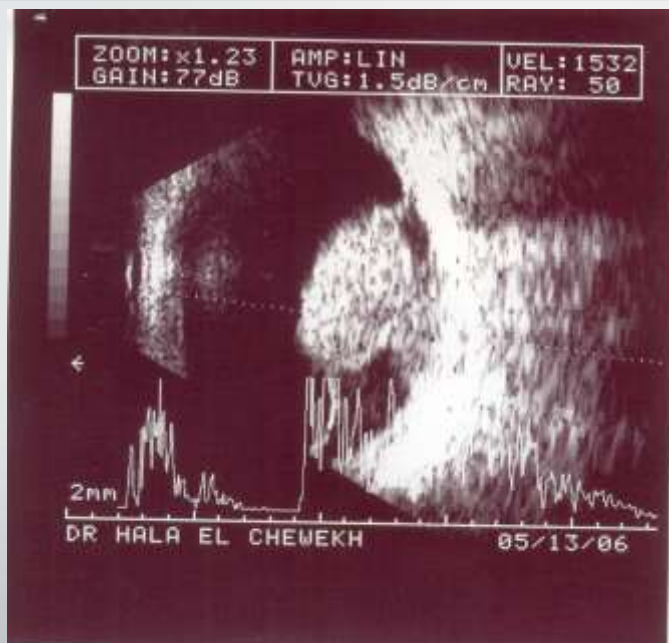
30

## "Acoustic Hollowing"



Sound attenuation leads to decrease in echo strength and reflectivity at tumor base leading to "acoustic hollowing"

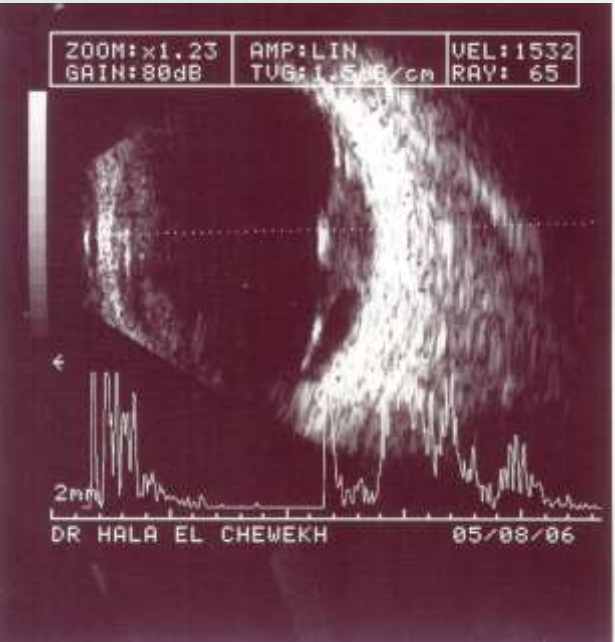
31



Sound attenuation leads to "shadowing"

32





ZOOM: x1.23    AMP: LIN    VEL: 1532  
GAIN: 80dB    TUG: 1.5dB/cm    RAY: 65

DR HALA EL CHEWEKH    05/08/06

- ▶ Another B-scan finding is Choroidal excavation at the base of the tumor
- ▶ 2ry retinal detachment extends from the margins of the tumor towards the lower periphery (rarely over the apex )

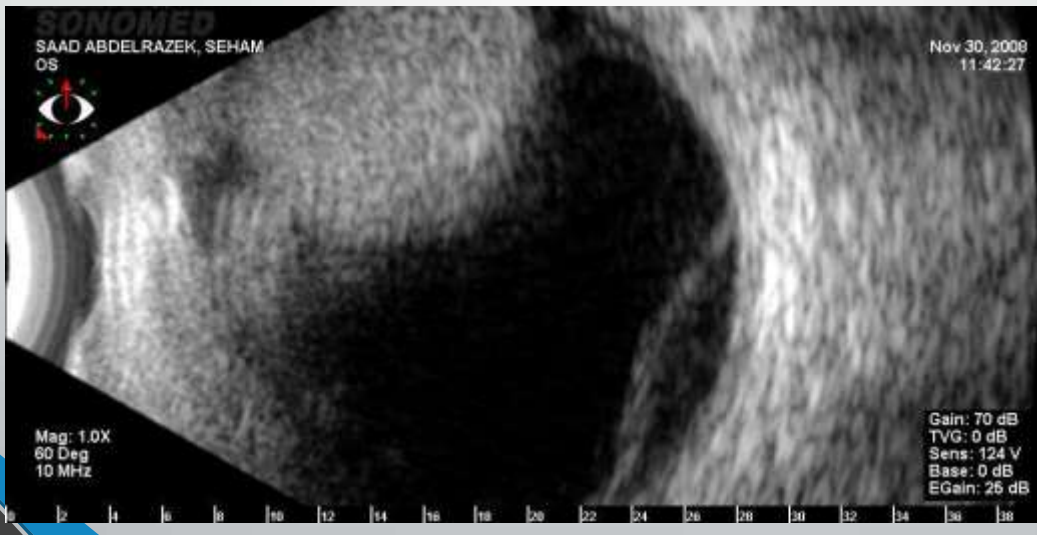
33

## Measure Dimensions using A&B-scan

- **Base** –In both transverse and longitudinal views
- **Height**-from tumor apex to bright inner scleral echo not including RD if present
- **A-scan**- from highest tumor spike to inner scleral spike.

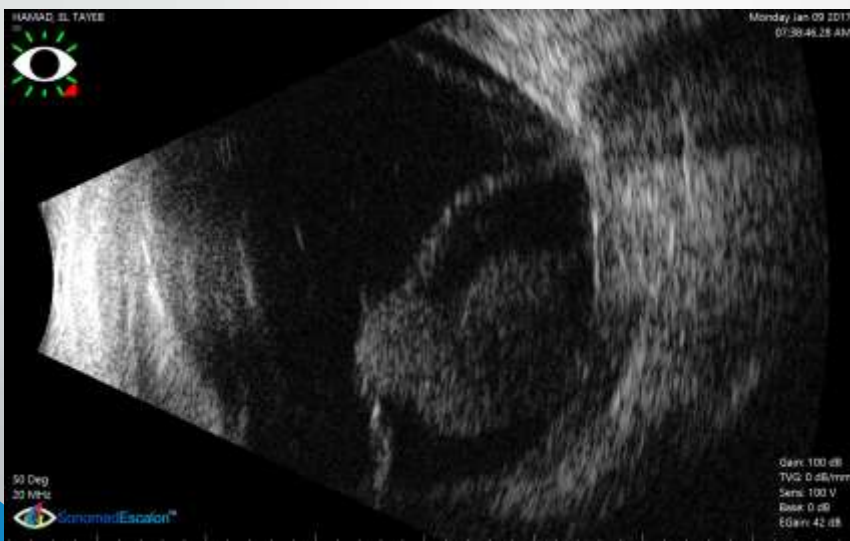34

## Large Malignant Melanoma with CB Extension



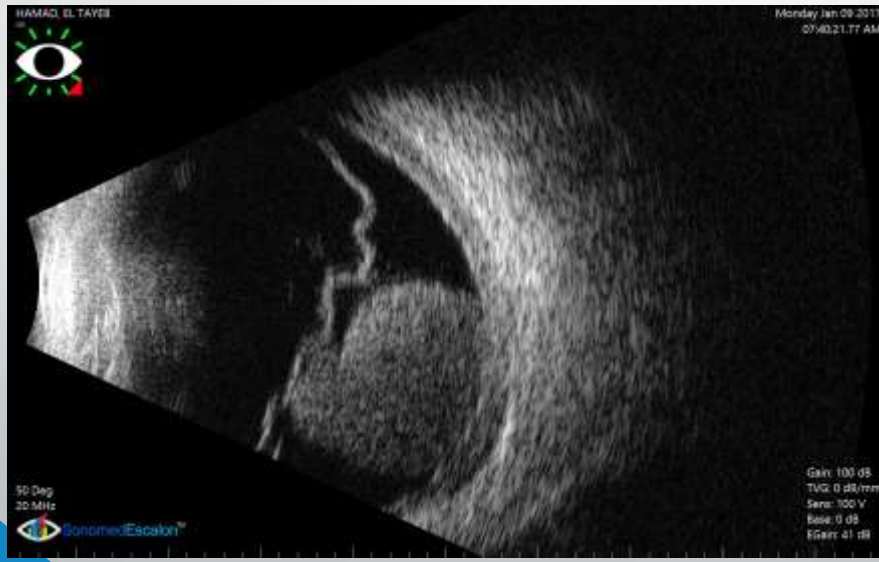
35

## Extra Scleral Extension



36

## Extra Scleral Extension



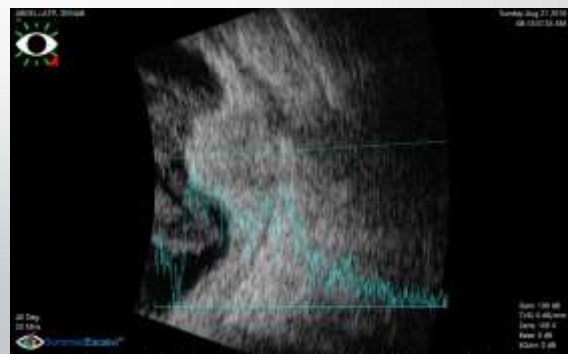
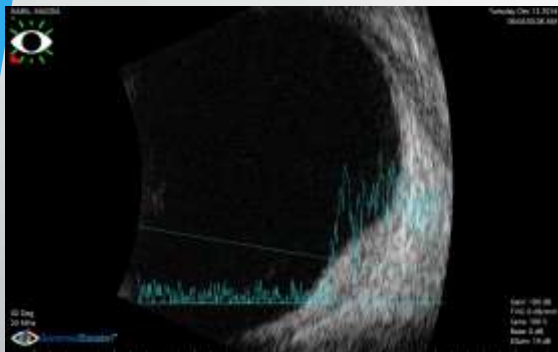
37

## Post Irradiation Findings Changes in the tumor

- 1- More irregular internal structure
- 2- Higher internal reflectivity
- 3- Decreased size
- 4- Decreased internal vascularity

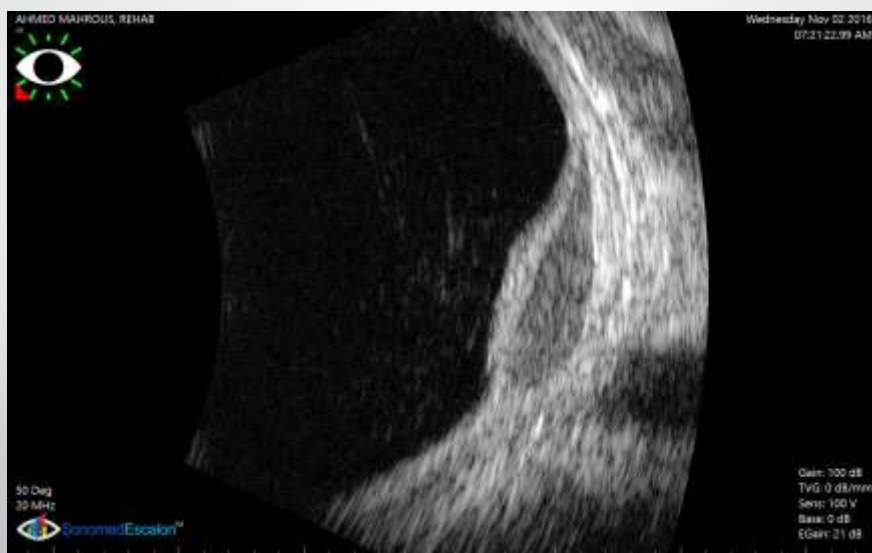
38

## Change in internal reflectivity post-radioactive plaque



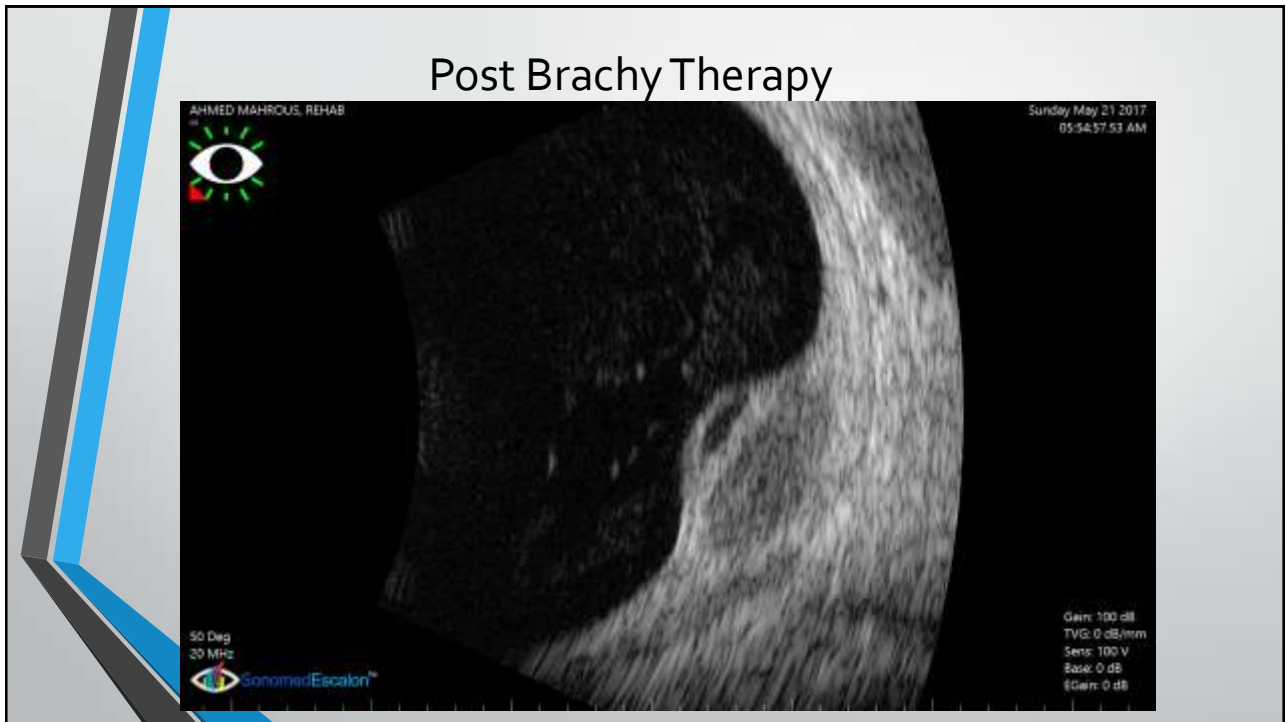
39

## Malignant Melanoma PrebrachyTherapy



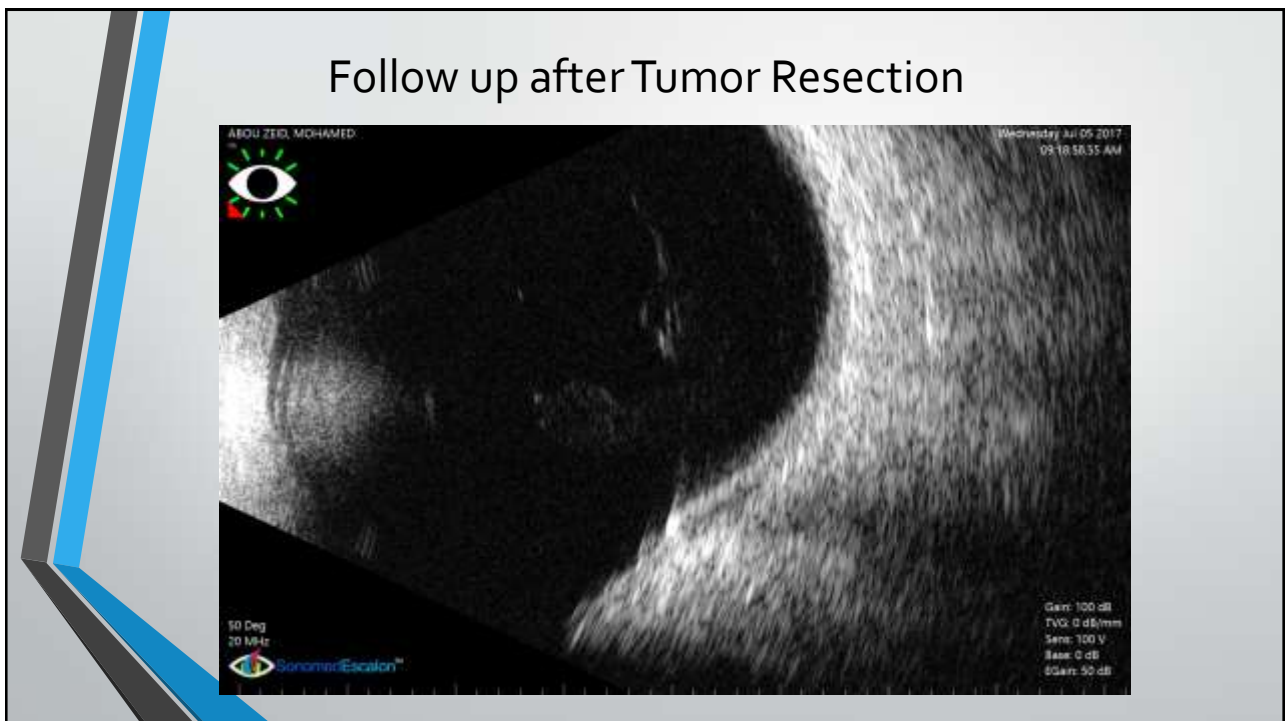
40

## Post Brachy Therapy



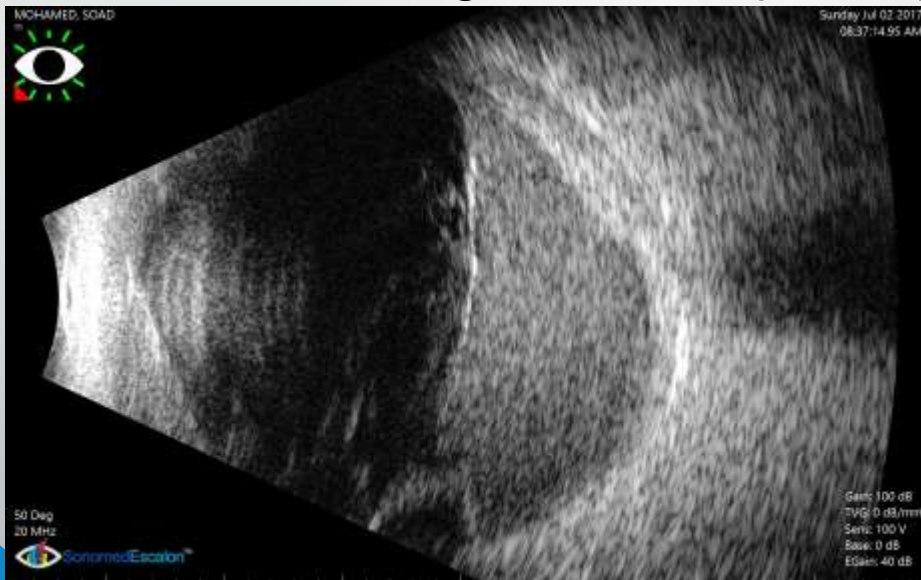
41

## Follow up after Tumor Resection



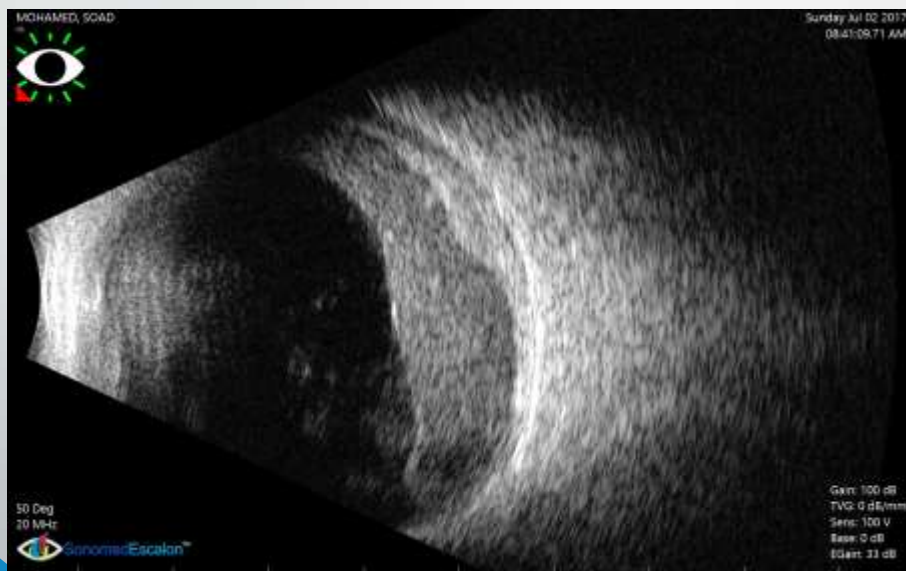
42

## Dense Vitreous Hge Post Brachy Therapy



43

## Dense Vitreous Hge Post Brachy Therapy (Cont'd)



44

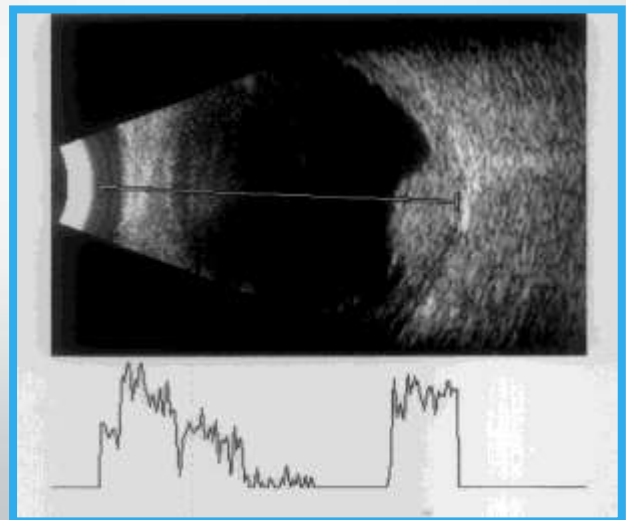
## Pseudomelanomas

1. Choroidal Hemangioma
2. Disciform Lesion
3. Metastatic Carcinoma to the Choroid
4. Choroidal Hemorrhage (Focal)
5. Posterior Nodular Scleritis
6. Choroidal Naevus.

45

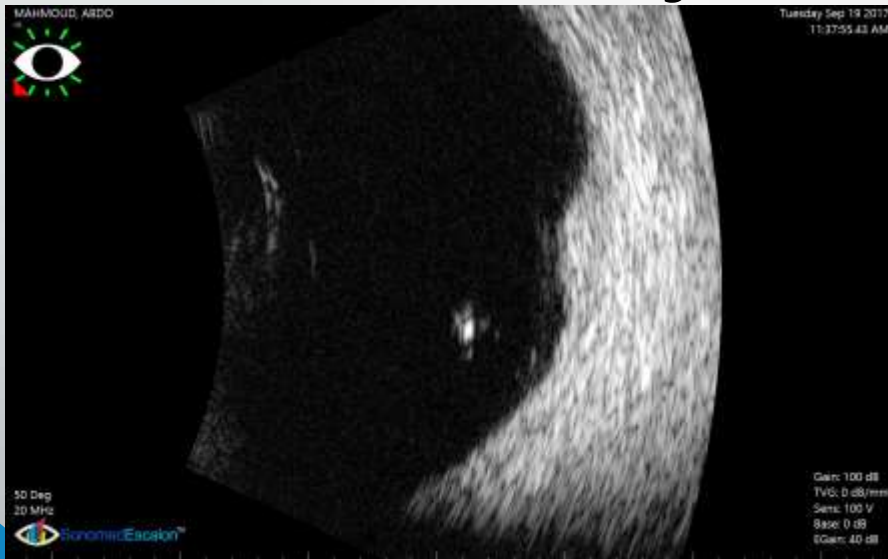
## Acoustic Criteria of Choroidal Hemangioma

- Located at posterior pole temporal to the disc.
- Dome shaped with regular structure and high internal reflectivity.
- Serous Retinal detachment can be present at tumor margins.



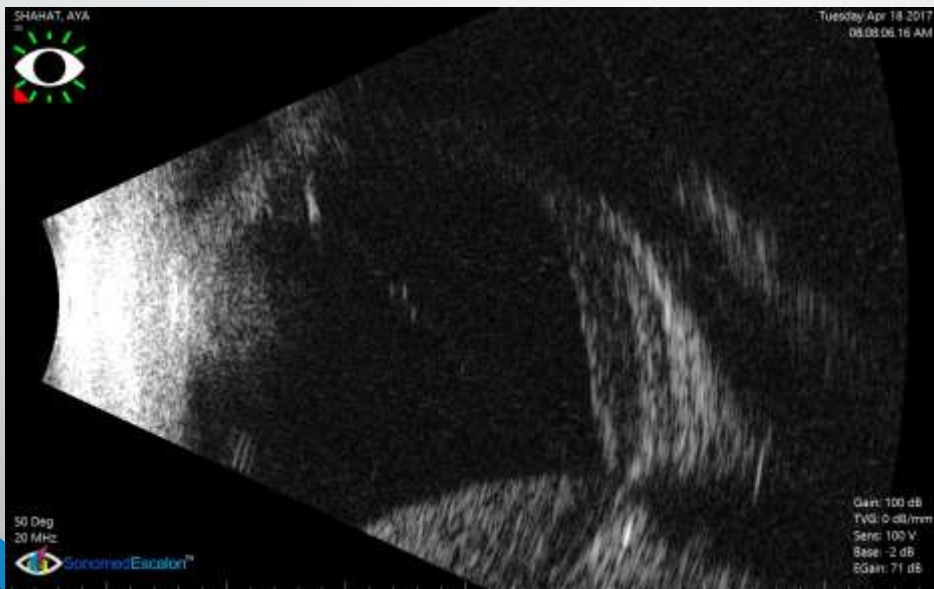
46

## Focal Choroidal Hemangioma



47

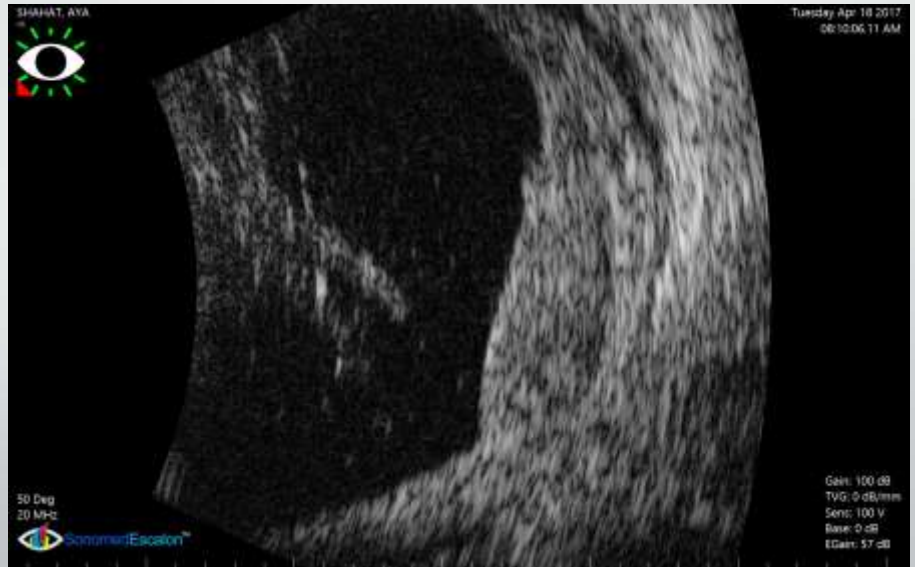
## Sturge Weber Syndrome



48

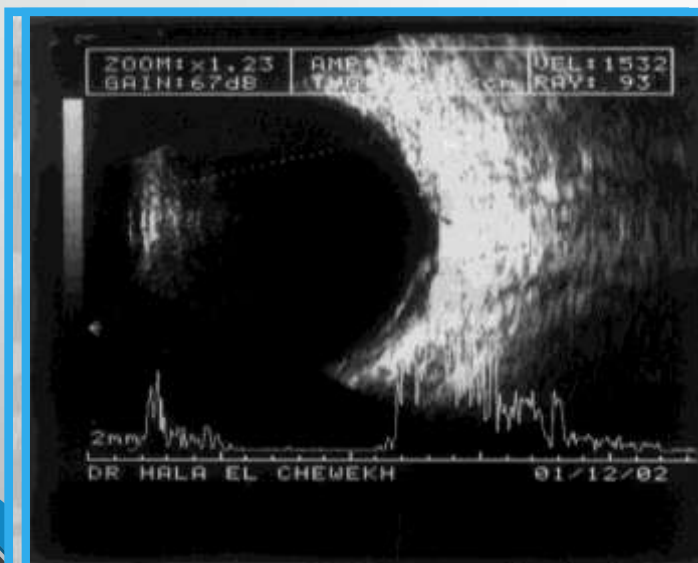

## Sturge Weber Syndrome



49

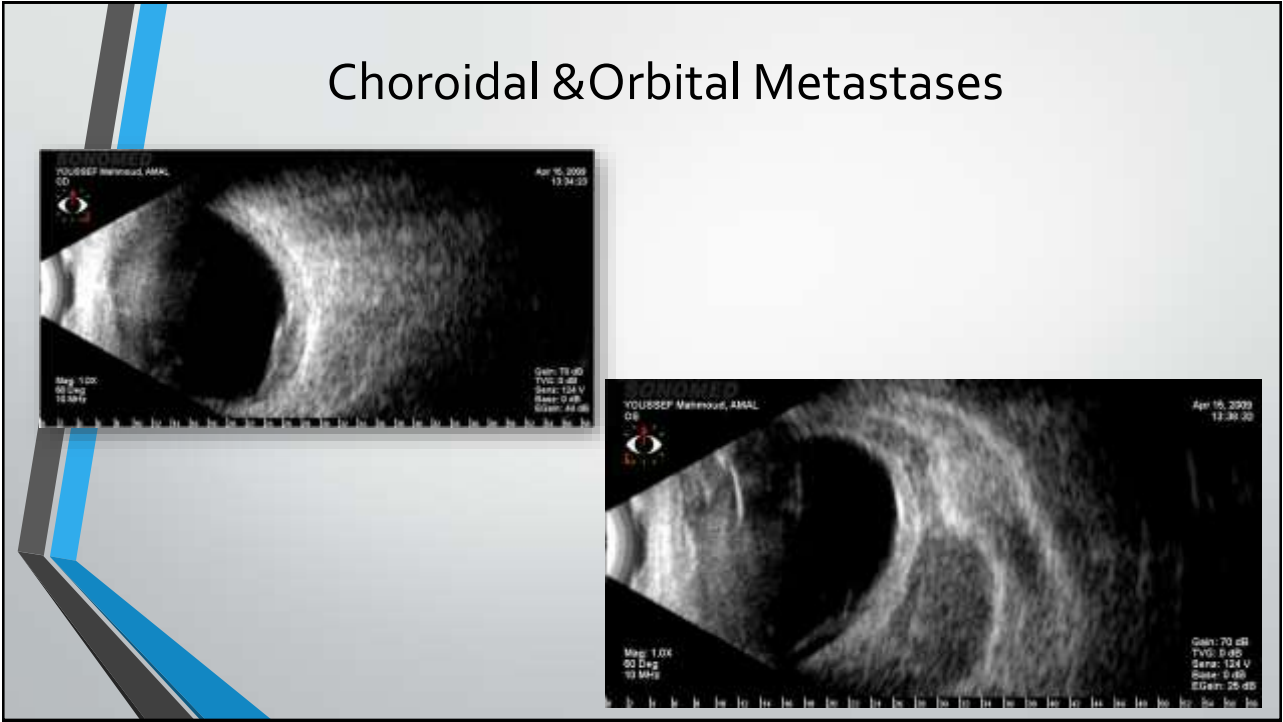
## Metastatic Carcinoma



- Involving posterior choroid
- Bumpy appearance and irregular reflectivity
- More extensive RD

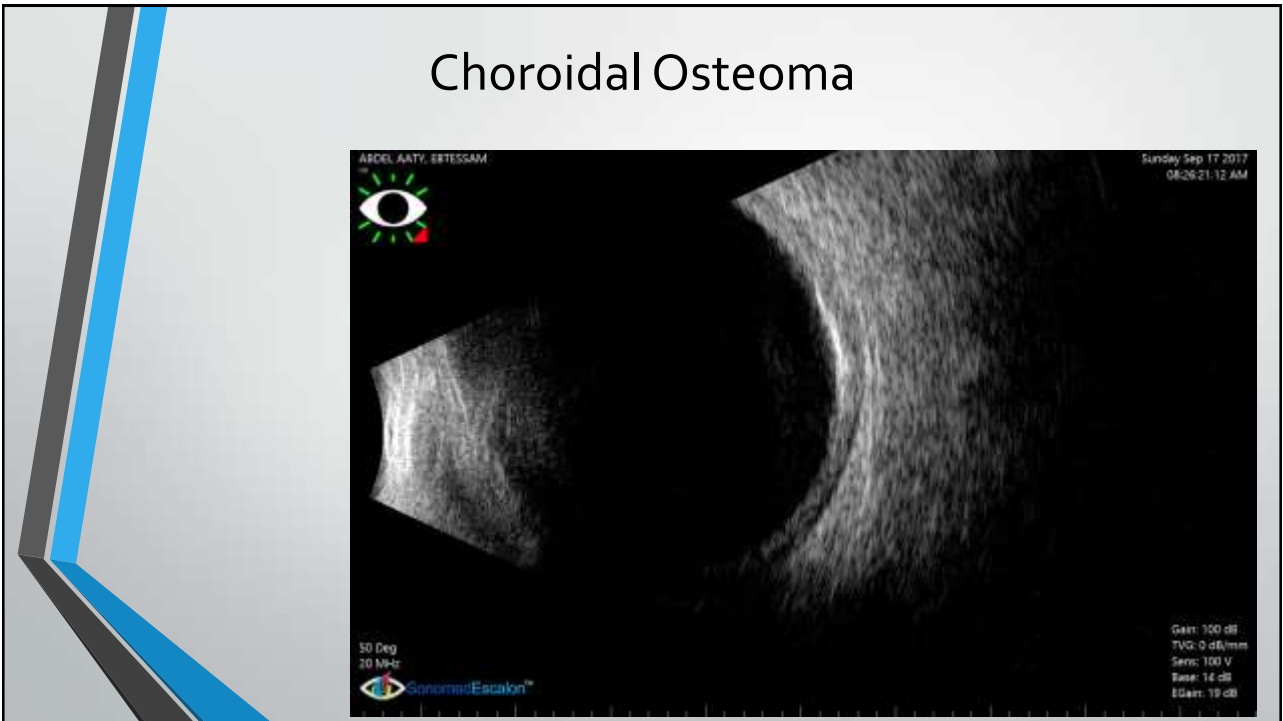
50

# Choroidal & Orbital Metastases



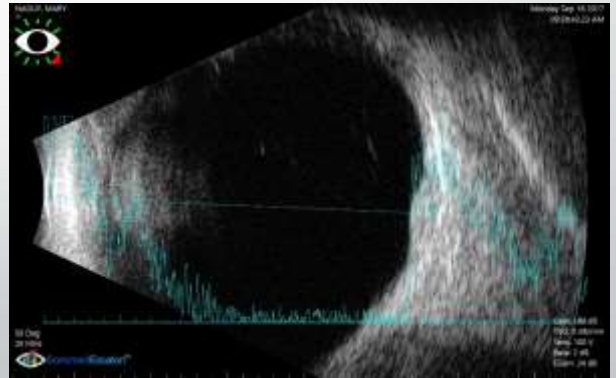
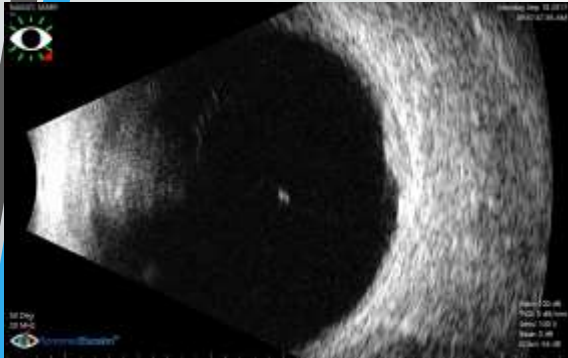
51

# Choroidal Osteoma



52

## Choroidal Nevus

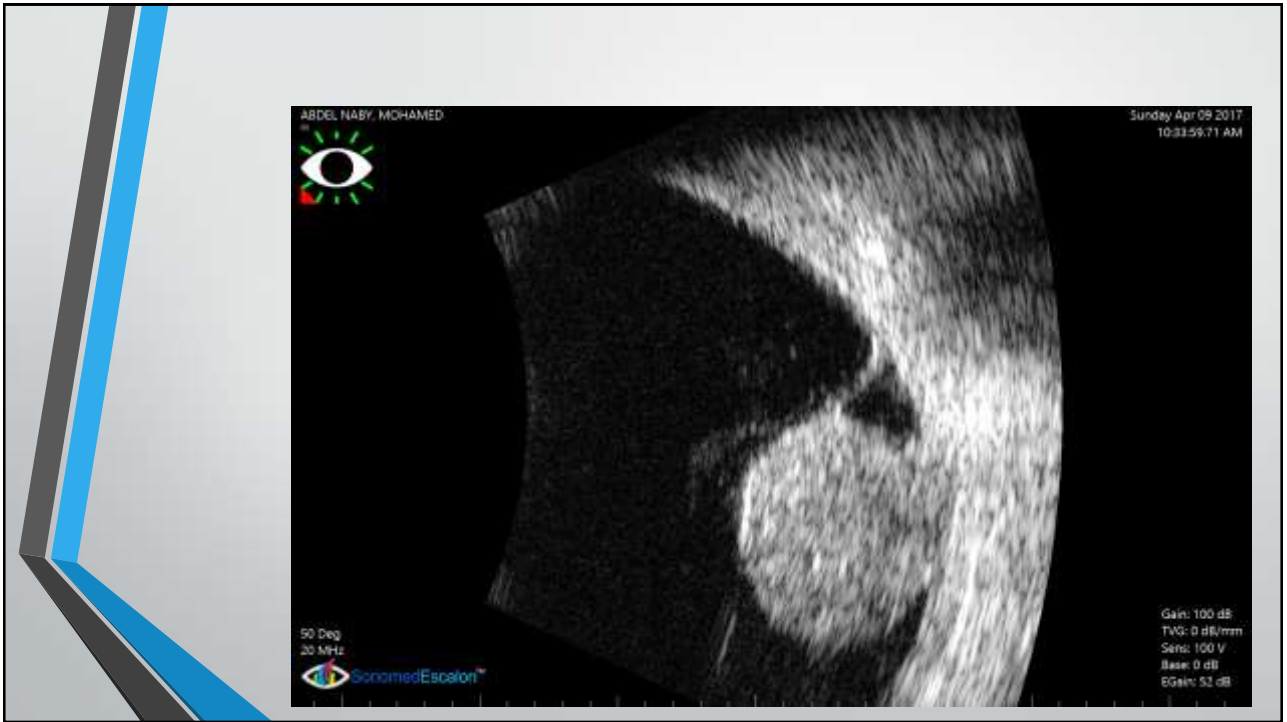


53

If there is still diagnostic doubt serial examination allows us to reassess for....

- Growth rapid in metastatic lesion with increase in extent of exudative detachment
- Slower in melanoma & haemangioma
- None in choroidal naevus
- Reduction in size in disciform haemorrhagic lesion.

54



55



56