

المؤتمر السنوي الدولي للجمعية المصرية
INTERNATIONAL CONGRESS OF THE

EGYPTIAN OPHTHALMOLOGICAL SOCIETY

EOS 2023

Capsulorhexis And Hydrodissection

Alaa Mahmoud Ahmed , MD

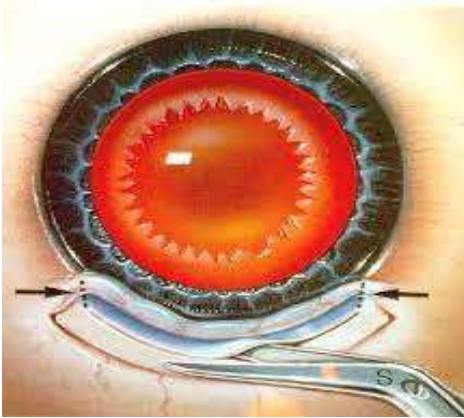
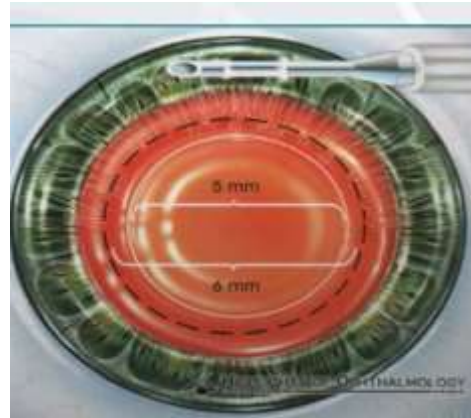
Lecturer Of Ophthalmology
Faculty Of Medicine
Sohag University



Capsulorhexis

- **Idea** : continuous circular opening in the anterior capsule.



Anterior capsulotomy**Anterior capsulorhexis****EOS 2023**

Essentials

- Operating microscope:
 - Focus on anterior capsule
 - increased magnification
- Surgeon:
 - careful
 - operate slowly

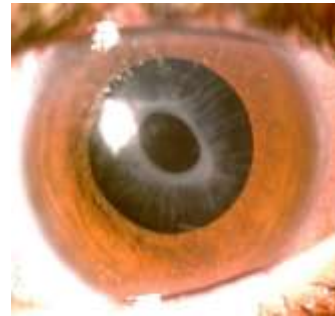EOS 2023

Rhexis Size

- Ideal size: 4-5 mm




- Smaller :Phimosis



Instruments

- Cystitome
 - tip bent =90°
 - =1mm
 - =sharp



EOS 2023



•Forceps:


- used in all cases
- specially (intumescent – congenital- rhexis escape)

•Types:

- Sharp tips
- blunt Tips



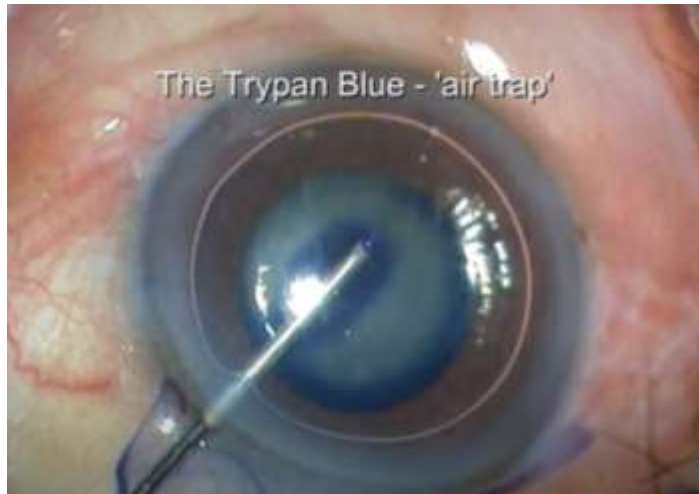Shearing or Ripping



Shearing and ripping force applied to tearing a piece of paper. **(a)** Shearing force. Direction of force (*black arrow*) is in the same direction as the intended tear (*white arrow*). Little effort to tear the paper. **(b)** Ripping force. Direction of force (*black arrow*) is 90° to direction of intended tear (*white arrow*). Force is spread over wider area and additional effort required.



Trypan Blue Staining Of The Anterior Capsule




Start Rhexis



Starting Point

At the Geometric center of the lens



Create the capsular flap

- Move laterally in a curved manner
R=1/2 at rhexis
create the flap
- direction : - clock wise
-Anti-clockwise

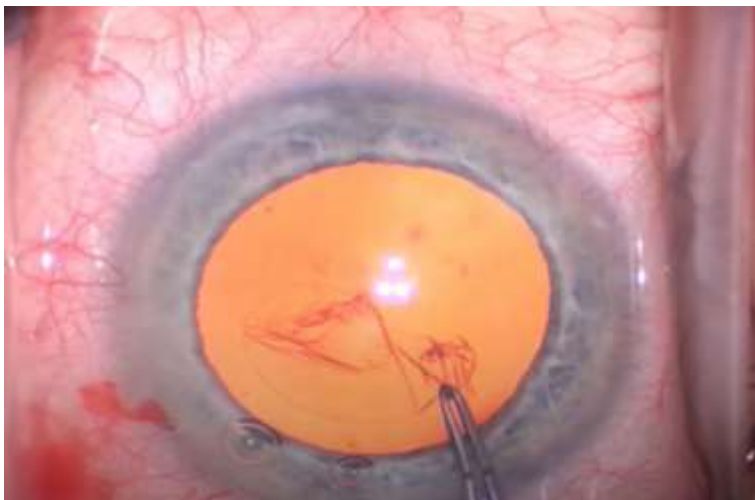

4 Golden Rules

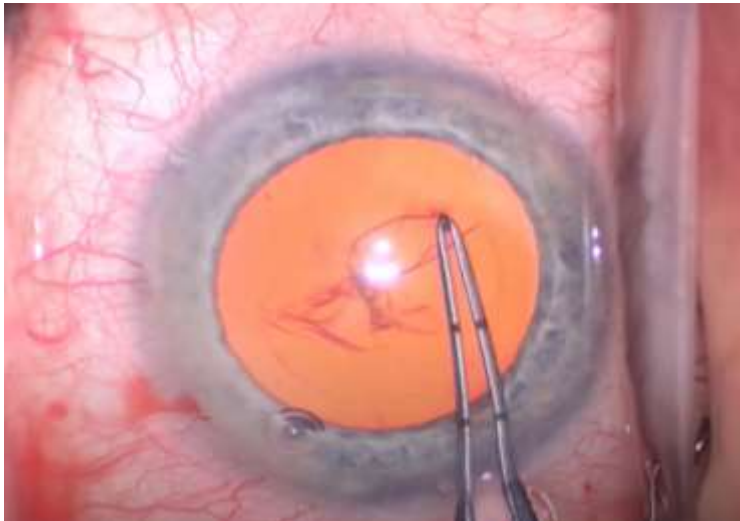1. Deep anterior chamber



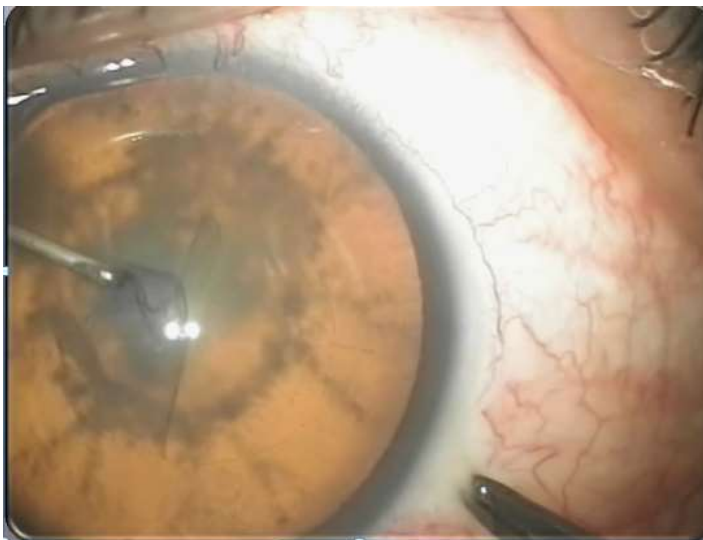2. Hold Near The Tearing Edge



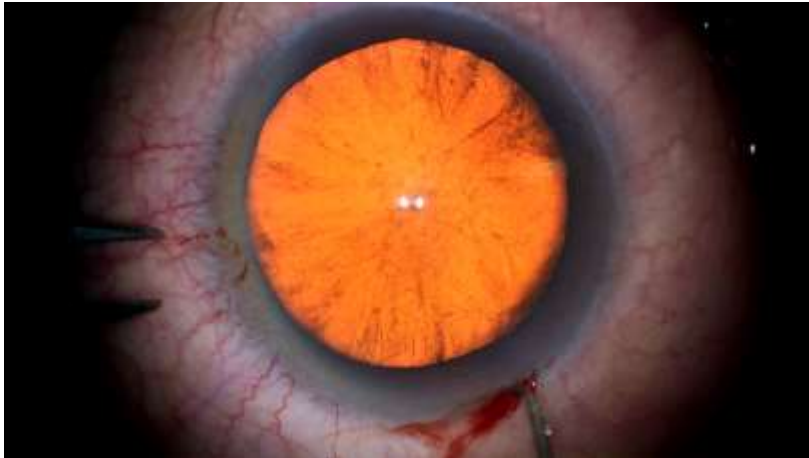3. Move and Re-grasp every 2 clock hours



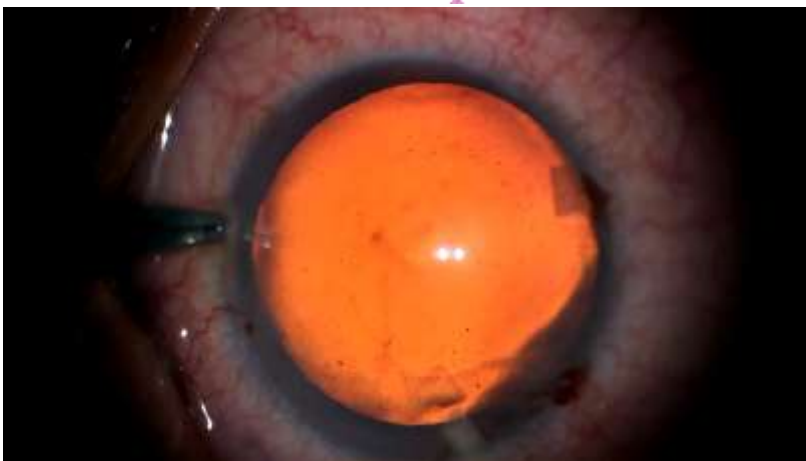4. Bring the flap to the center

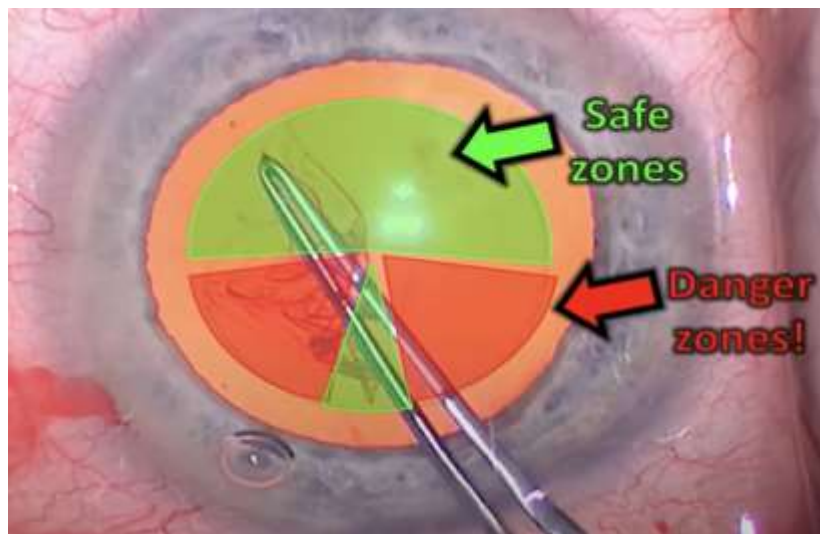


Surgical Technique Using Cystitome



Surgical Technique Using Rhexis Forceps

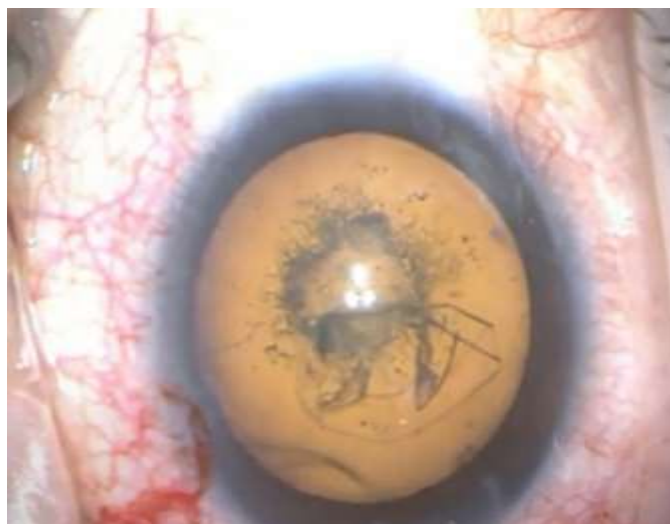



EOS2023



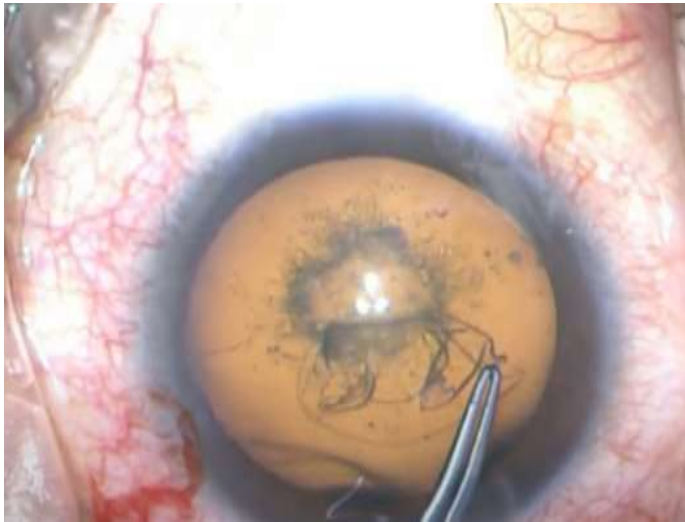
Extended Rhexis



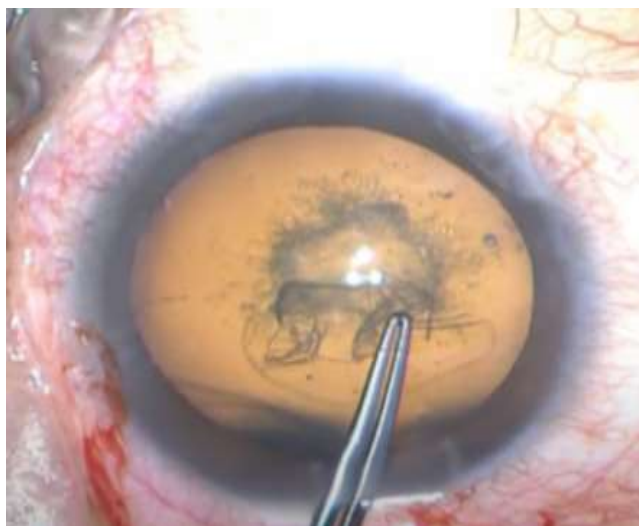
EOS2023



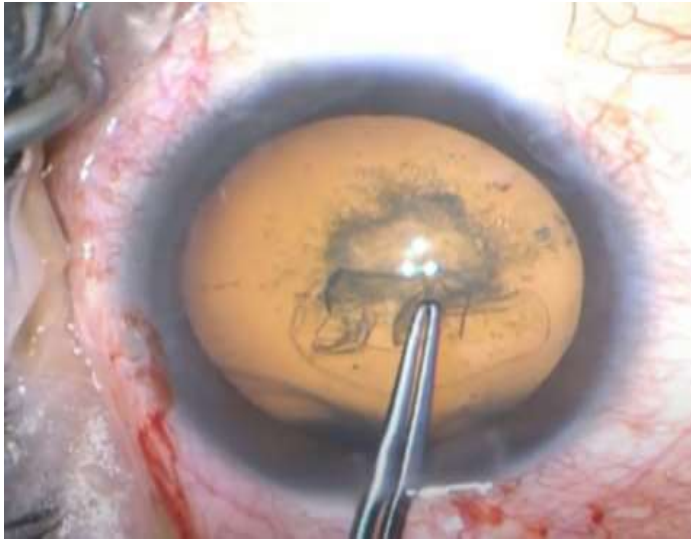
Little Capsulorhexis Technique



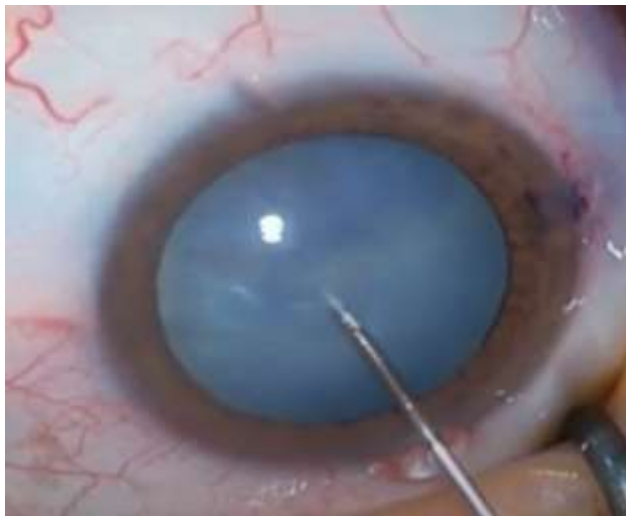Little Capsulorhexis Technique



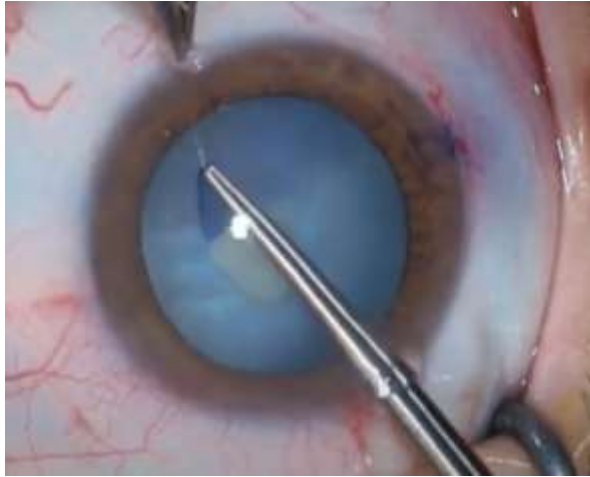Little Capsulorhexis Technique



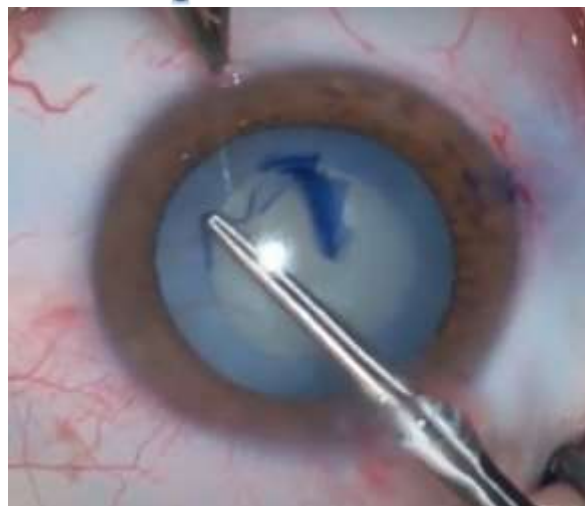White Intumescent Cataract A- Needle Decompression Technique



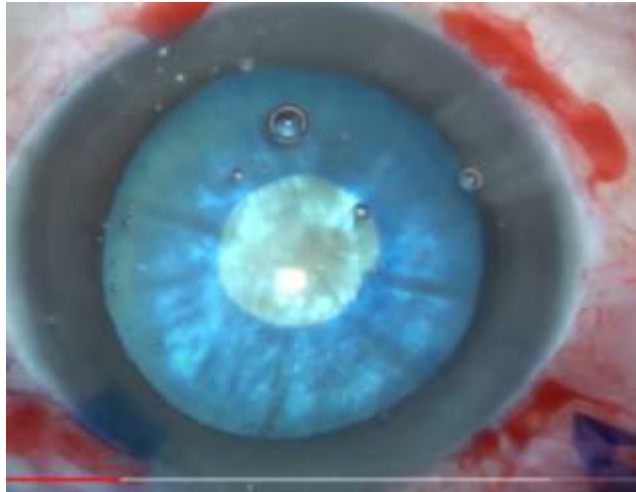
Start Small Capsulorhexis



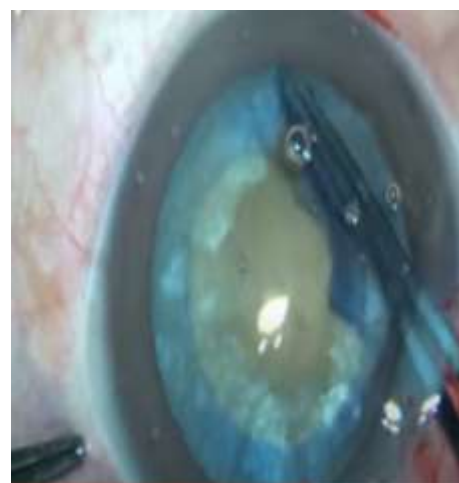
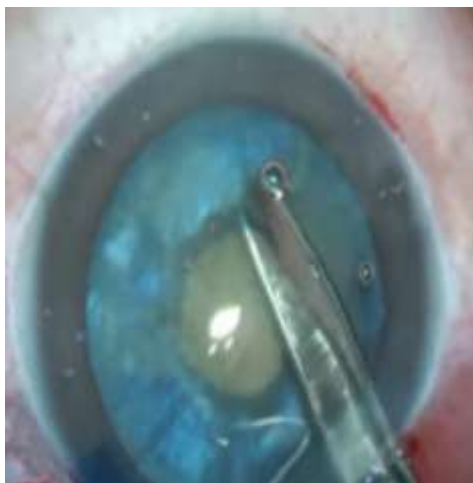Spiral Rhexis



B- Double capsulorhexis in white intumescent cataract



Double Rhexis Technique

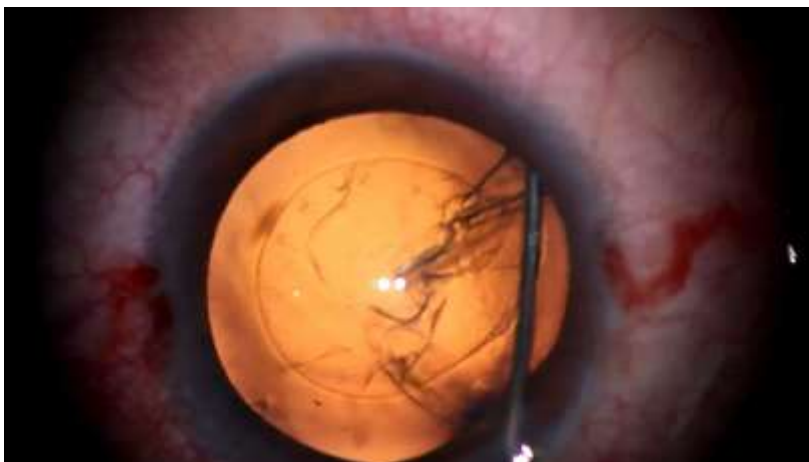

Hydrodissection

- ▣ Definition
- ▣ Function



- ▣ **Technique**



CI Of Hydrodissection

PPC



Extended Rhexis
Capsulotomy



Morganian cataract

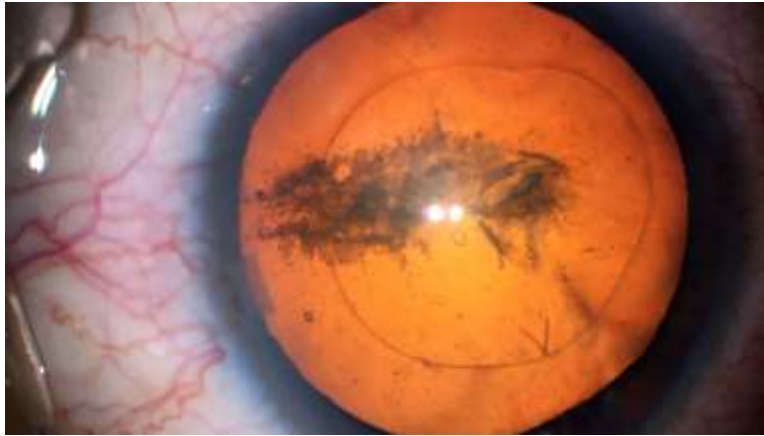


Hydrodelineation

- Definition
- Function



Hydrodelineation Technique



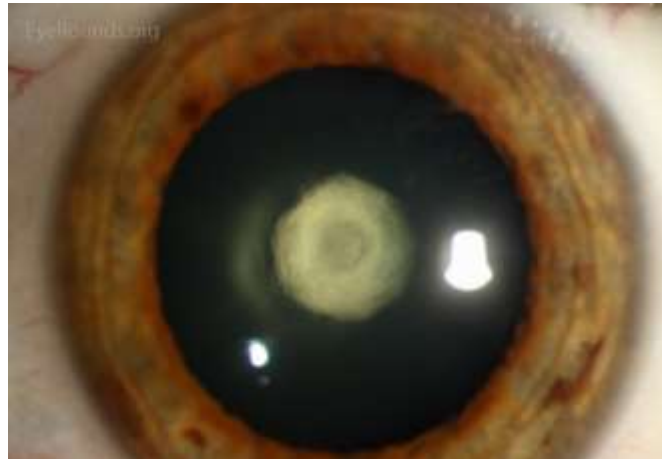
SPECIAL SITUATIONS



Posterior Polar Cataract

Rhexis

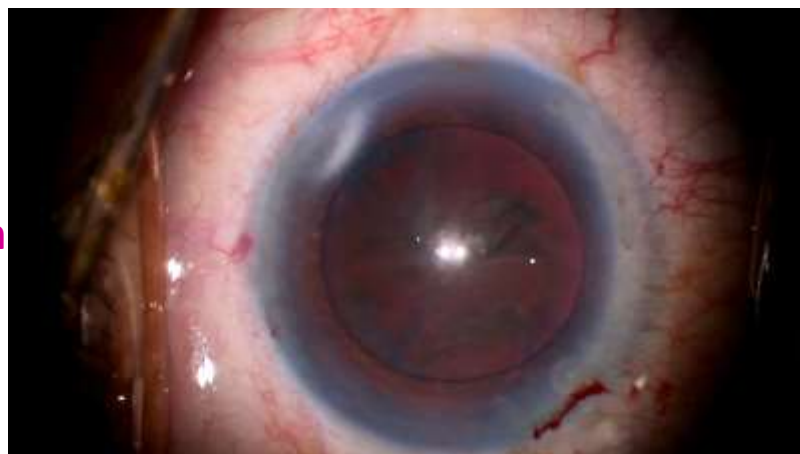Hydrodissection



Hard cataract

Rhexis

Hydrodissection



Capsular Block Syndrome

Small capsulorhexis

Pre-dispose to posterior dislocation of the nucleus

Large nucleus

Aggressive fluid injection



Capsulorhexis





THANK YOU

See you next year

المؤتمر السنوي الدولي للجمعية الرمدية المصرية

INTERNATIONAL CONGRESS OF THE

**EGYPTIAN
OPHTHALMOLOGICAL SOCIETY**

EOS 2024

24-26 APRIL 2024

InterContinental Citystars, Cairo, Egypt

