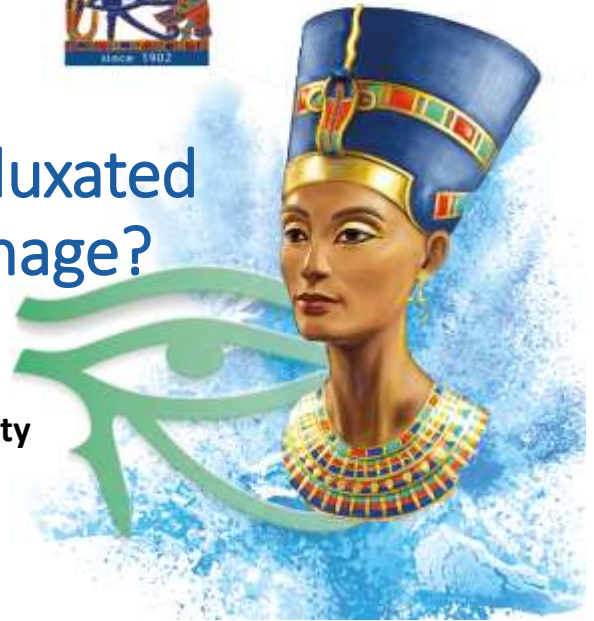

المؤتمر السنوي الدولي للجمعية المصرية
INTERNATIONAL CONGRESS OF THE

EGYPTIAN OPHTHALMOLOGICAL SOCIETY

EOS 2023



Traumatic Severely Subluxated Cataract, How to Manage?

By

Dr. Adham Salah

Lecturer of Ophthalmology, Sohag University

FRCsed

No Financial Interest



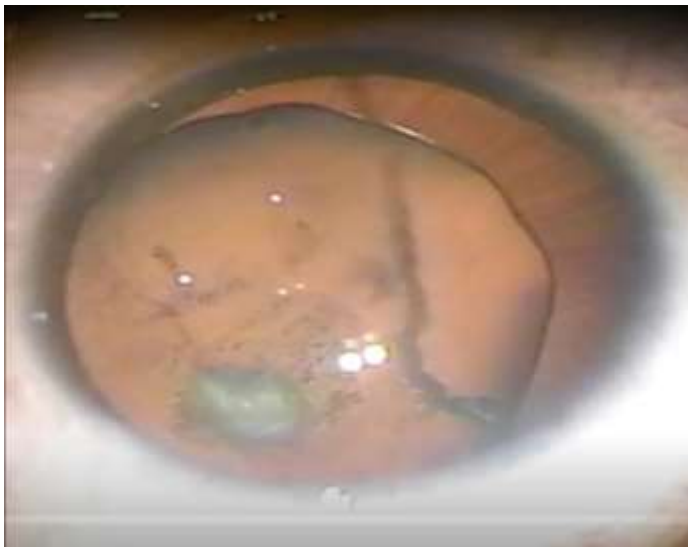History


- 28 years old male
- History of blunt trauma to the Rt. eye 3 years ago

	OD	OS
UCVA	0.05	0.1
Refraction	-10.00 DS, -4.00 DC, 20	-8.00DS, -0.50DC, 120
BCVA	0.2	0.9
Keratometry	43.25 D 44.25 D	43.50 D 44.25 D

Examination:

- OD: Severely subluxated cataract, vitreous strands in AC.
- OS: Free





Postoperative result

- UCVA 0.7
- Refraction +0.50 DS, -1.25 DC, 14

REFI	UD: 12.0		
	Cyl. Form: (-) A		
TR>	SPH	CYL	AX
	+0.50	-1.25	14 D
	+1.00	-2.00	169 D
UE	+0.50	-1.25	14

Take Home Massage

- Always pressurize the globe
- Prepare your weapons
- Ensure there is no vitreous
- Forceps is better than cystotome
- Inject OVD at dialysis site
- CTR as late as possible

