


بسم الله الرحمن الرحيم

Advanced Phaco. Course

Phaco. Incisions

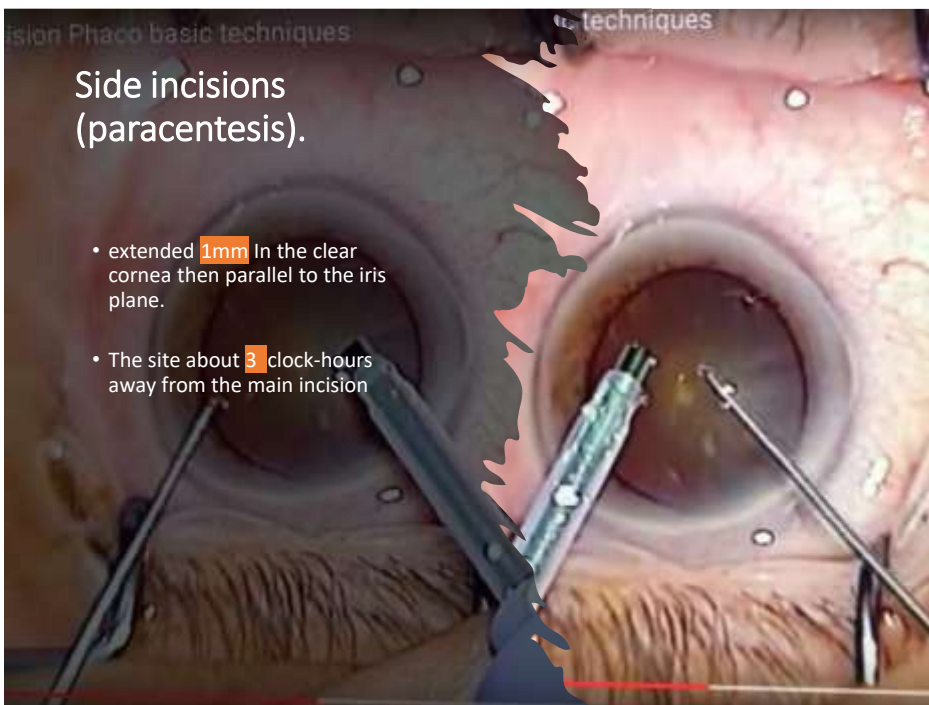
Prof : Ahmed Mostafa Eid, MD
Minia University
EOS 2023





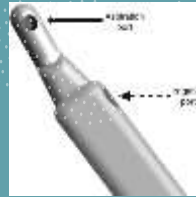
The phaco. incisions

- Main incision
- Side incision (paracentesis)



One paracentesis.

Those surgeons use coaxial I/A to the left in right-handed surgeon and to the right in left-handed surgeon.



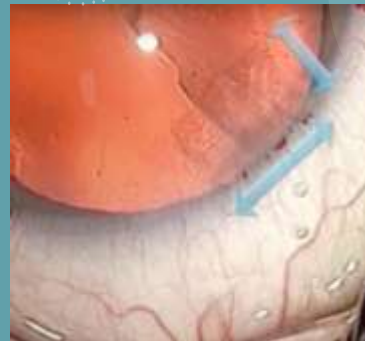Two paracentesis.

Surgeons prefer 2 paracentesis for the second hand instrument and for I/A ports.



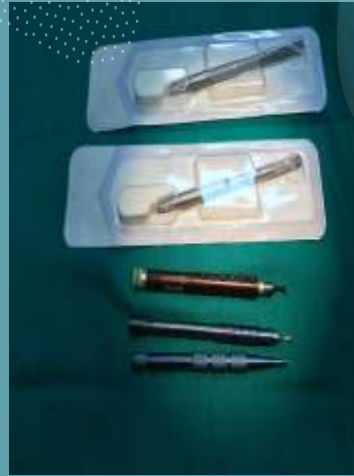The criteria of ideal phaco incision.

- Self sealing.
- Sutureless.
- Neutral (no astigmatism).



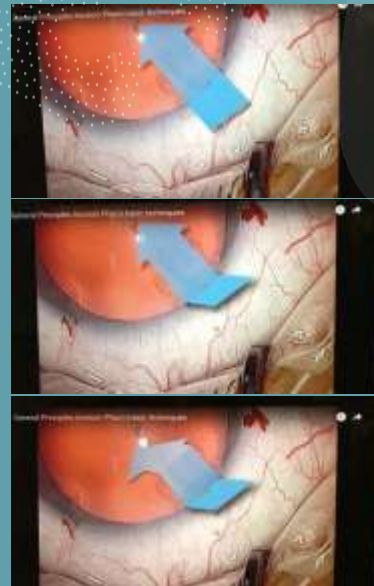
Incision Architecture (size)

- 1- width 3 mm or less (2.8 - 2.4mm)
- 2- length 1.5-2.0 mm
- 3- internal counter
- one plane (one step).
- Two planes (two steps).
- Three planes (three steps).

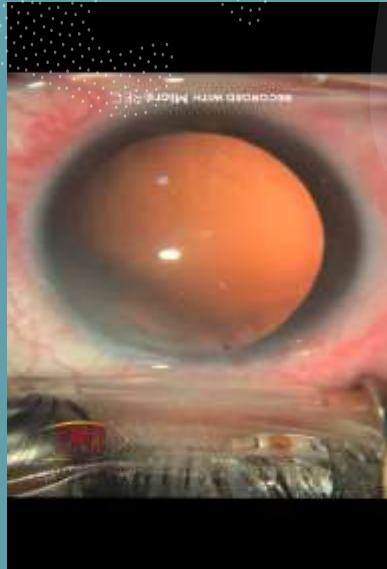


Architecture of the incision interior contour of the incision

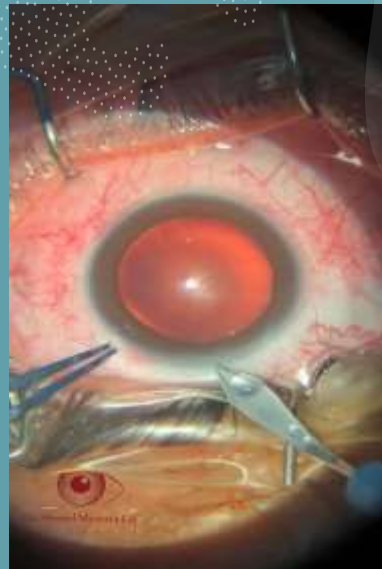-
- One plan
- Two plans
- Three plans



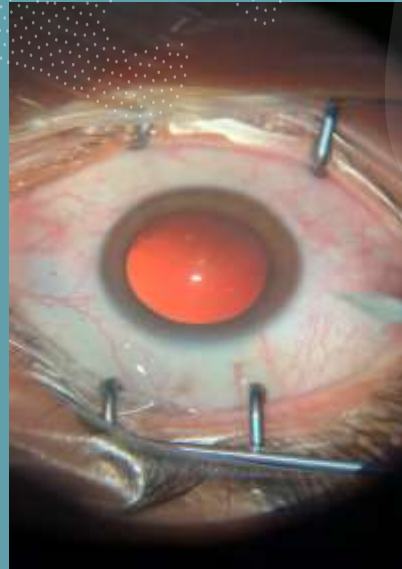One plan corneal incision



Two plans corneal incision



Three plans incision



Too tight phaco. incision

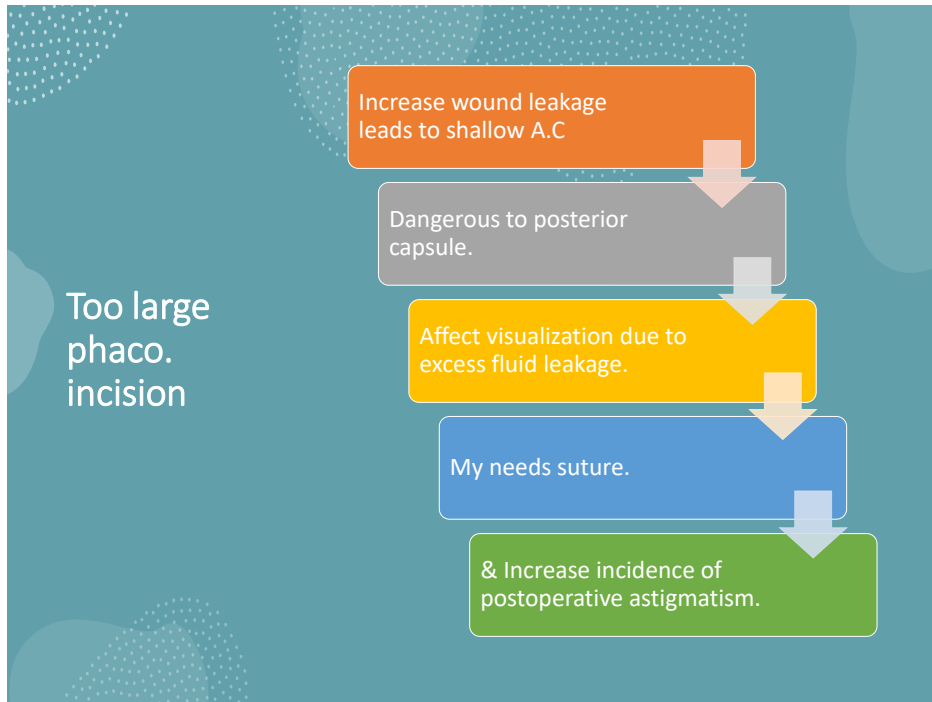
Collapse of the sleeve leading to decrease the irrigating fluid.

Increase the possibility of corneal burn.

Induce fish mouthing effect of the wound.

Increase the need of suture.

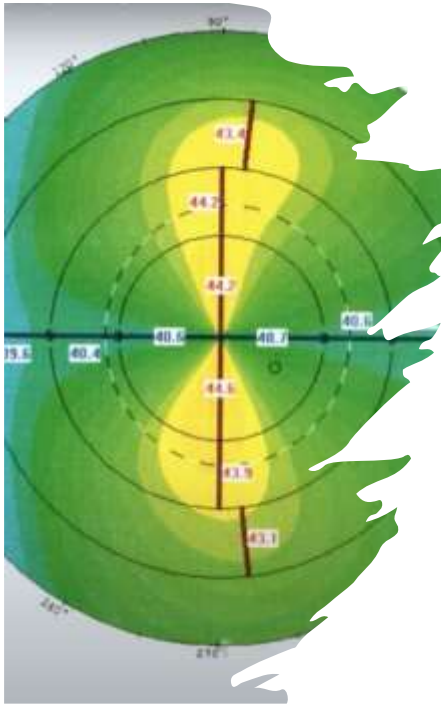
& leads to postoperative astigmatism.



Why Cataract surgery is the most common refractive surgery in ophthalmology ?

- -during surgery we can treat preoperative errors of refraction through
- -Incision site modification
- - LRI , CRL (femto laser or manual)
- - premium IOL to correct all degree of spherical error of refraction, astigmatism and presbyopia

A stylized blue eye icon is positioned to the right of the list of reasons.



Example: Comparative preoperative refractive astigmatism with the keratometry reading (K reading) will show if it is

Corneal , lenticular or combind causes

Corneal ----- modification of the incision

Combined ---- modification of the incision

Lenticular ----- Just remove the lense

Treatment Options for the astigmatism associated with cataract

- Placement of surgical incision at the steep meridian.
- Relaxing incision (CHI or LRI).
- Toric intraocular lenses.
- Combination of more than one option during surgery.
- 2nd-stage procedure with excimer laser ablation.

Advantages of temporal clear corneal incision

- Creates a self-sealing incision that does not usually require sutures.
- Offers better accessibility especially in sunken glob.
- Offers an excellent red reflex.
- Spares the superior conjunctiva for subsequent surgery.
- Avoid the need of a traction suture.

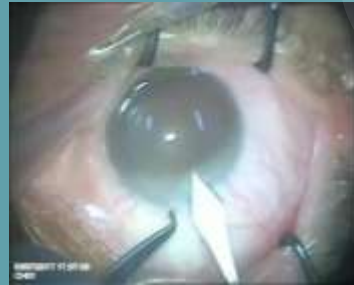Disadvantages of temporal clear corneal incision

- Need the surgeon to adapt to a different surgical position.
- Difficulty in converting to a manual expression ECCE technique.

Incision in different situations.

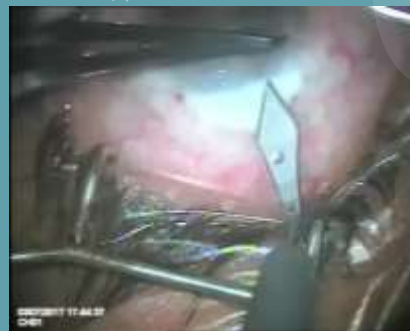Thin cornea ,irregular cornea and scared cornea.

Be ready with suture to manage the fish mouthing effect in this situation



Incision in different situations.

- Associated with glaucoma surgery



Important Points for ideal phaco incision

- preoperative investigation to show the corneal steep meridian (topography and pachymetry) .
- Use blades of good type with sharp tip and sides.
- Eye fixation is important during creating the incision.
- The incision 3mm width and at least 1.5 mm length in the clear cornea is ideal for make self-sealing, neutral and sutureless incision.
- Use suitable size phaco tips and sleeves to prevent fish-mouthing effect in tight incision or leaking in large incision

Sample Footer Text



Advanced Phaco. Course

Phacoemulsification in Traumatic subluxated cataract

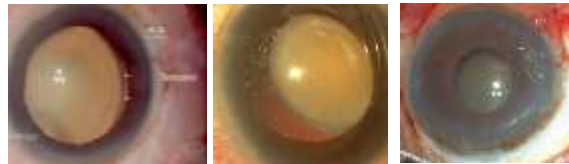
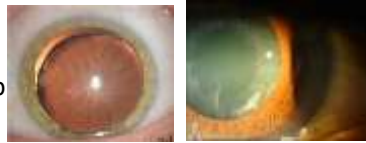
(video presentation)

Prof. Ahmed Mostafa Eid
Minia University
EOS - 2023

6/1/2023

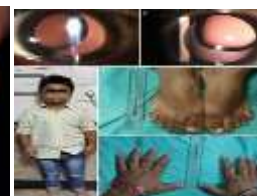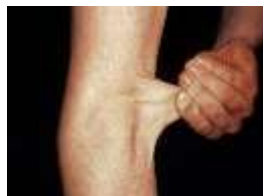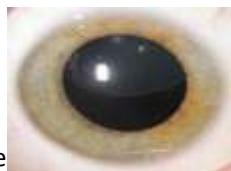Common causes of subluxated cataractus lens

- **Ocular trauma**
- Pseudoexfoliation syndrome
- Large eye (High degree of myopia, b
- Hypermature cataract



inherited causes of subluxated lens

- Marfan syndrom
- Ehlers-Danlos syndrome
- Homocystinuria
- Hyperlysinemia
- Weill-Marchesani syndrome
- Aniridia
- Familial ectopia lentis



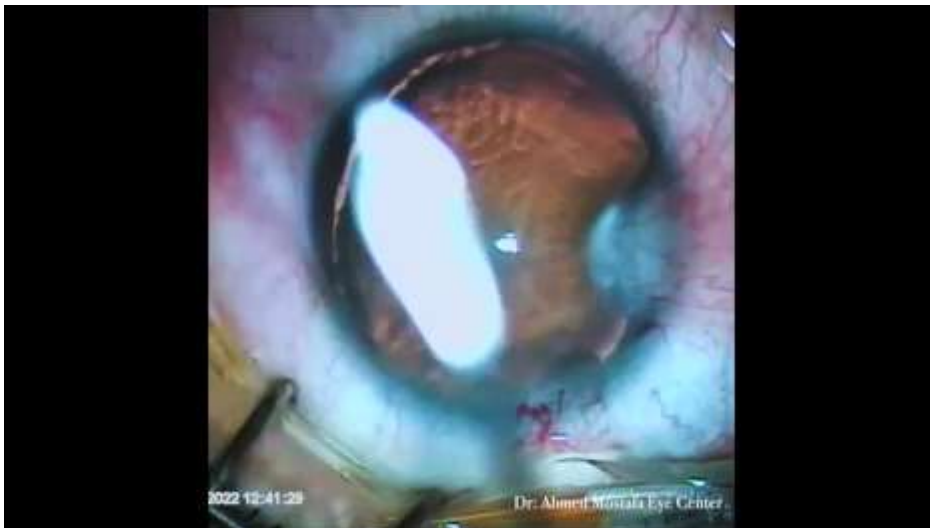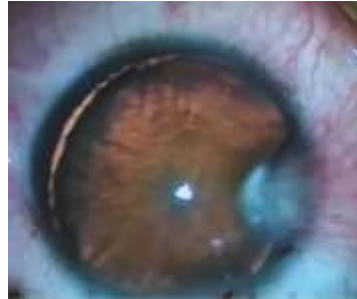50-year-old male work as farmer with history of old trauma since many years presented by subluxated cataract in his Lt eye

Ophthalmic examination show

Clear corneal centra with large nasal pterygium under midriasis there is subluxation of cataractus lens 2-6 clock (4 hours)

Cortecal and posterior subcapsular cat.

in supine position the anterior chamber normal and the iris and lens stabile ,normal iop, normal funds ,V/A 2/60



Important points during management of traumatic subluxated cat.

1- Good evaluation of the degree of subluxation and choose suitable procedure

2- Suitable devices you may use during the procedure

3- Suitable IOL in this situation

Evaluation of subluxation and suitable procedure

Up to 4 clock hours

- 1st choice: CTR with IOL implantation
- 2nd choice: IOL implantation with haptic being used to stretch the bag

4 to 6 clock hours Modified CTR with single loop with IOL implantation


More than 6 to > 9 clock hours Modified CT with double loop with IOL implantation

9 or more clock hours

- Intracapsular cataract extraction with post. ch. IOL scleral fixated with sutures or Yamman technique, Iris fixated IOL (ant. Or post.) or anterior chamber IOL

Suitable devices you may use during the procedure

- CAPSULAR TENSION RINGS (CTR) and its modifications
- - Cionni CTR
- - Ahmed segment CTR
- - different types of capsular



Suitable IOL in this situation



Prof : Ahmed Mostafa Eid MD.
Minya University

+201144664400

Ahmedmostafa1966@mu.edu.eg

Minya -Minya university eye hospital

Minya - Bani mazar -port said street

Minya - saad Zaghloul - safway tower



THANK YOU!

dreamstime.