

Posterior Capsular Rent

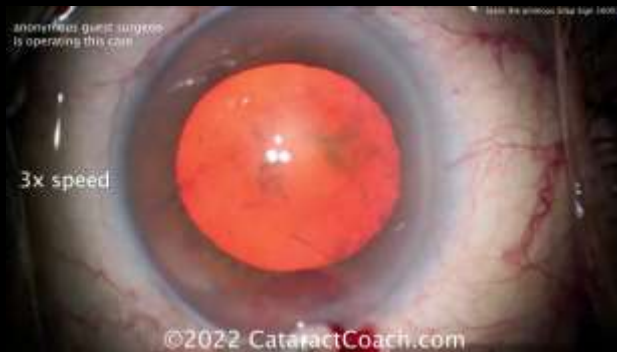Dr Mohamed Anbar

Assistant Professor Of ophthalmology
Sohag University

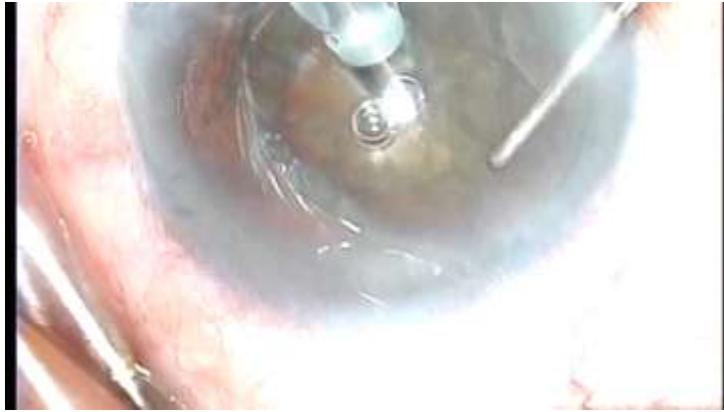I have Nothing To Disclos



Very Early PCR



Pupil Snap Sign



Posterior Assisted Levitation- PAL



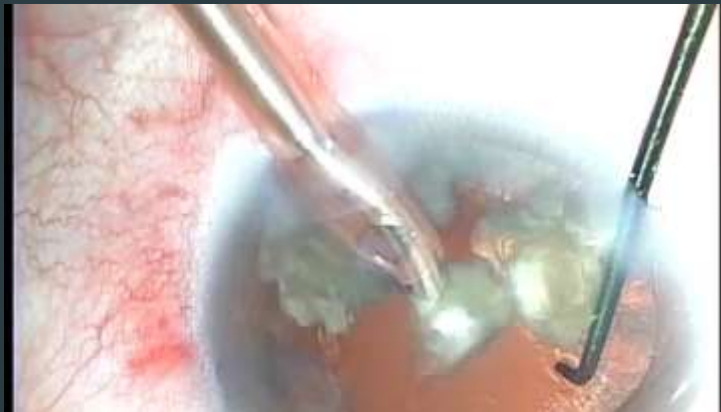Early signs Of PCR

Pupil snap sign- sudden marked pupil constriction after hydrodissection

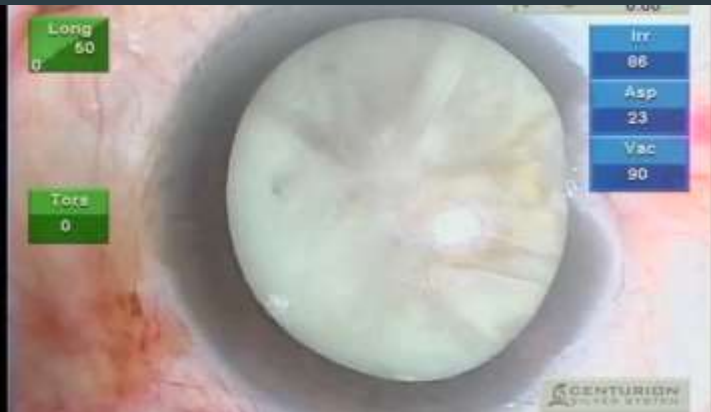Sudden deepening of the chamber with momentary expansion of the pupil

Apparent inability to rotate a previously mobile nucleus

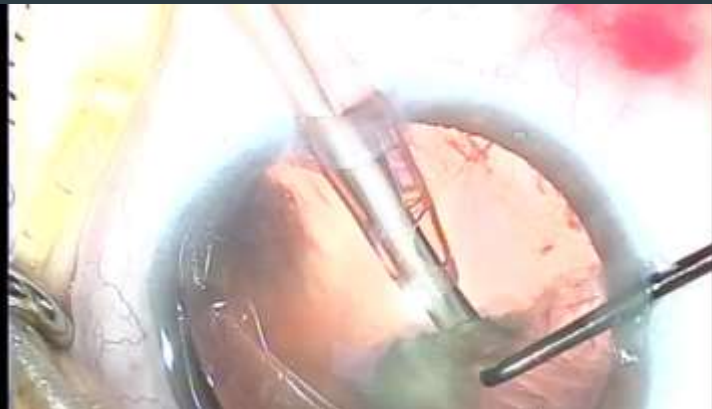IOL Scaffold & Posterior Rhexis



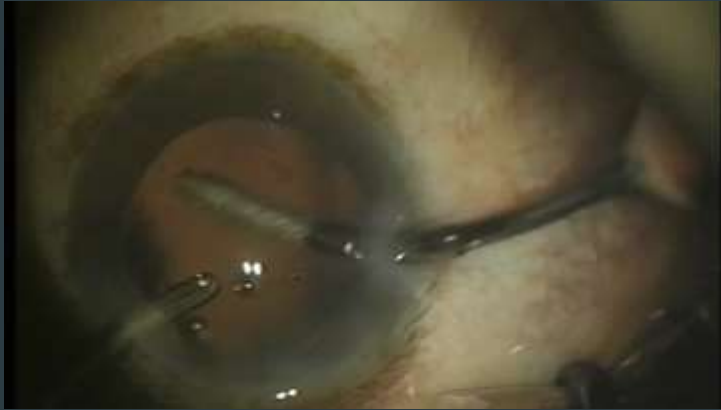Vitreous IN AC



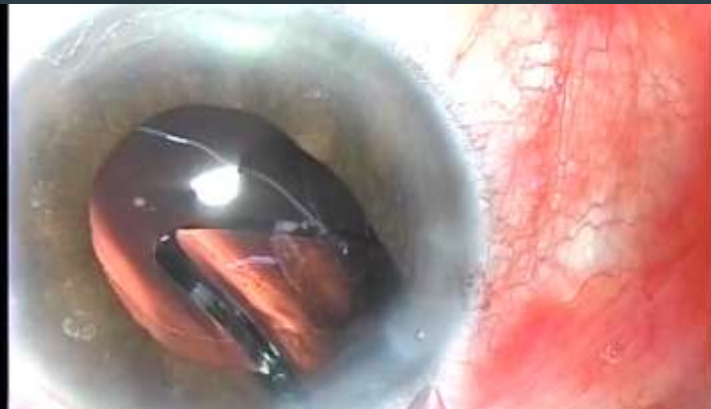
No Vitreous IN AC



PCR with I/A



PCR After Implantation



To Summarize

Remember Your Weapons

Dispersive OVD...Viscoat

PAL

IOL Scaffold

Posterior rhexis

Triamcinolone

3 piece IOL

Michol

PCR with Presence Of nuclear Material

Reduce Phaco Parameters

Lowest flow rate possible that will not aspirate dispersive OVD is **12ml/min**

Avoidance of occlusion break surge we should use moderate vacuum / **200mmgh**

Flow rate in case of aspirating cortex should be low as possible to **5ml/min**

Anterior Vitrectomy Parameters

A 23 gauge would require

Bottle height of 75 cm

Vacuum of 150–200 mmHg

Flow rate 10–15 cc/min

Cut rate the highest allowed

Never Fishing

Never anterior vitrectomy through
the main wound

Thank You

Small Pupil Management

Dr. Mohamed Anbar MD

*Assistant Professor Of Ophthalmology
Sohag University*

I Have Nothing To Disclose

Causes Of small pupil

Aging.. Iris sphincter sclerosis
Diabetes
Pseudoexfoliation
Iris floppy syndrome..IFIS
Chronic uveitis
Chronic Miotics therapy

IFIS

Triad

Progressive **constriction** of the pupil during surgery
Fluttering and **billowing** of the flaccid iris stroma
Iris **prolapse** to the corneal incision

Causative Agents Of IFIS

Sympathetic Alpha 1 antagonist agents

Selective e.g. Tamsulosin or Silodostin.....Benign Prostatic hyperplasia

Nonselective e.g. Doxazosin or Alfuzosin

IFIS may be partial or complete

Male and females may be affected

Risks Relate to Small Pupil In Cataract Surgery

Iris injury...iris burn

Posterior capsule rupture

Vitreous Loss

Endothelial damage

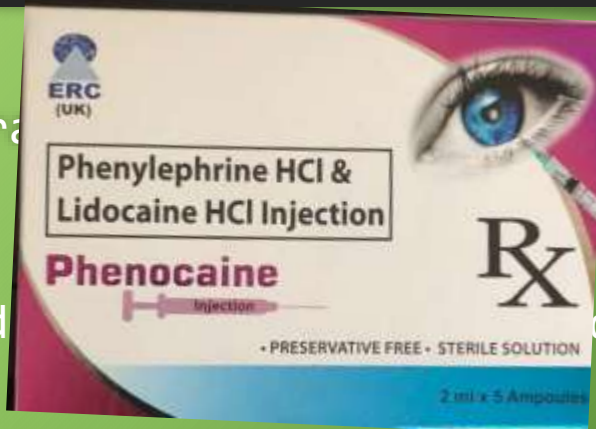Later..... capsule phimosis

Management Of Intraoperative Small Pupil

Intracameral Mydriatics

Intracameral

Adding lidocaine
effect of

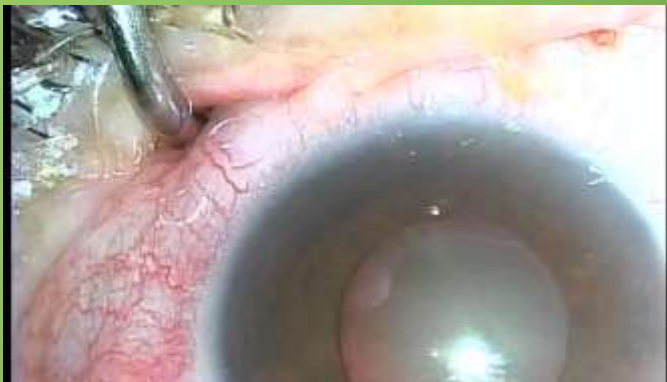

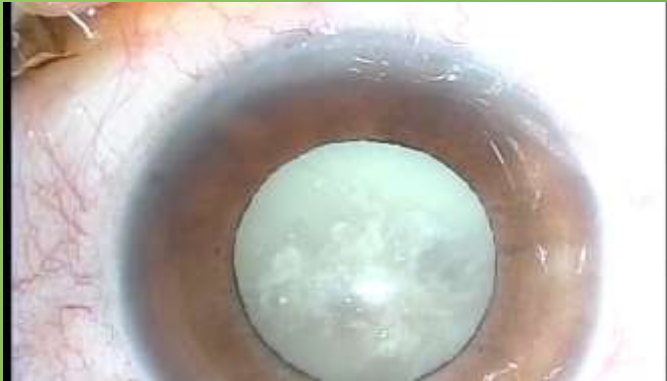phenylephrine

mydriatic

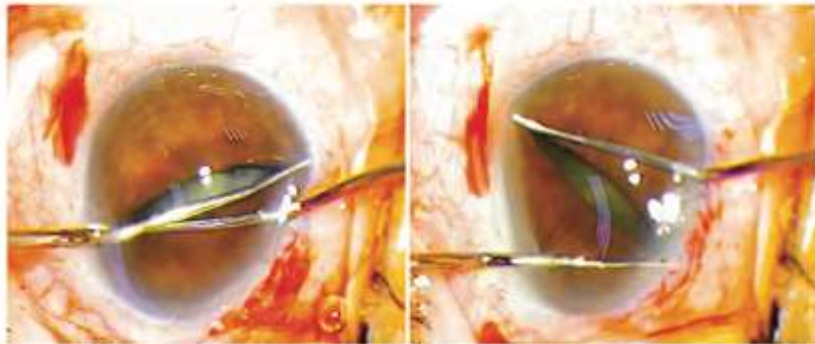
Viscoadaptive Agents

Further mydriasis can be achieved by injection of **cohesive**, high molecular weight ophthalmic viscoelastic devices (OVD)





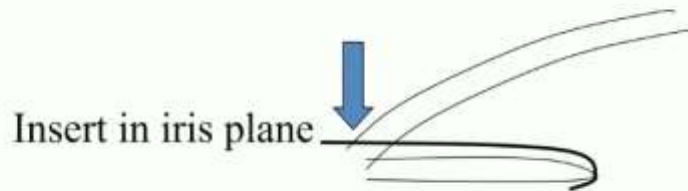
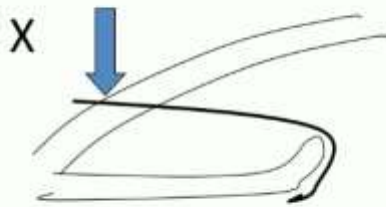
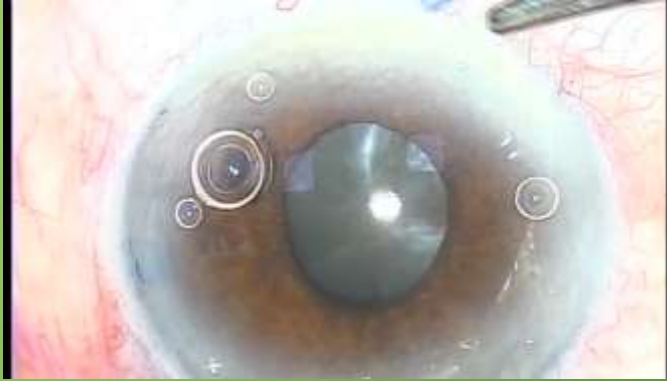Pupil Stretching



Small pupil and cataract surgery

Hassan Heshem^{1,2}, Mohammad A. Seyedian³, and
Mehrdad Mohammadpour³


Iris Hooks



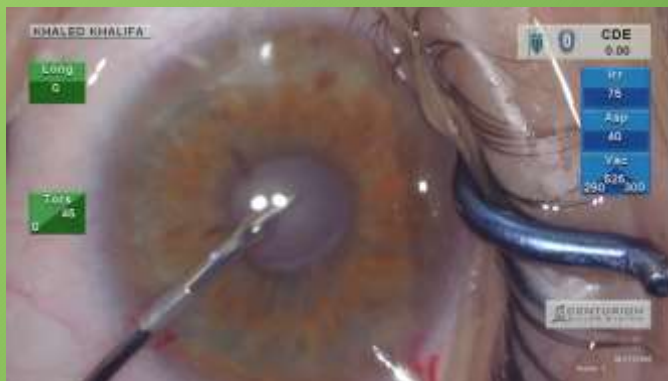Pupil Expanders

Table 1. An overview of pupil expansion devices

Device	Producer	Additional information	Movie
Bhattacharjee pupil expansion ring	Madhu Instruments	Single-use, requires straight 23-G serrated forceps for insertion; options: square or hexagonal	N/A
Bhattacharjee pupil expansion ring (3rd generation)	Med Invent Devices	Single-use, requires straight 23-G serrated forceps for insertion	https://youtu.be/6XGgrIXhM40
Xpand NT	Diamatrix LTD	Pupil diameter 6.7 mm, incision width 2.5 mm	https://youtu.be/cpbw5TEsSAI
Malyugin Ring	MicroSurgical Technology	Single-use, introduced through a 2.2 mm incision with a dedicated injector	https://youtu.be/2K0fsuZWktA
Malyugin Ring 2.0	MicroSurgical Technology	Single-use, introduced through a 2.0 mm incision with a dedicated injector, available in 6.25 mm and 7.0 mm sizes	https://youtu.be/ABOd4cgYp5E
I-Ring pupil expander	Beaver-Vistec International	Single-use, preloaded	https://youtu.be/zzfGlx9AJk0
Assia Pupil Expander (APX) 200	APX Ophthalmology Ltd.	Single-use, does not require an injector	https://youtu.be/3OvxcjqRZQ
OASIS Iris Expander	Oasis Medical Inc.	Single-use, packaged with easily loaded disposable injector, 6.25 or 7.0 mm version	https://youtu.be/G9GFjxTZZ4w
Groether 2000 Pupil Expander	Katena Products, Inc., NJ, USA	Single-use preloaded instrument, also pack includes an iris glide-retractor	https://youtu.be/9co0HOP3M
Marcher pupil dilator MR-55	FCI Ophthalmics, MA, USA	Single-use, may be injected manually or with the Geuder pupil dilator injector	https://youtu.be/hjxAZkNo-7w
Perfect pupil device	Mivella limited	Single-use, engaged manually or with an injector	https://youtu.be/TCj8bAl2QTQ
Canabrava ring	AJL Ophthalmic S.A., Spain	Single-use, inserted with McPherson forceps	https://youtu.be/M8oHjg-JX8g



Malyugin Ring



Iris hooks Vs Malyugin Ring

Iris hook cases have additional operating time 14 minutes for consultants and 24 minutes for trainees

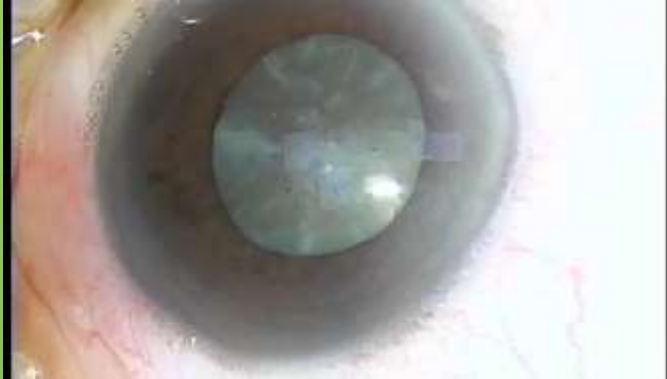Malyugin ring cases have additional operating time 4 minutes for consultants and 6 minutes for trainees

**Iris hooks versus a pupil expansion ring:
Operating times, complications, and
visual acuity outcomes in small pupil cases**

Paul Nderitu, MB ChB, MPhil, Paul Ursell, MB BS, MEd, FRCCOphth

The proportion of patients with anterior uveitis and corneal edema was significantly higher in the Malyugin ring

Multiple Sphincterotomies



Multiple Sphincterotomies



Take Home Massage

Intracameral Mydriatics

Use a block rather than topical

Difficult cases... Hooks or Rings

Soft shell technique

Modify your technique....Low
parameters and central phaco

Avoid touching the iris

Thank
You