

Desparate Times, Desparate Measures. Corneal Patch Grafts

Mouamen M Seleet
Assoc. Prof. ASU

EOS 1902

Indications

- Infections
- Immunological diseases and ocular surface diseases
- Mitomycin
- Exposed shunts ?
- Trauma

EOS 1902

Mitomycin after Pterygium excision

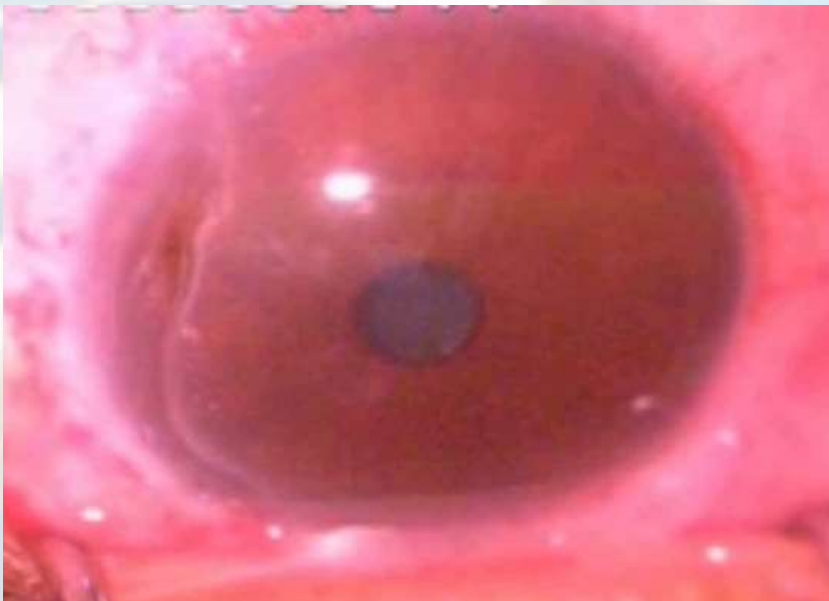- Antineoplastic antibiotic isolated from *streptomyces caseipitosus*
- Inhibits the synthesis of DNA by attaching to it.

USE: (law of 2)

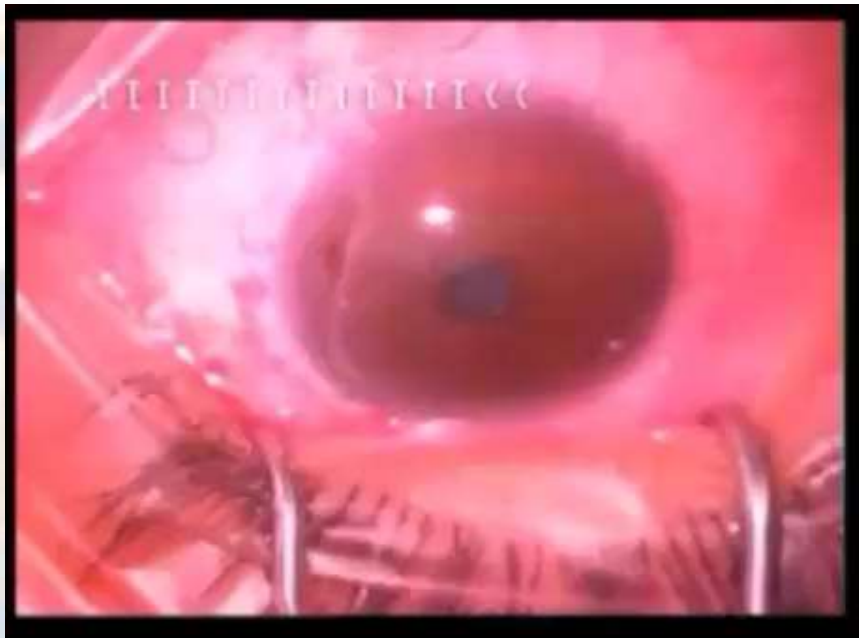
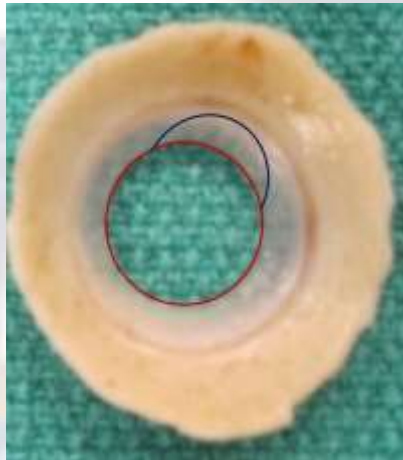
Application during the surgery 0.2% for 2 minutes

After the surgery as drops 0.02% twice daily for 2 weeks

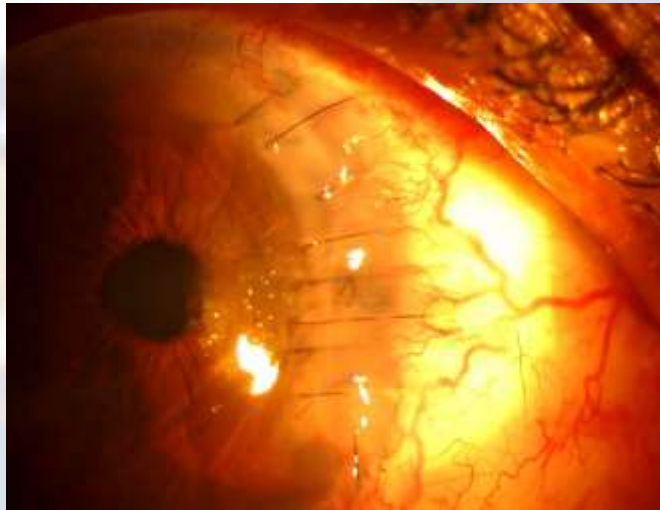EOS 1902



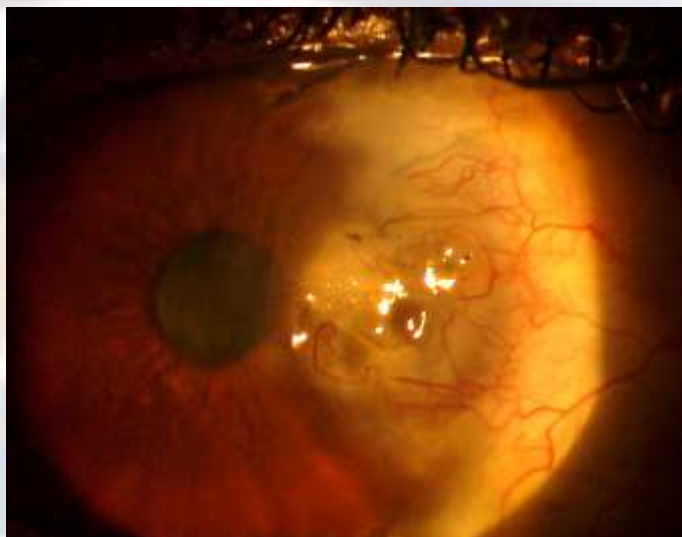
Patch graft harvesting



2 months later



1 year later



Interface Lamellar Keratitis (ILK)

- Fungal (mostly Candida) 1.4 per 10000
- Bacterial (mostly Staphylococcus)
- Acanthamoeba

EOS 1902

Post DALK nightmare

Fungal ILK

Literature Rate: 1.4 per 10000

My rate: 3 cases in the past year

EOS 1902

Prevention?

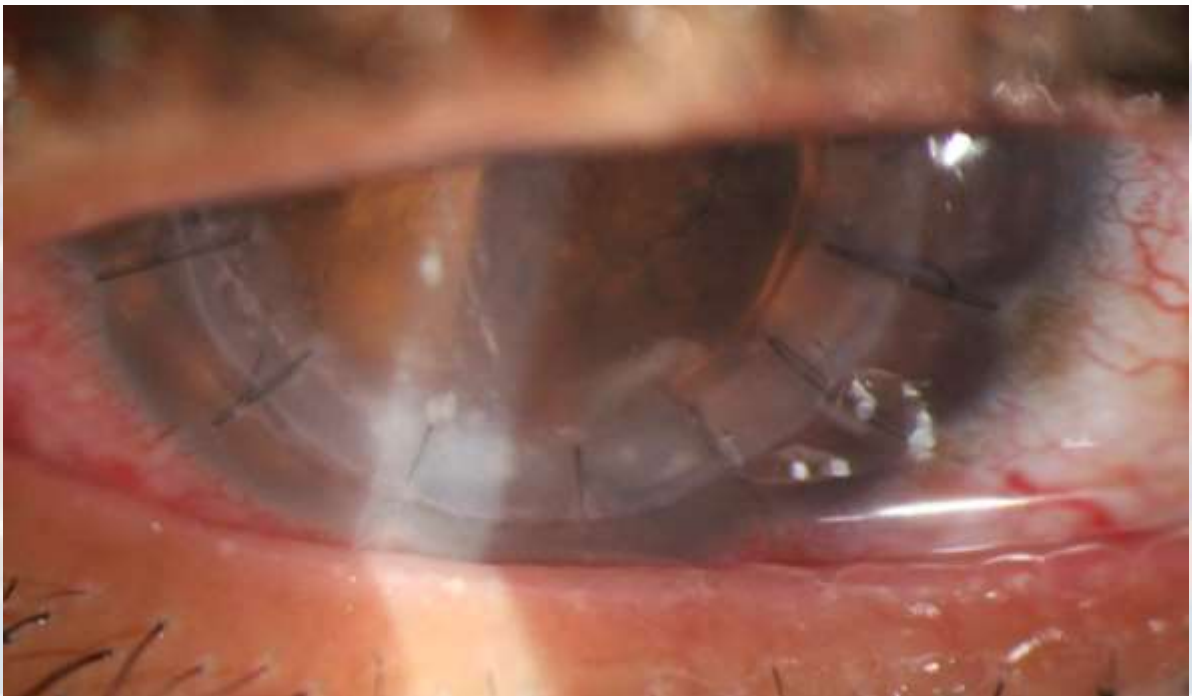
Graft Irrigation with antifungals?

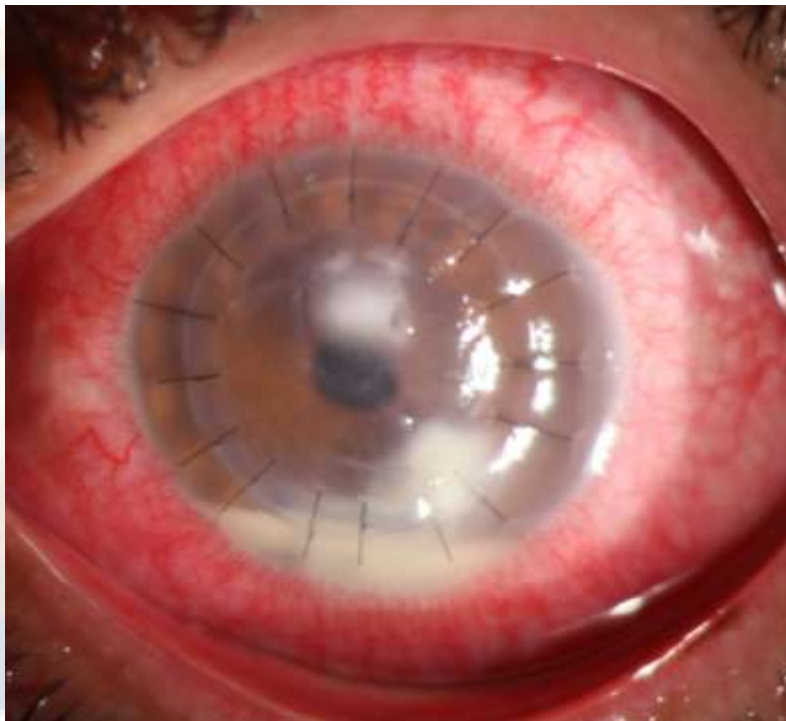
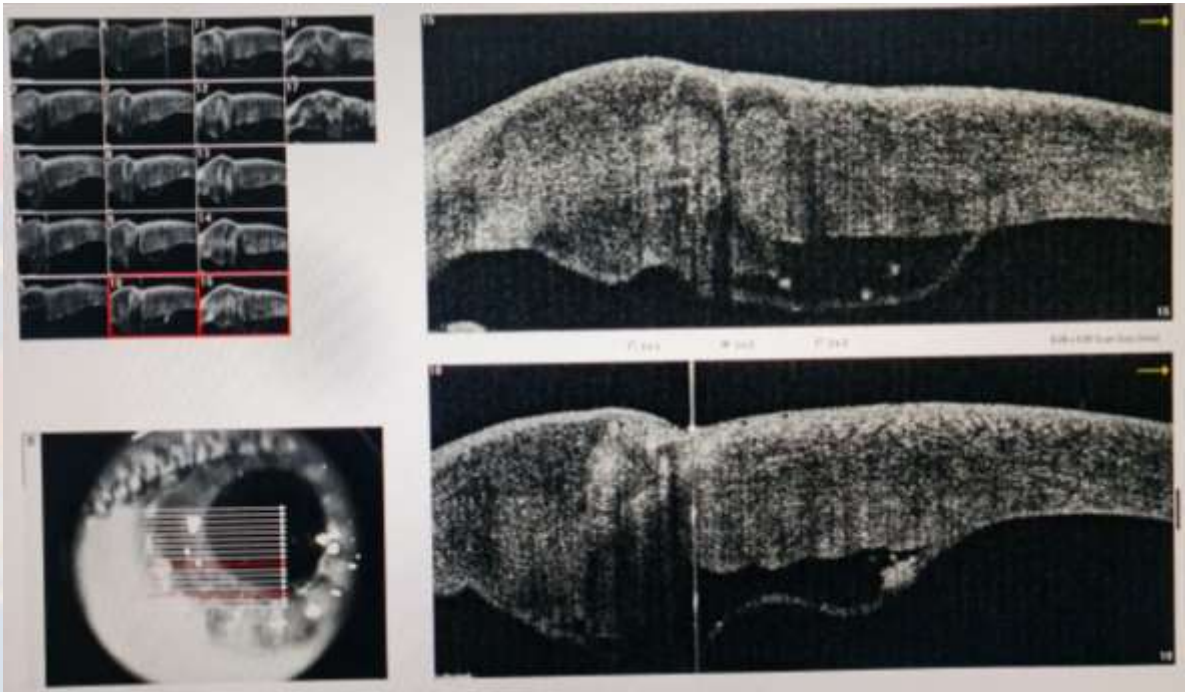
Amphoterecin B 5ug/0.1ml

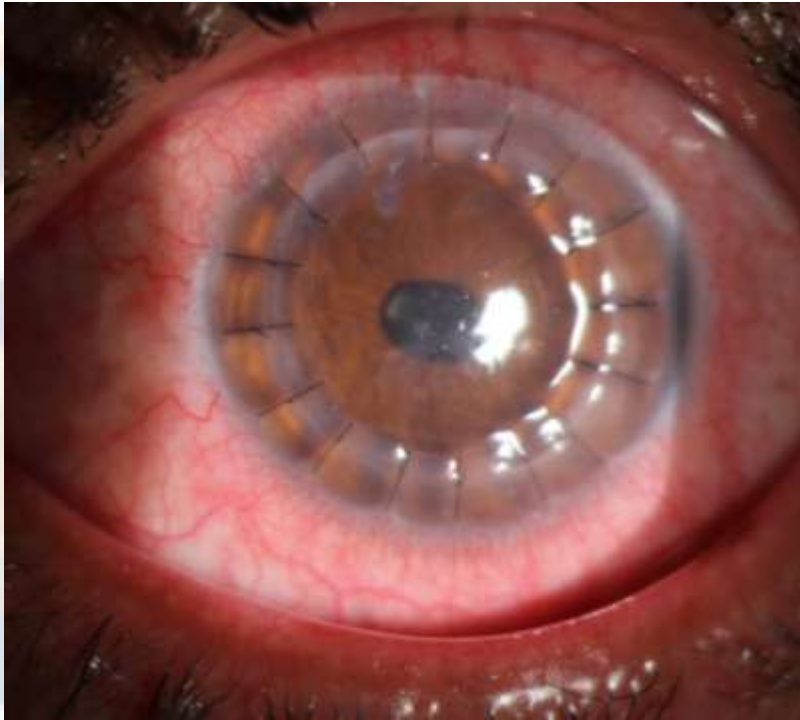
Fluconazole

Voriconzole 0.25mg/ml

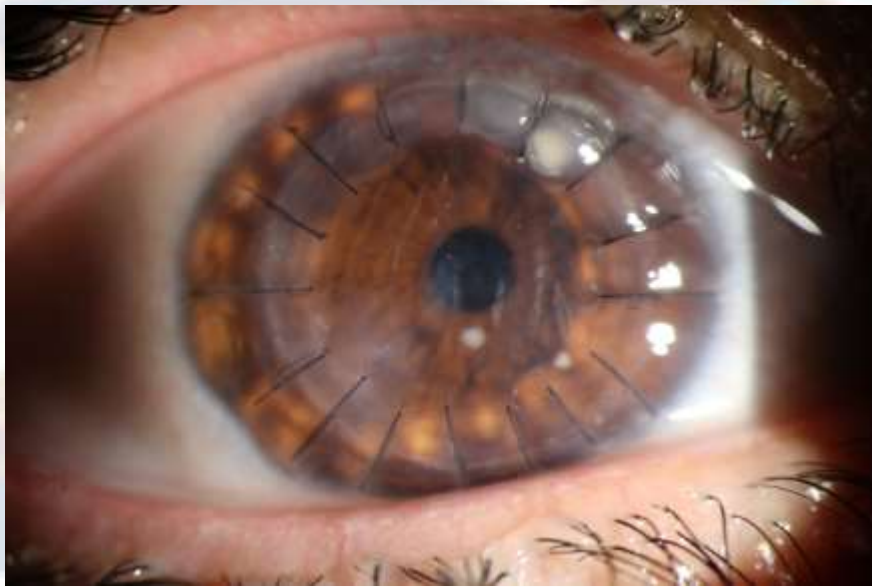
EOS 1902



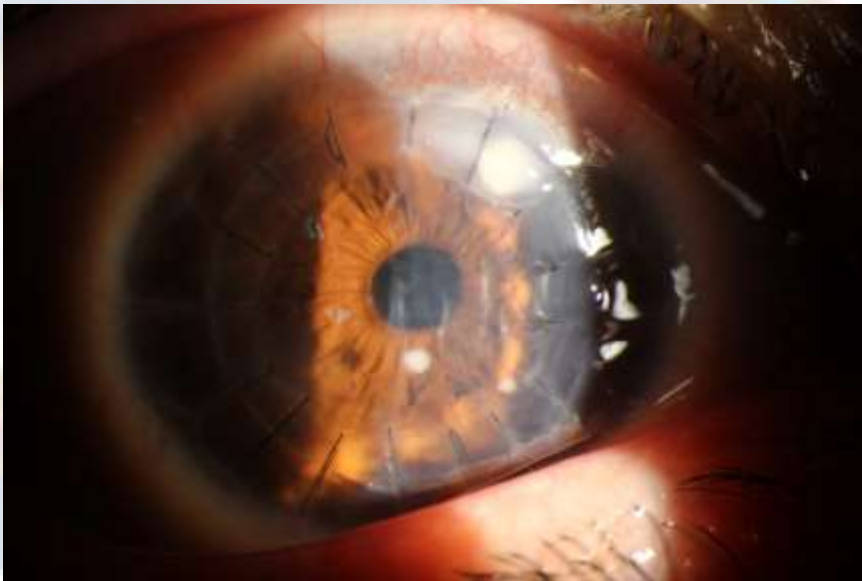




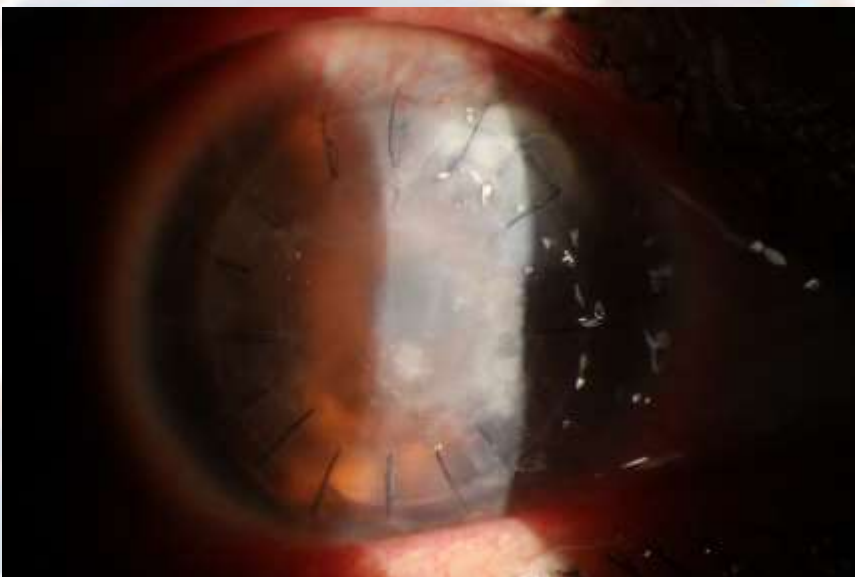35 year old female
2 weeks post DALK



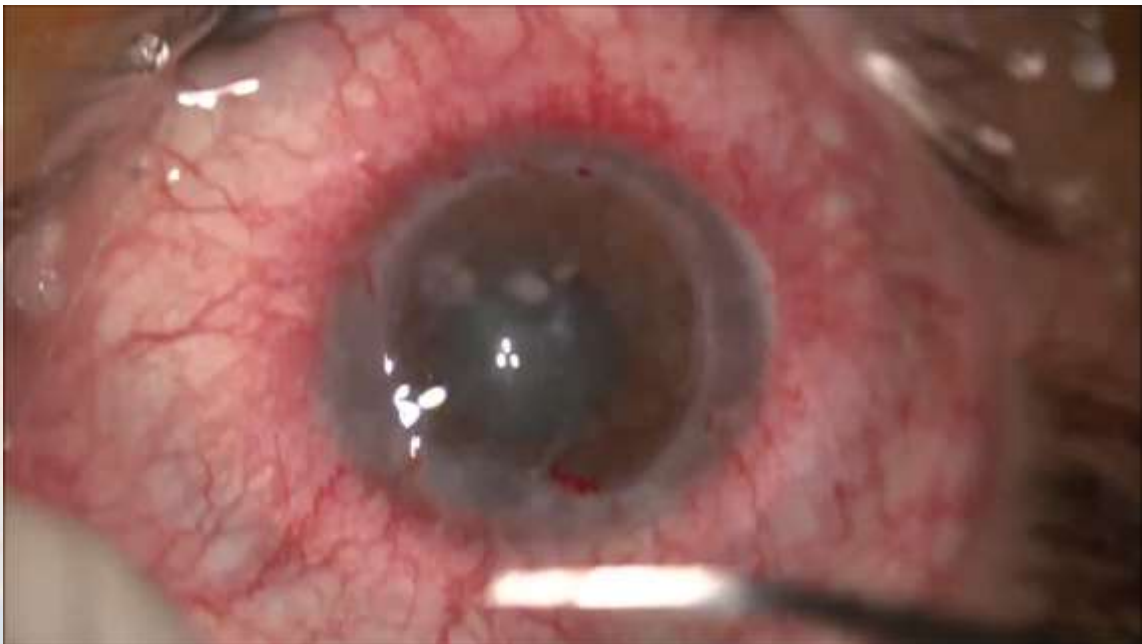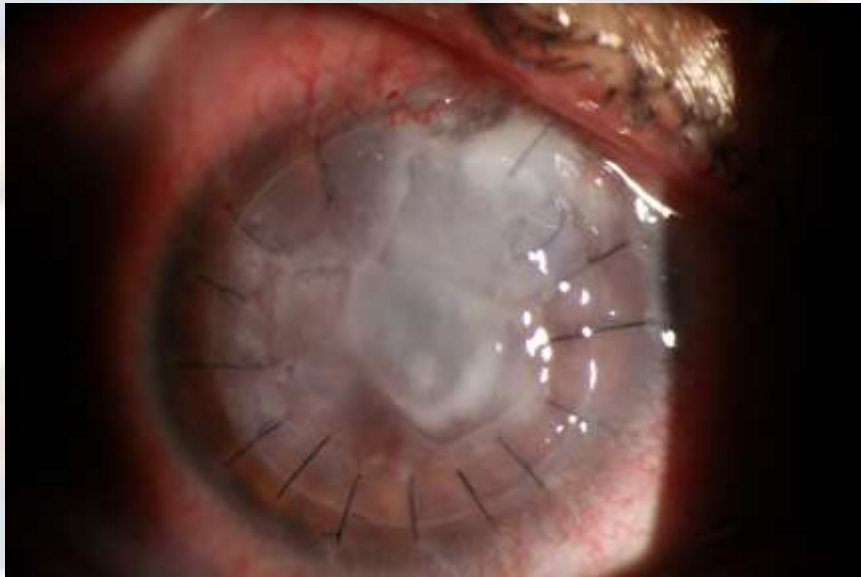2 weeks later



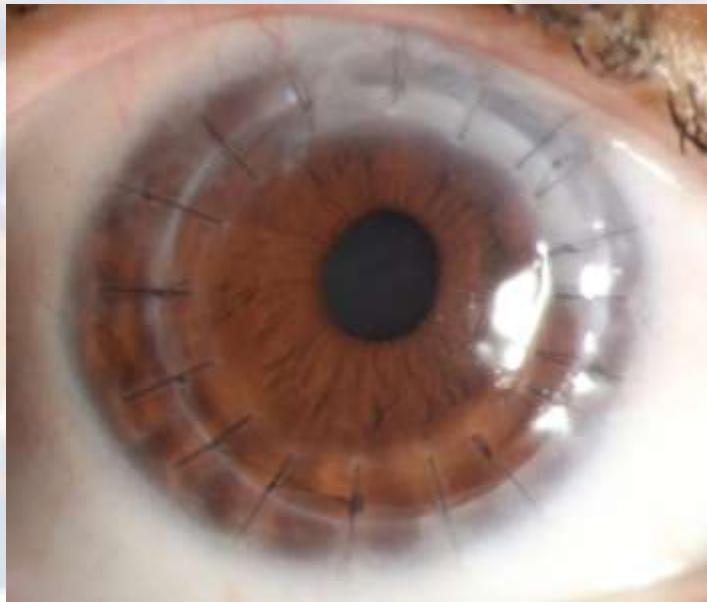4 weeks after interface wash and injection

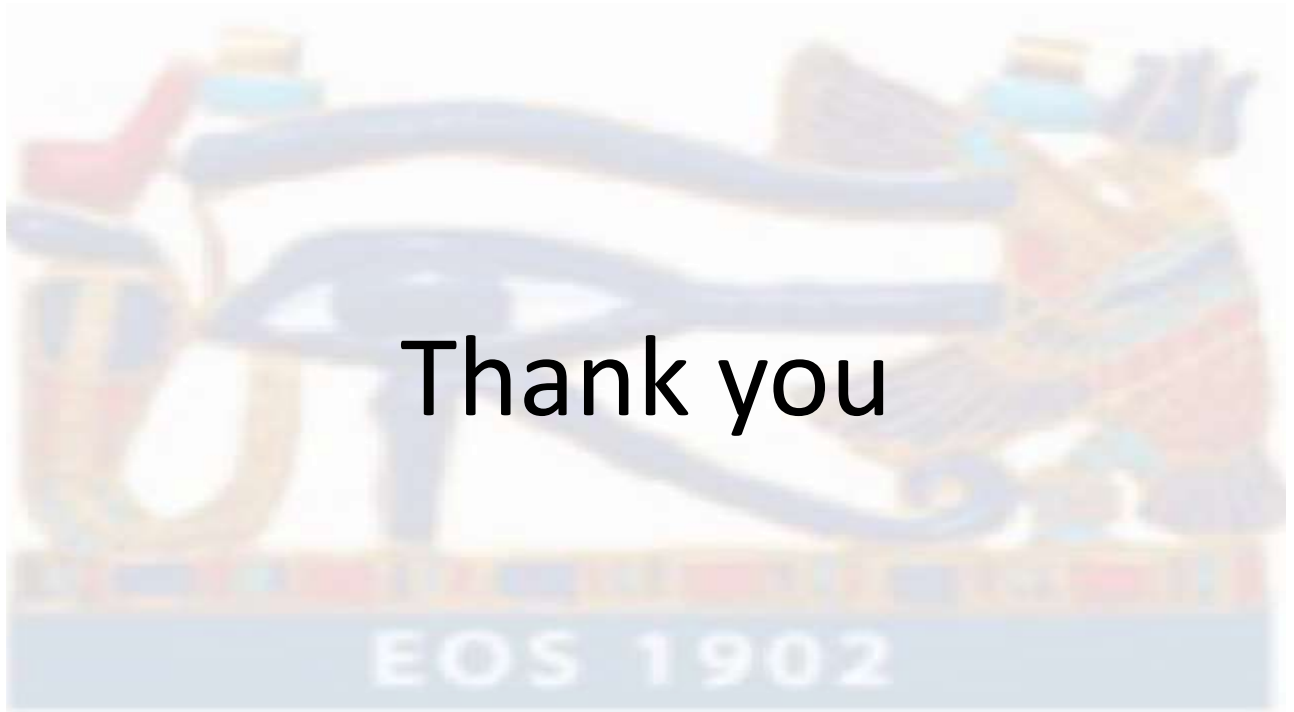

6 weeks after wash



3 months after PKP





Thank you