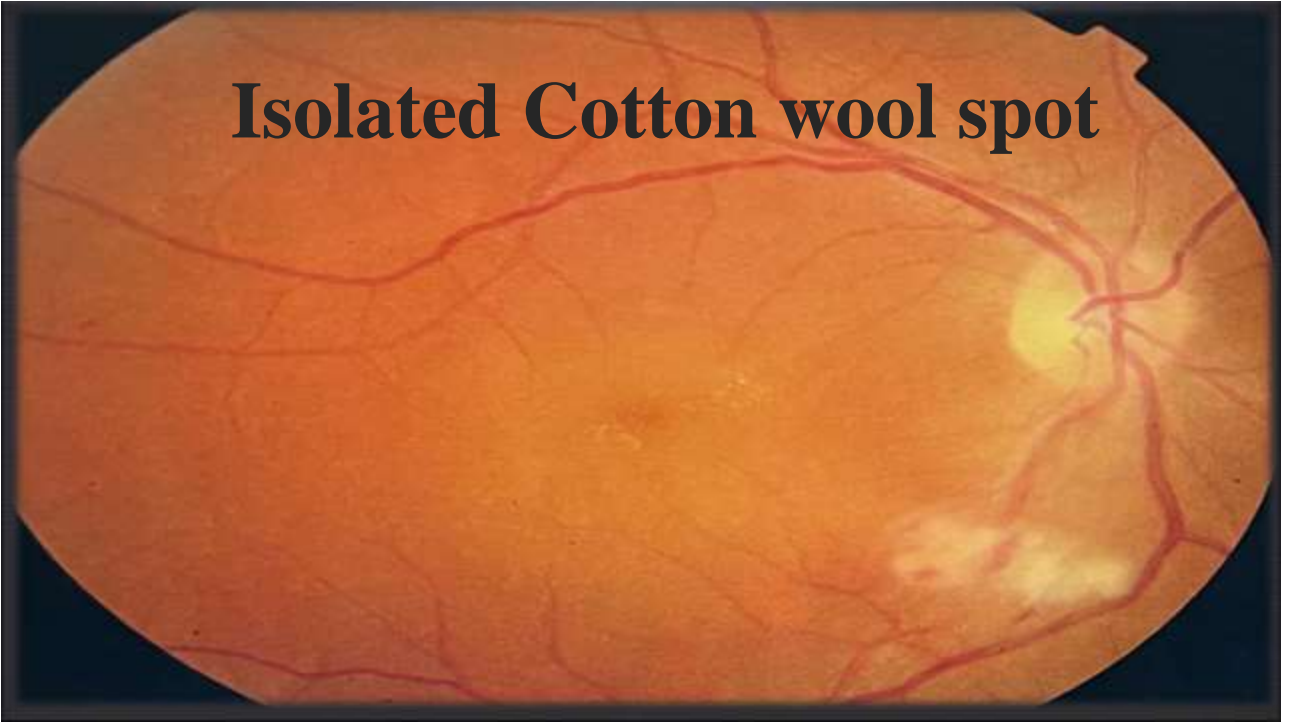

# *Something is leaky ...*

Abdussalam Abdullatif, MD  
Associate Professor  
Cairo University

- 40 yrs old female patient coming complaining of blurred vision in right eye.
- No diabetes or HTN
- Negative past medical and ocular history.

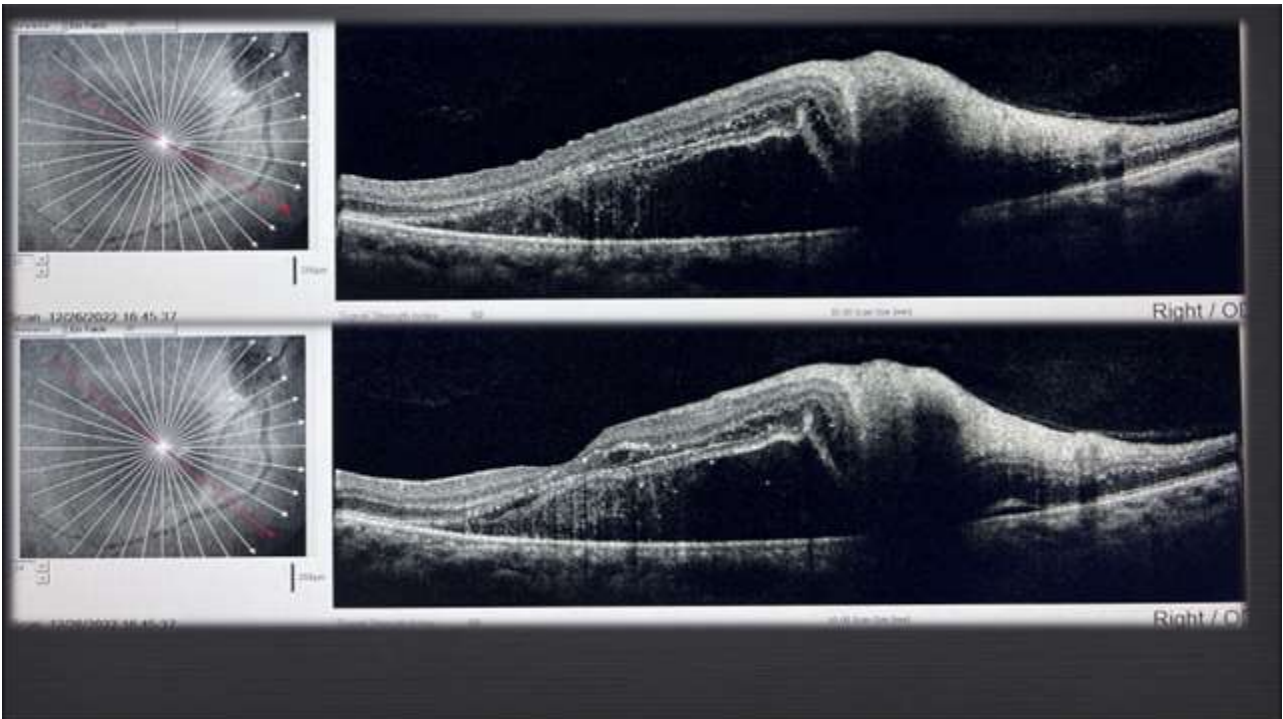
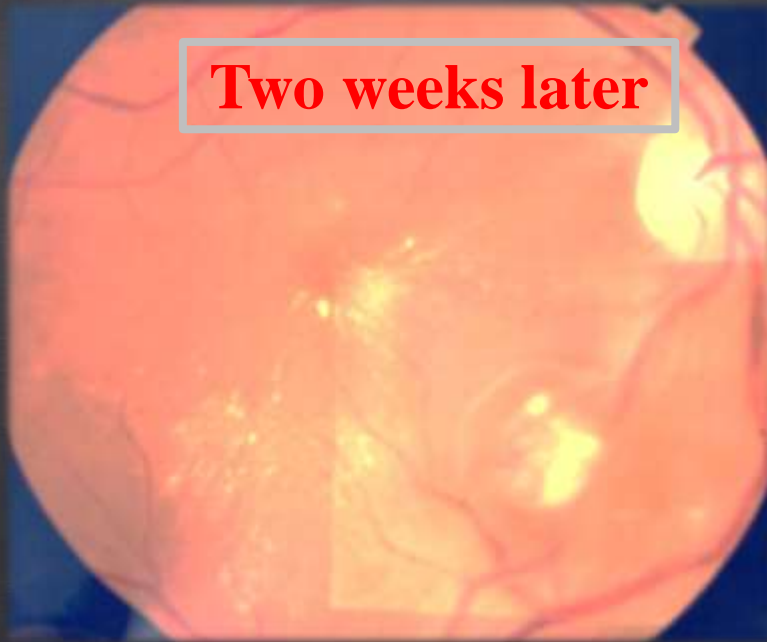
## Isolated Cotton wool spot



## Cotton wool spots

- Ischemic
- Embolic
- Connective tissue
- Neoplastic
- Infectious

Two weeks later

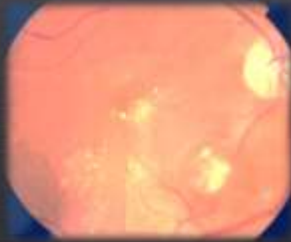


# Exudation

Look for

**Mass**

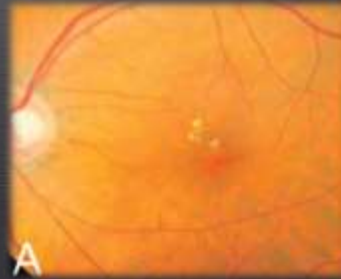**Telangiectasia**



# Exudation

**Telangiectasia**

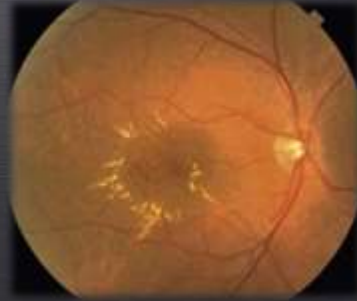-Perifoveal exudative vascular  
anomalous complex



# Exudation

## Telangiectasia

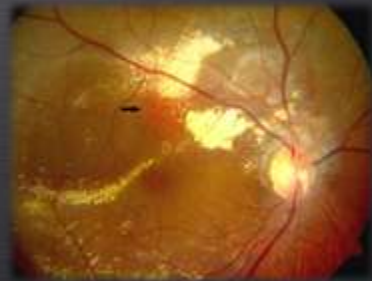
- Perifoveal exudative vascular anomalous complex
- MacTel type 1



# Exudation

## Telangiectasia

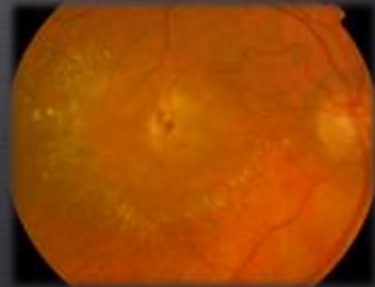
- Perifoveal exudative vascular anomalous complex
- MacTel type 1
- PCV



# Exudation

## Telangiectasia

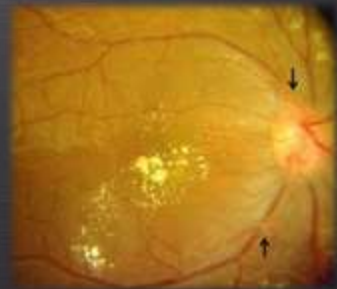- Perifoveal exudative vascular anomalous complex
- MacTel type 1
- PCV
- RAP

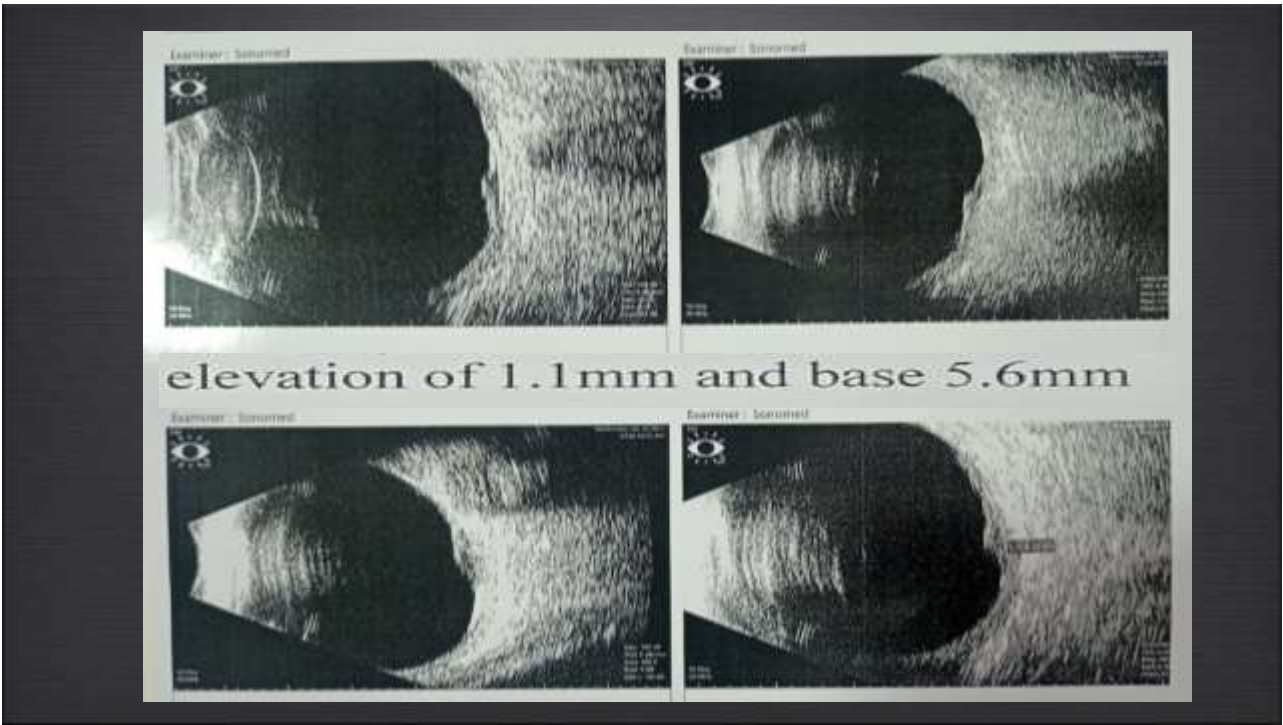
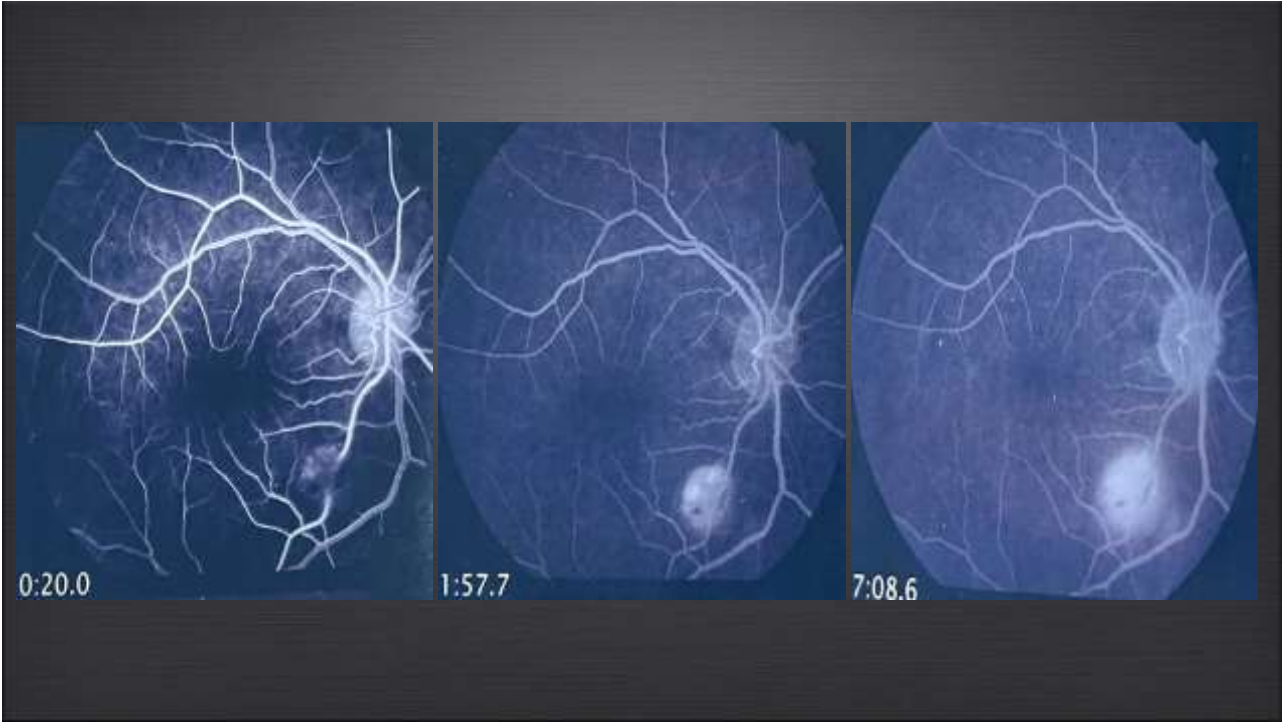


# Exudation

## Telangiectasia

- Perifoveal exudative vascular anomalous complex
- MacTel type 1
- PCV
- RAP
- IRVAN





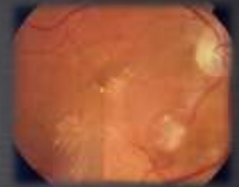# Exudation

+

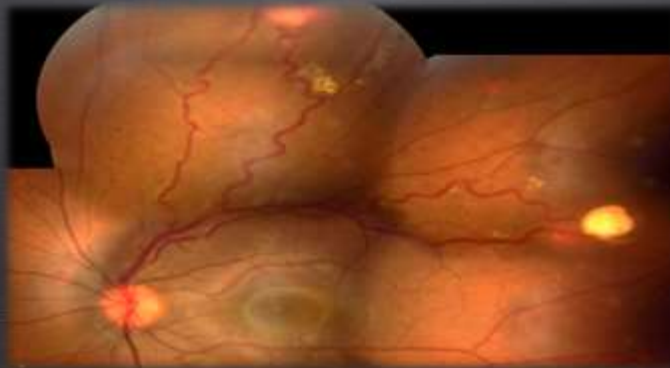
Mass

# Exudation

Mass



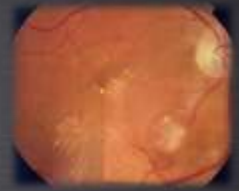Capillary hemangioma: Orange mass + feeder vs





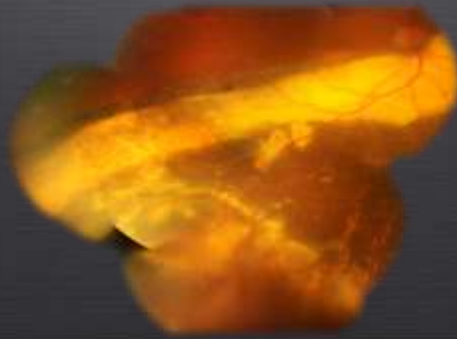
# Exudation

**Mass**



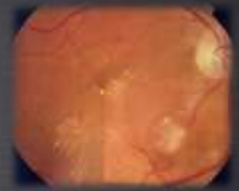**Capillary hemangioma: Orange mass + feeder vs**

**Vasoproliferative proliferation: Yellowish Pink mass + NO feeder vs**



# Exudation

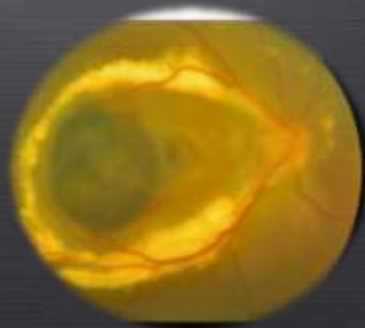
**Mass**



**Capillary hemangioma: Orange mass + feeder vs**

**Vasoproliferative proliferation: Yellowish Pink mass + NO feeder vs**

**RPE adenoma: Black mass**



# Exudation

## Mass

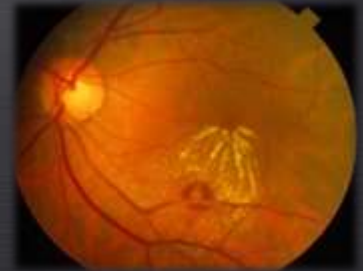

**Capillary hemangioma: Orange mass + feeder vs**

**Vasoproliferative proliferation: Yellowish Pink mass + NO feeder vs**

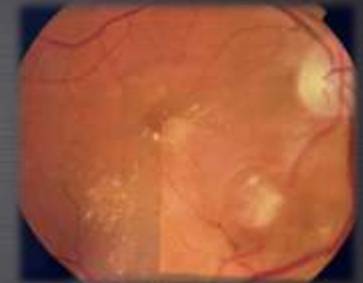
**RPE adenoma: Black mass**

**Retinal Arterial Macroaneurysm:  
Mass along artery**



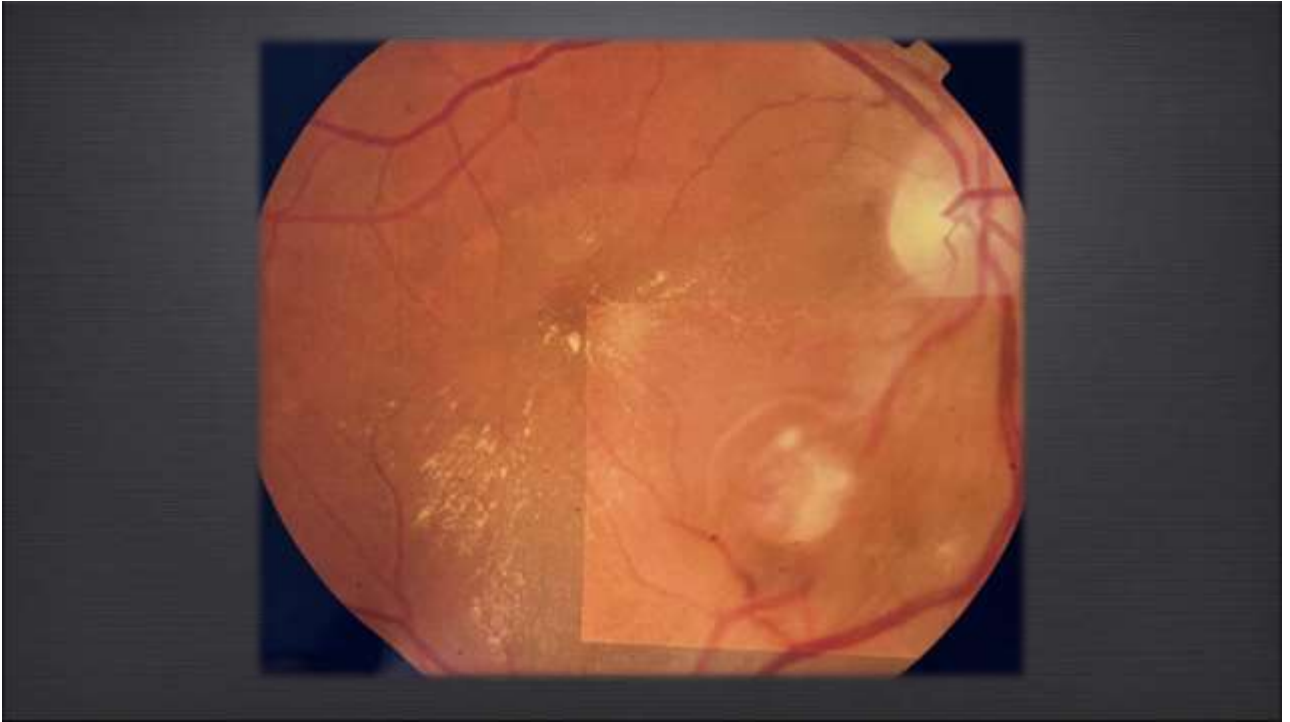
# Exudation

## Mass

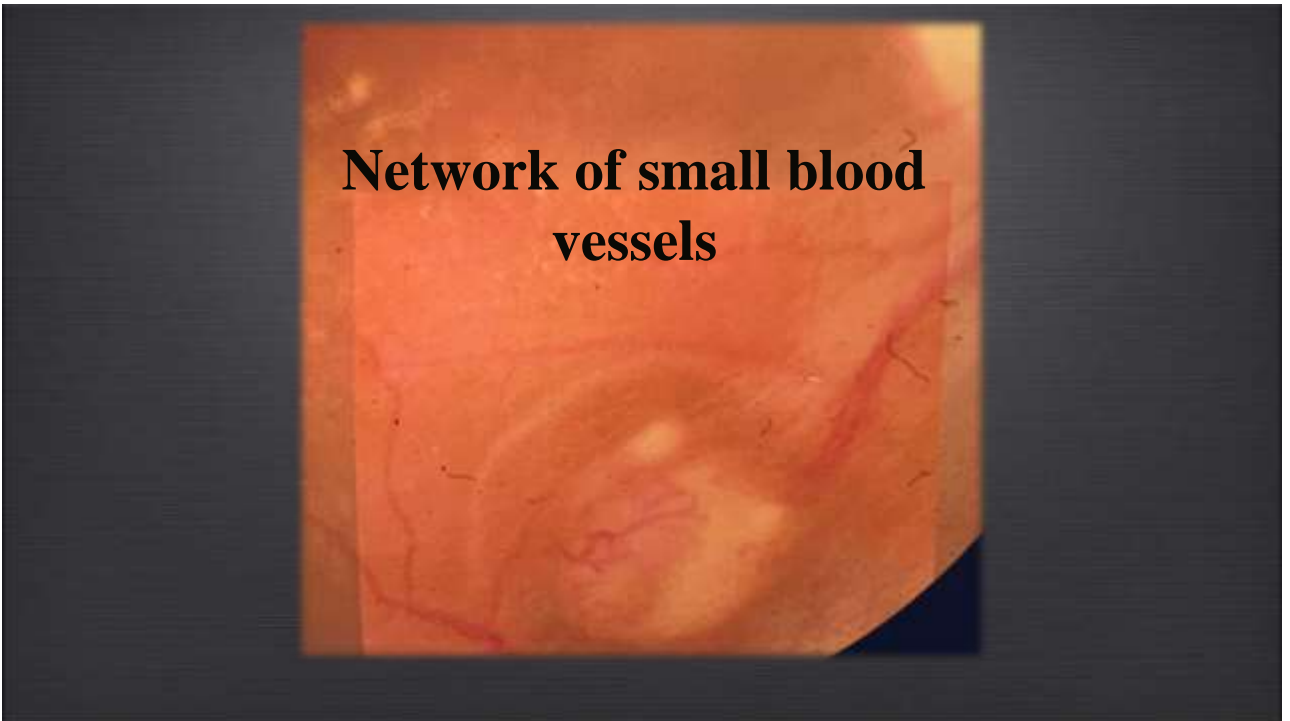


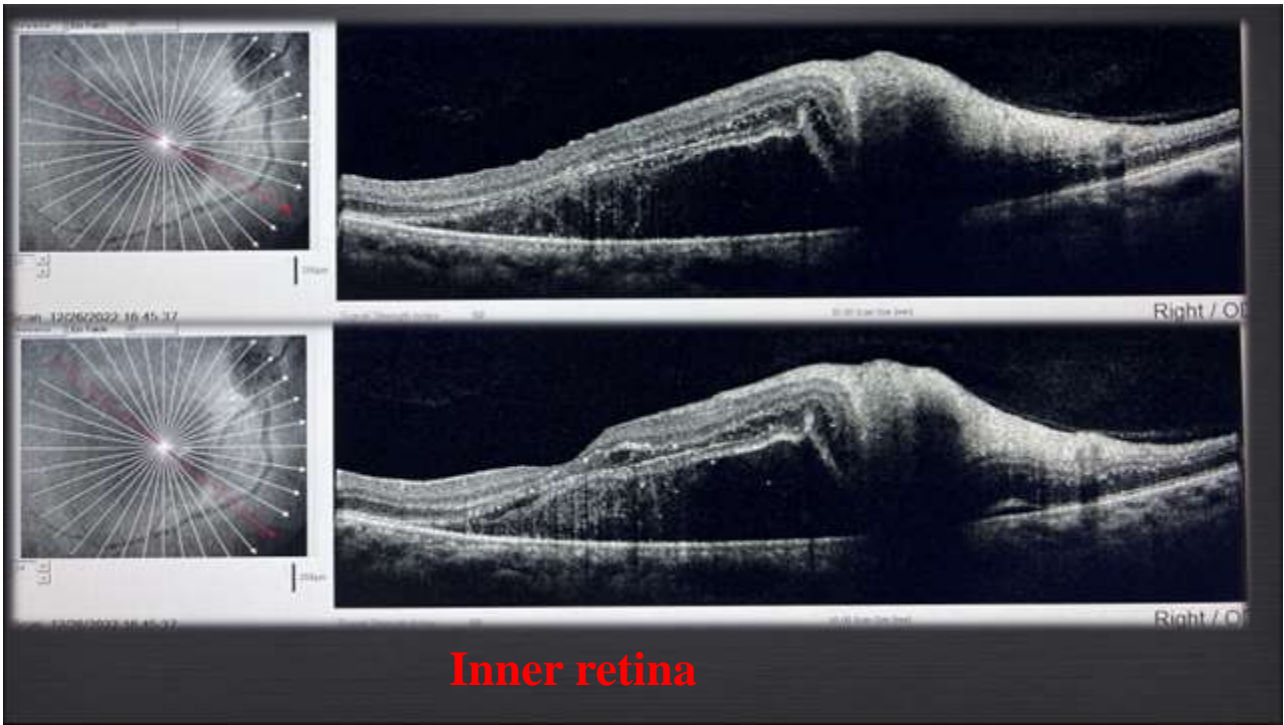
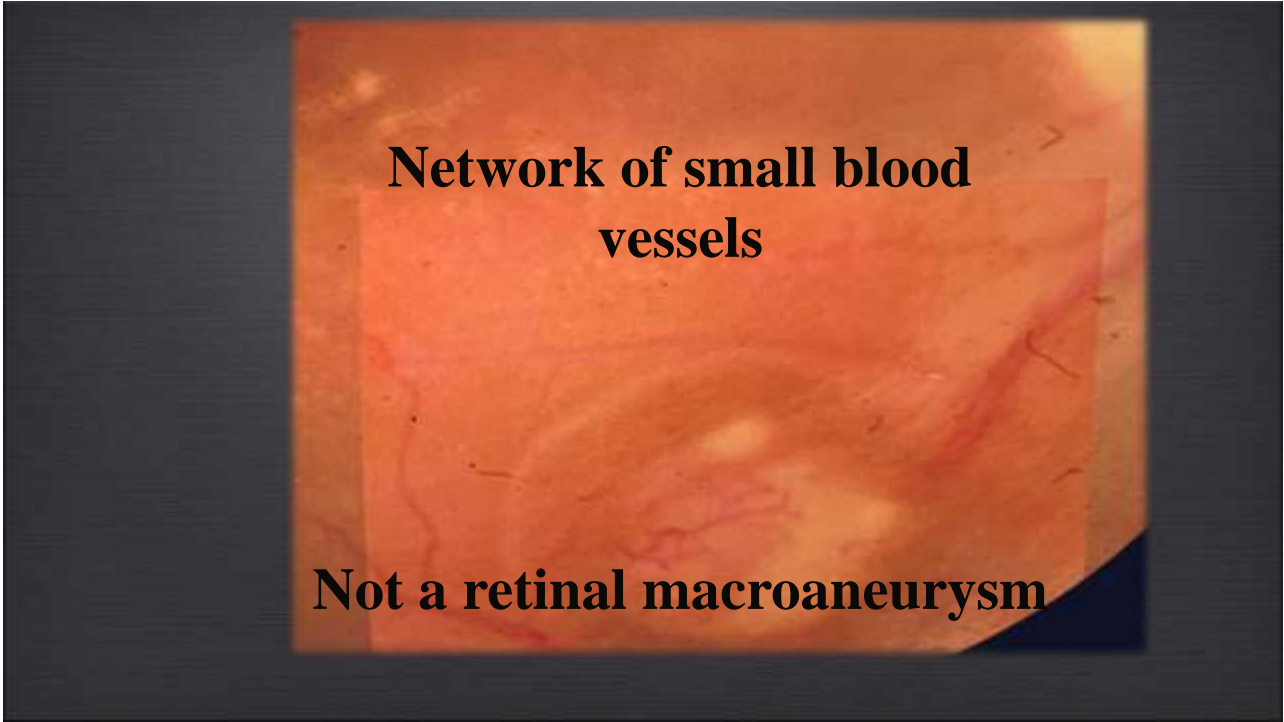
**Retinal Arterial Macroaneurysm:**

- Female ... along an artery ... FFA: early filling
- Not reddish .... Thrombosed RAM is white
- No hge ... Exudative form



**Network of small blood vessels**





- Whitish mass with exudation
- Arising from inner retinal layers

## Retinal Astrocytoma

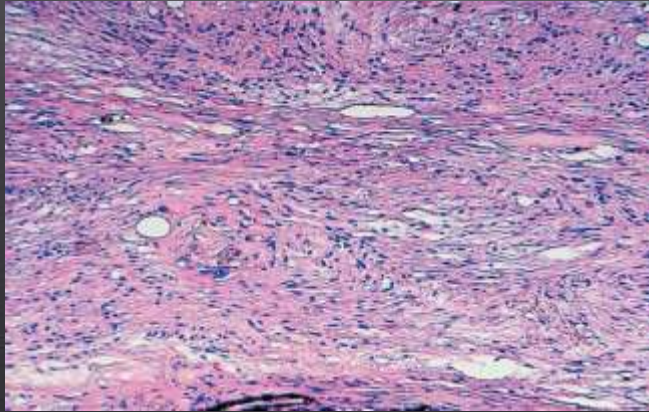
## Retinal Astrocytoma

**But,**

- No calcifications
- No manifestation of Tuber Sclerosis

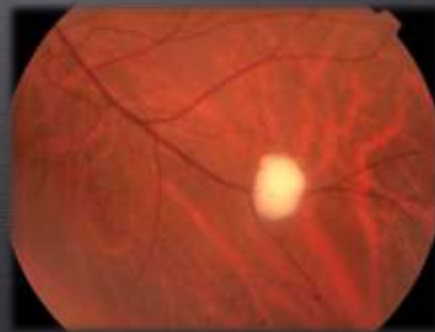## Retinal astrocytic tumors

Arises from glial cells of the sensory retina predominantly astrocytes



## Retinal astrocytic tumors

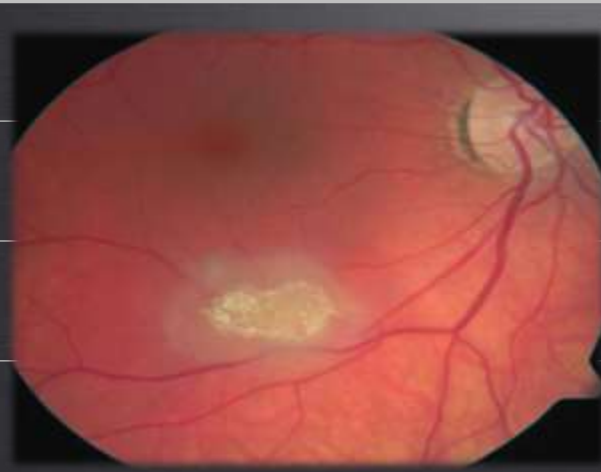### 1. Solitary Circumscribed Retinal Astrocytic Proliferation



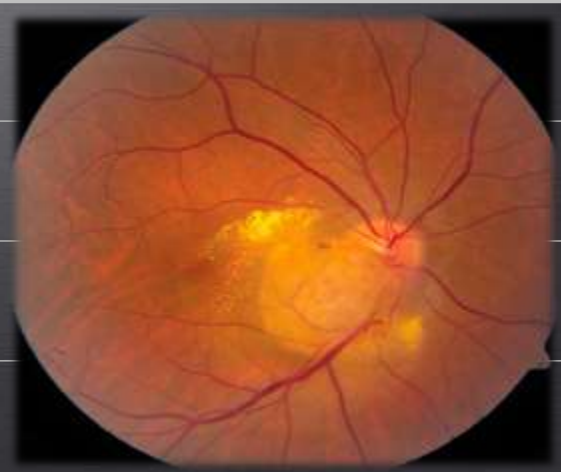## Retinal astrocytic tumors

1. Solitary Circumscribed Retinal Astrocytic Proliferation
2. Retinal Astrocytic hamartoma (RAH)
3. Acquired Retinal Astrocytoma


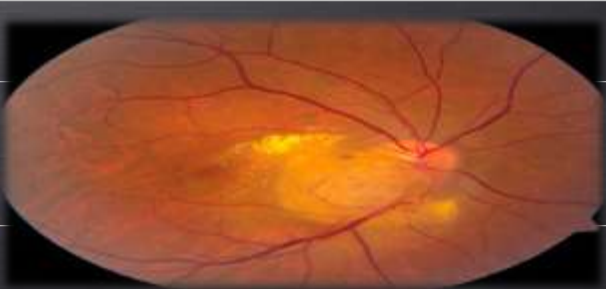
**Retinal Astrocytic  
hamartoma**




**Acquired Retinal  
Astrocytoma**



<b>Retinal Astrocytic hamartoma</b>	<b>Acquired Retinal Astrocytoma</b>
Congenital ... 1 <sup>st</sup> decade	Acquired ... older
Ass. with TSC	Not ass.
Bi, multiple	Uni, Solitary
No growth	Aggressive Growth

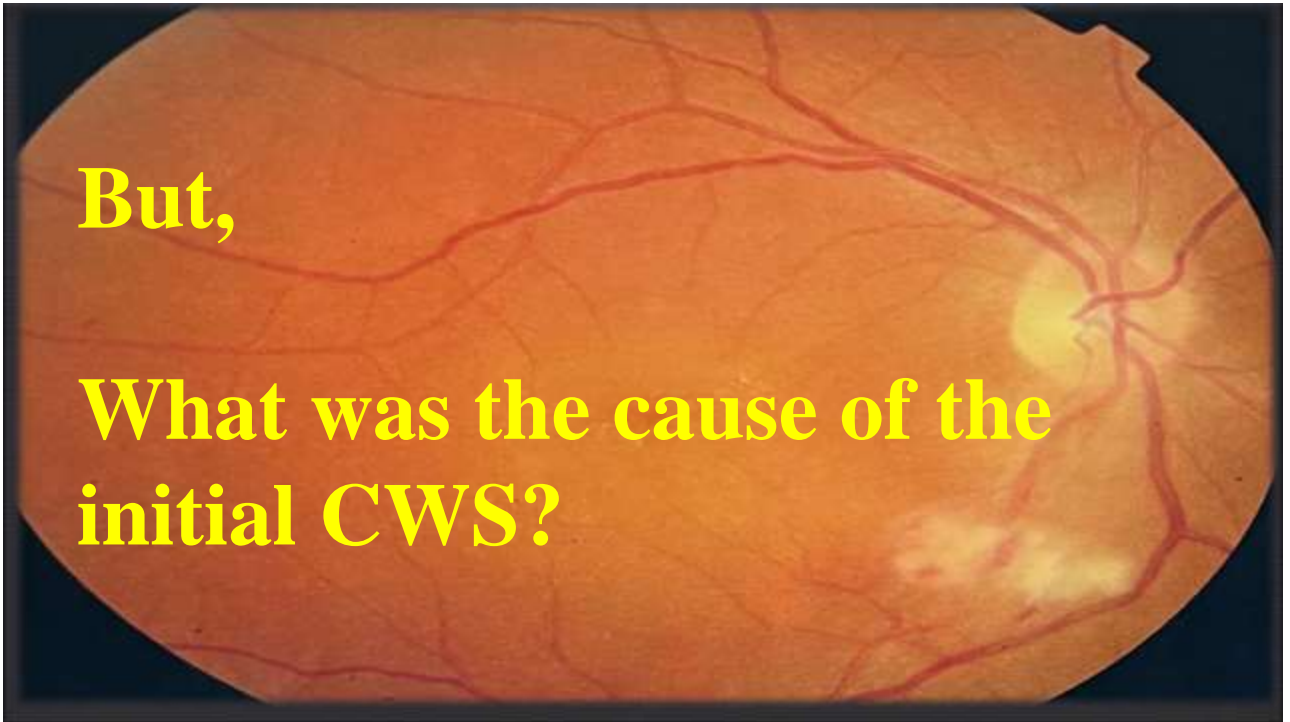<b>Retinal Astrocytic hamartoma</b>	<b>Acquired Retinal Astrocytoma</b>
Yellowish white mass in the superficial retina	
Show Calcification ... Sessile mass	No Calcification
	Intraretinal exudation and secondary retinal detachment
	



<b>Retinal Astrocytic hamartoma</b>	<b>Acquired Retinal Astrocytoma</b>
Yellowish white mass	
Show Calcification ... Sessile mass	
Retinal traction ... not RB	
	Abundant intrinsic vascularity
	Retinal feeder vessels can be apparent, but they are not dilated and tortuous as Rb, RCH

- Solitary
- Yellowish white mass in the inner retina
- Exudation
- Intrinsic vascularity
- No calcification
- Not ass with TSC

## **Acquired Retinal Astrocytoma**



## Cotton wool spots

- Localized swelling of RNFL ...
- Hist: cystoid bodies
- Obstruction of the Axoplasmic transportation in the RNFL leading to accumulation of axoplasmic debris

## Cotton wool spots

- Obstruction of the Axoplasmic transportation in the RNFL leading to accumulation of axoplasmic debris

**Vascular**

**Mechanical**

- ... **NOT** an RNFL infarct

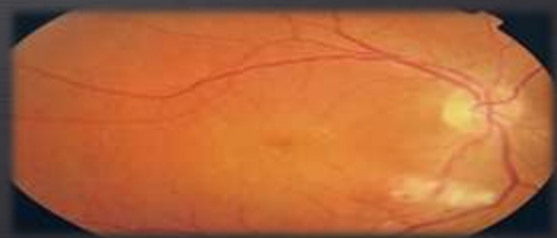## Cotton wool spots

- Obstruction of the Axoplasmic transportation in the RNFL leading to accumulation of axoplasmic debris

**Vascular**

**Mechanical**

- Growing mass



## Management

## Management

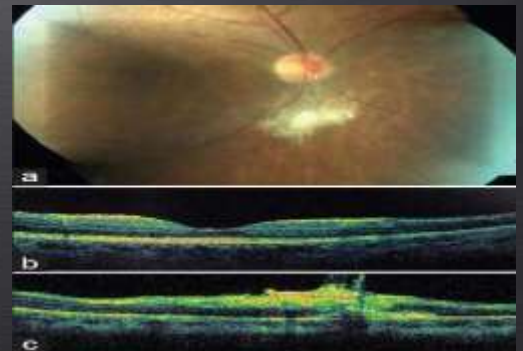
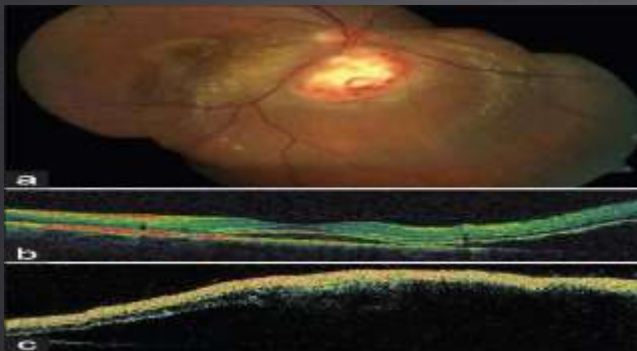
### ➤ Photodynamic Therapy

Middle East Afr. J. Ophthalmol., 2014 Jul-Sep; 21(3): 263-266.  
doi: [10.4103/0974-9233.134689](https://doi.org/10.4103/0974-9233.134689)

PMCID: PMC4123267  
PMID: 25100811

#### Dramatic Regression of Presumed Acquired Retinal Astrocytoma with Photodynamic Therapy

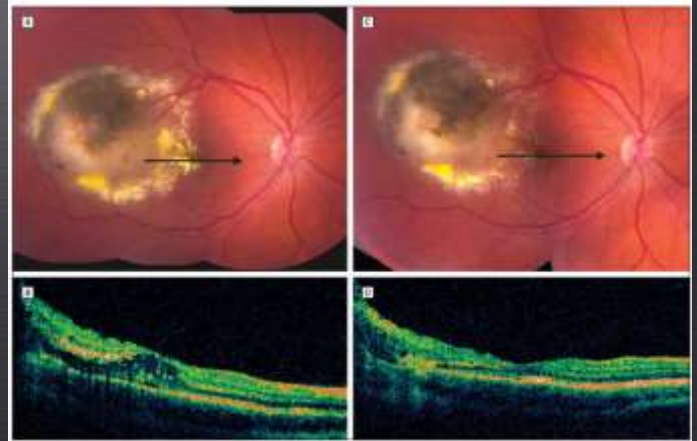
Samiray Tuncer and Zafar Cebeci



## Management

### ➤ Photodynamic Therapy

Case Report | J Arith Ophthalmol, 2018 Feb;12(2):273-4. doi: 10.1001/archophthol.2017.34.  
**Resolution of exudative retinal detachment from retinal astrocytoma following photodynamic therapy**  
 Carol L. Shields<sup>1</sup>, Miguel A. Matero, Brian P. Mac, James Rajagopal, Jerry A. Shields



## Management

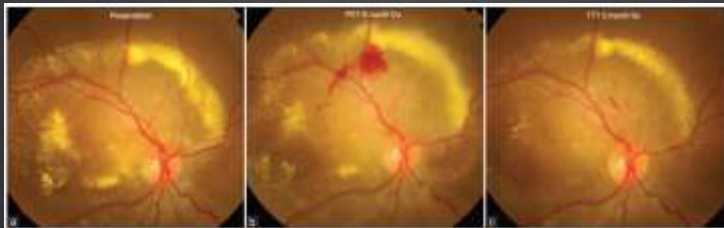### ➤ Transpupillary Thermotherapy

Indian J Ophthalmol, 2020 Jul; 68(7): 1446-1447.  
 Published online 2020 Jun 25. doi: [10.4103/ijo.IJO\\_1724\\_19](https://doi.org/10.4103/ijo.IJO_1724_19)

PMCID: PMC7574059  
 PMID: [32587188](https://pubmed.ncbi.nlm.nih.gov/32587188/)

**Acquired retinal astrocytoma: Transpupillary thermotherapy may be a viable alternative treatment option**

Divyashish Dubey, Rajesh Ramaniulu, Mahesh P. Shanmugam, and Divyansh K. Mishra



## Management

### ➤ Endoresection

Case Reports > Retina. 2006 Nov-Dec;26(9):1081-2. doi: 10.1097/01.iae.0000254888.63519.3c.

#### Acquired retinal astrocytoma managed with endoresection

Daniel Vilaplana <sup>1</sup>, Miguel Castilla, Vladimir Poposki, Francesc Alameda, Carol L Shields

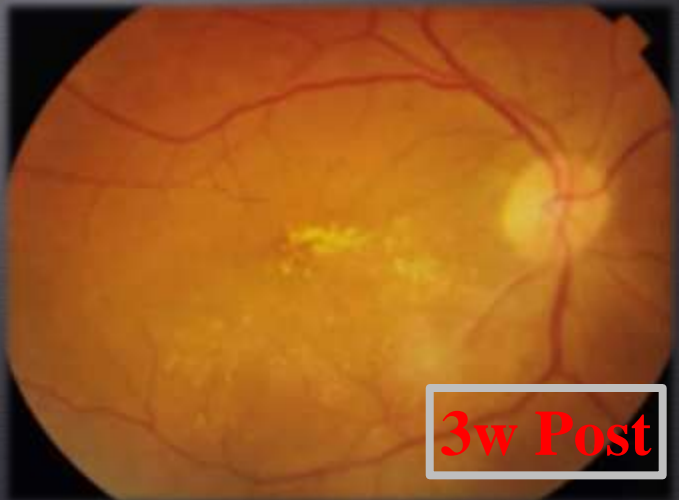
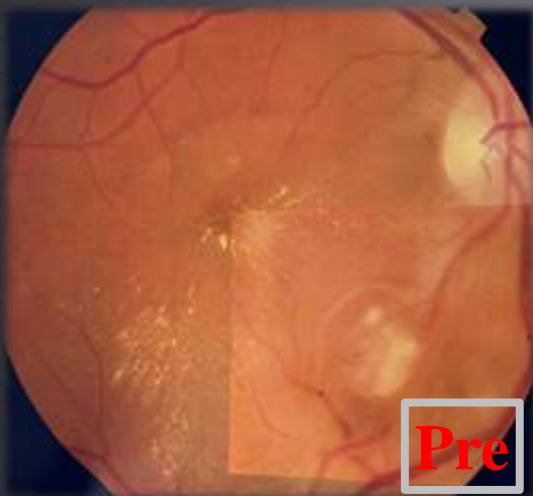
## Transpupillary Thermotherapy

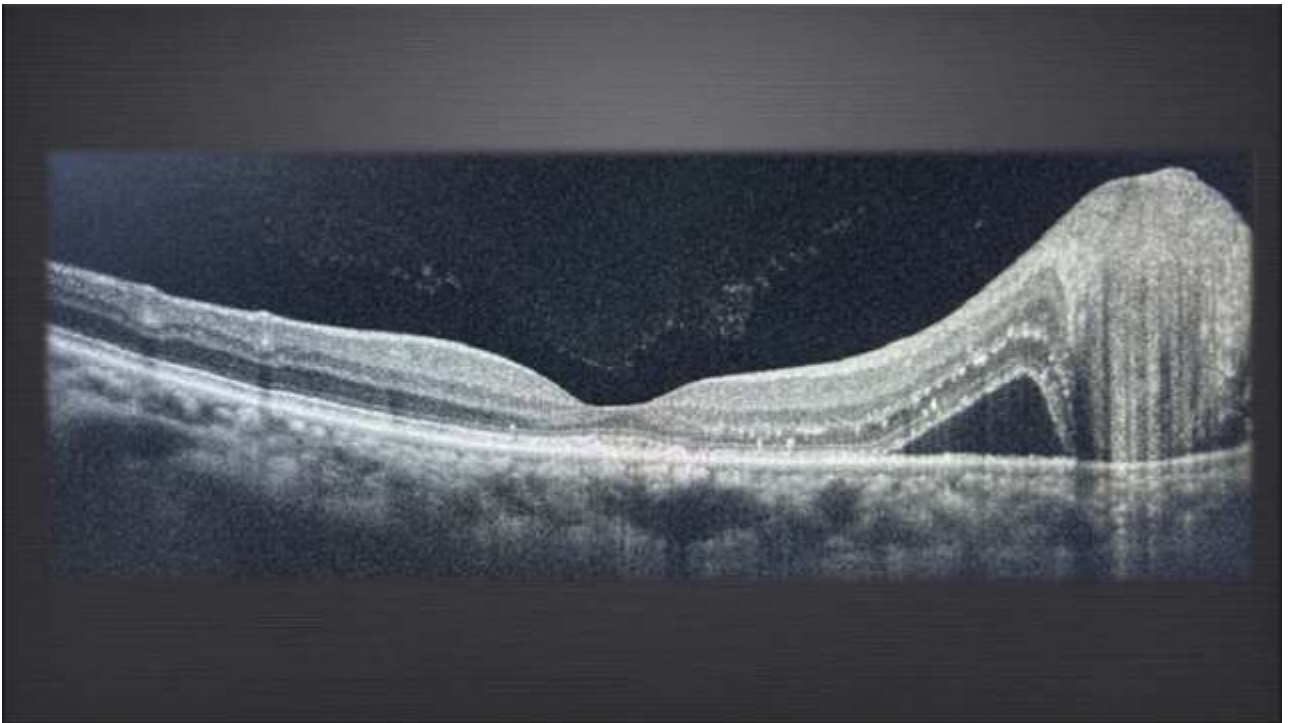
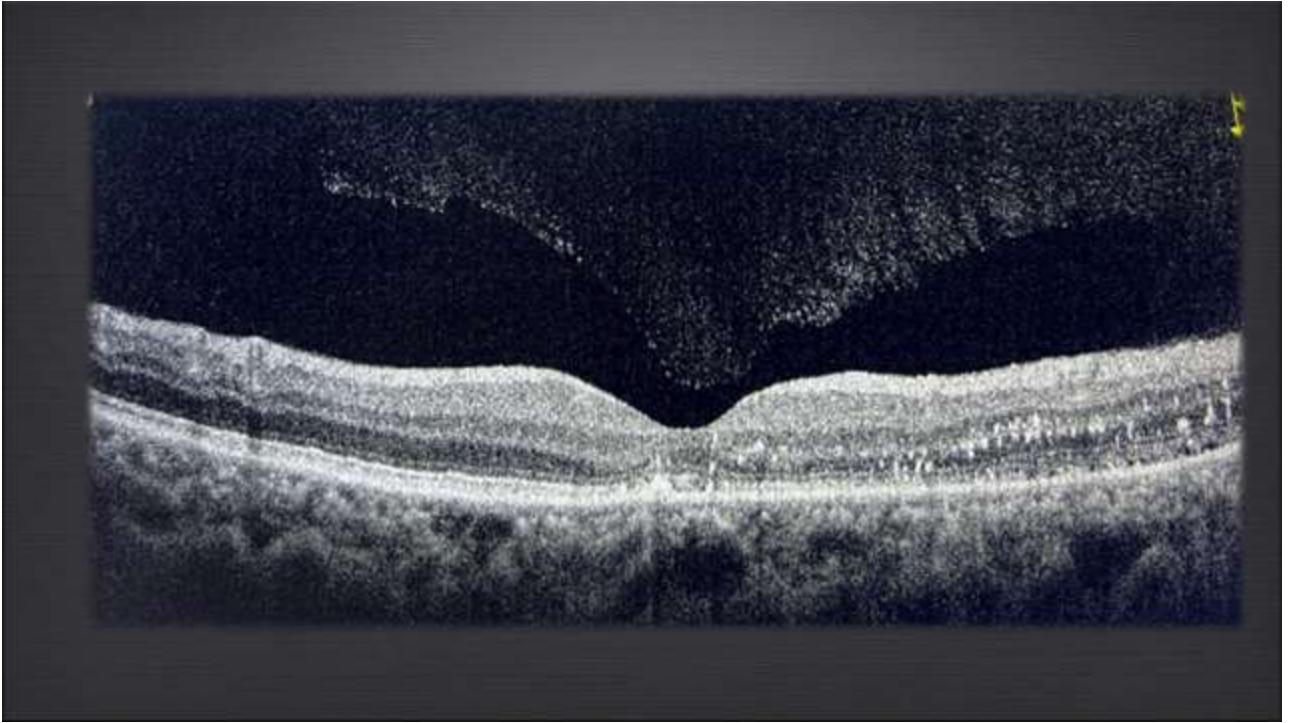
## Transpupillary Thermotherapy

Dual mode of action.

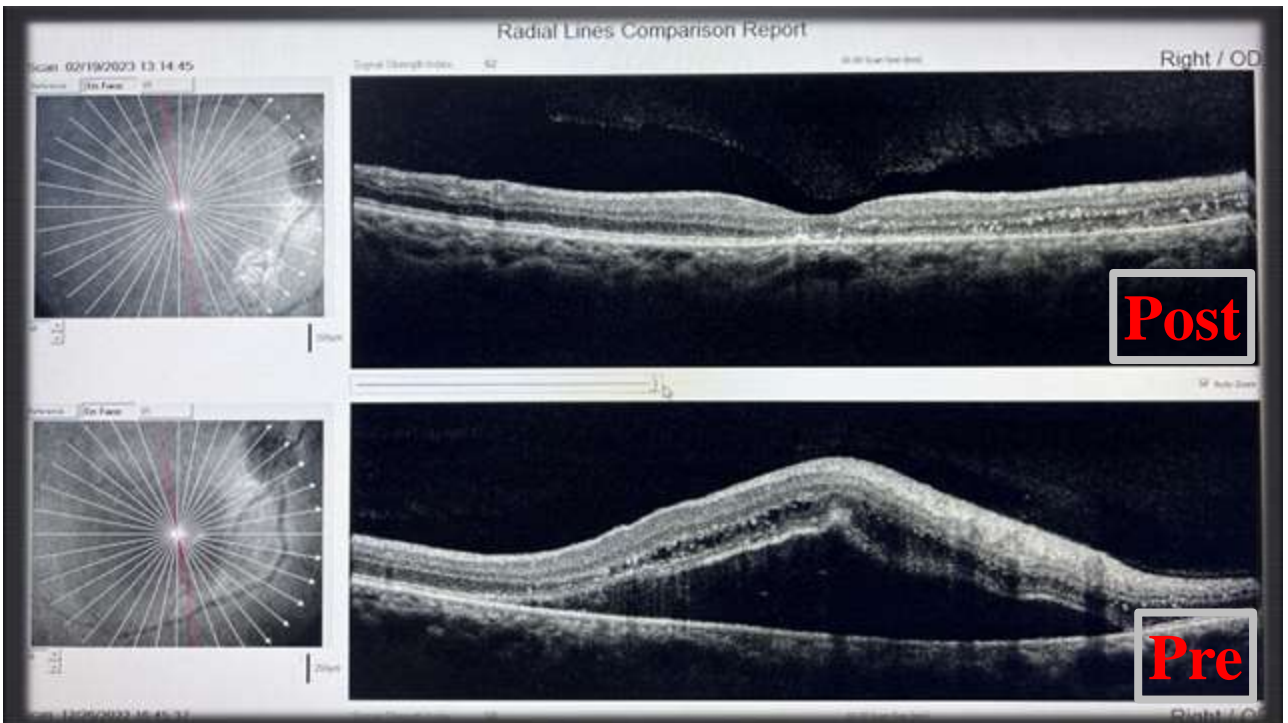
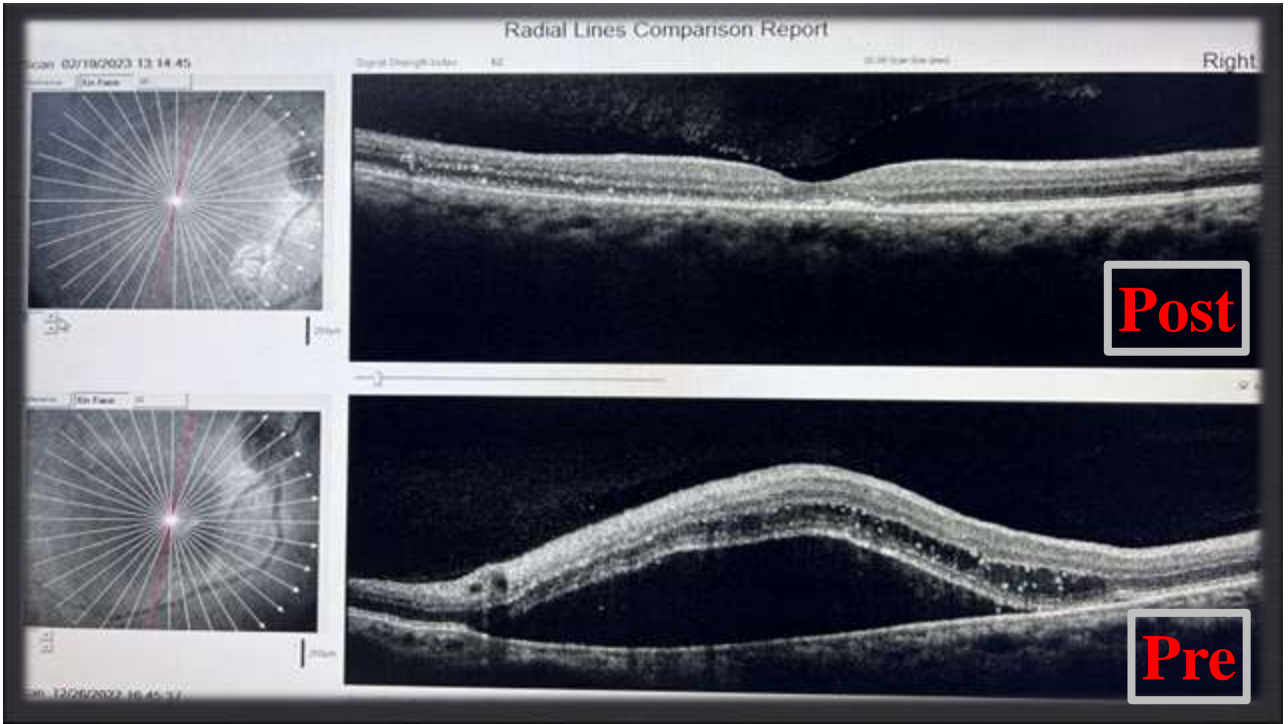
- Thermal cytotoxic damage leading to cell apoptosis.
- Heat-induced sclerosis of the vascular channels causing tumor regression and resolution of exudation

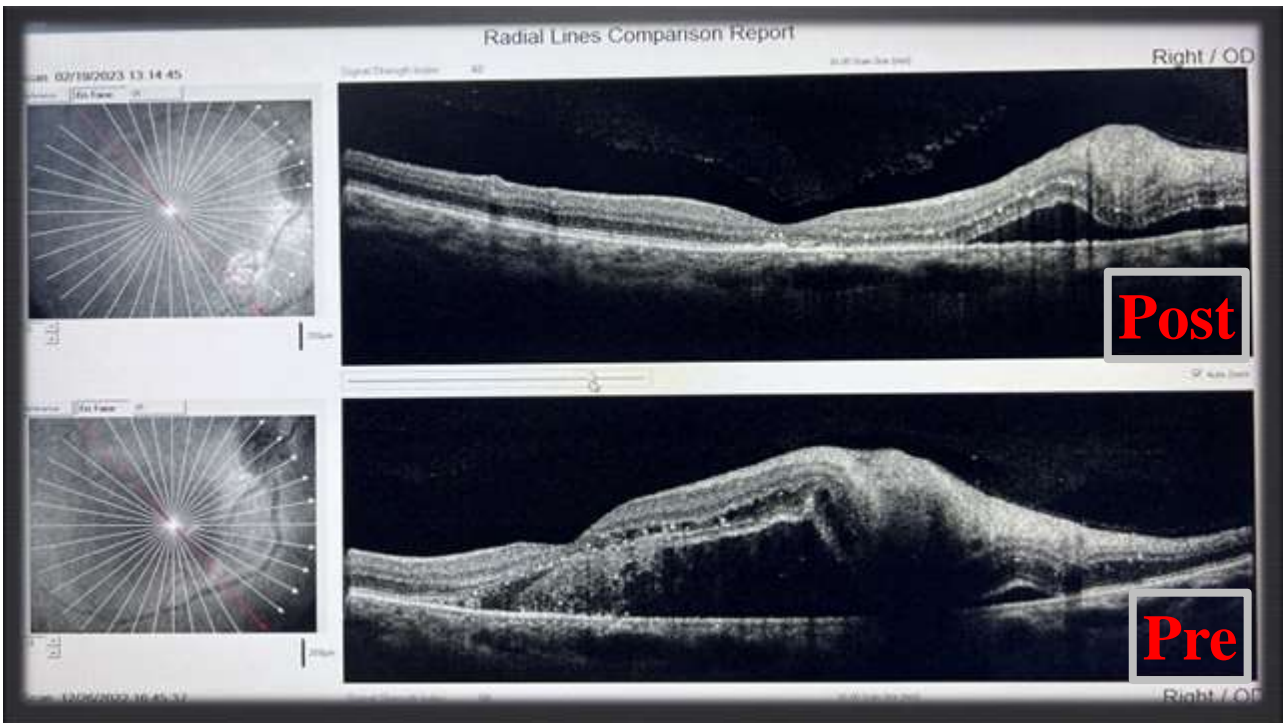
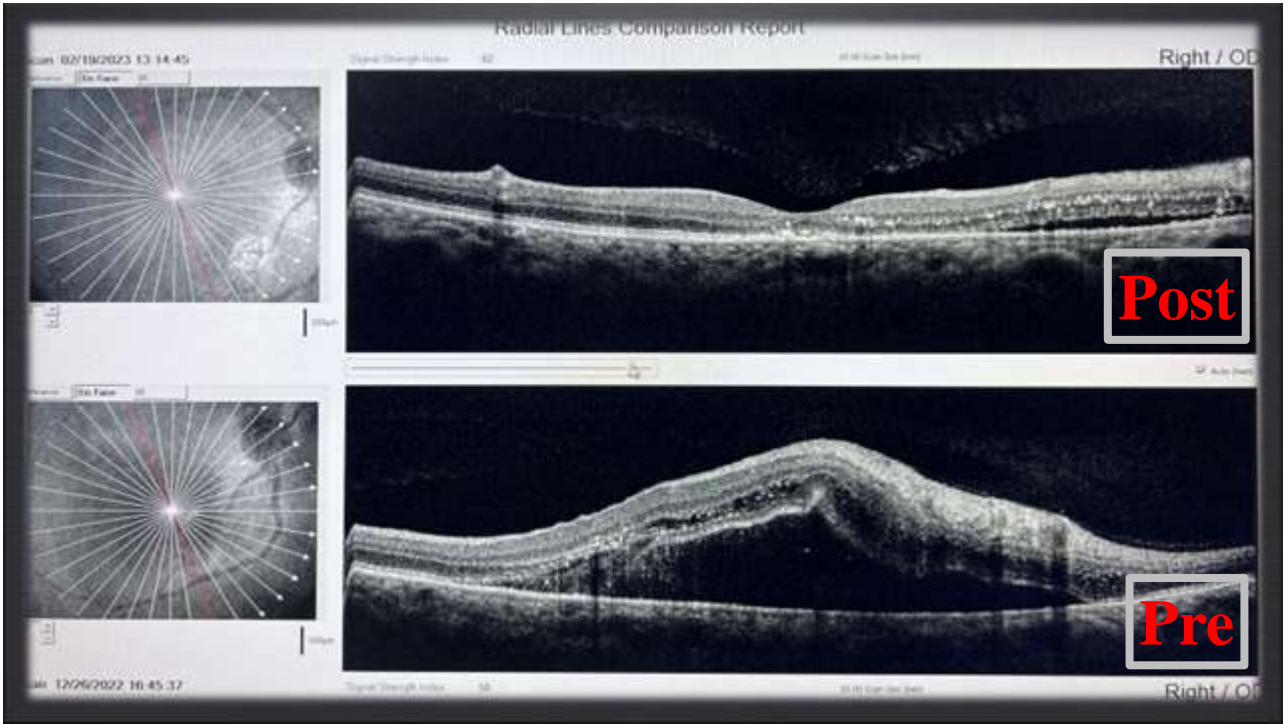
### TTT

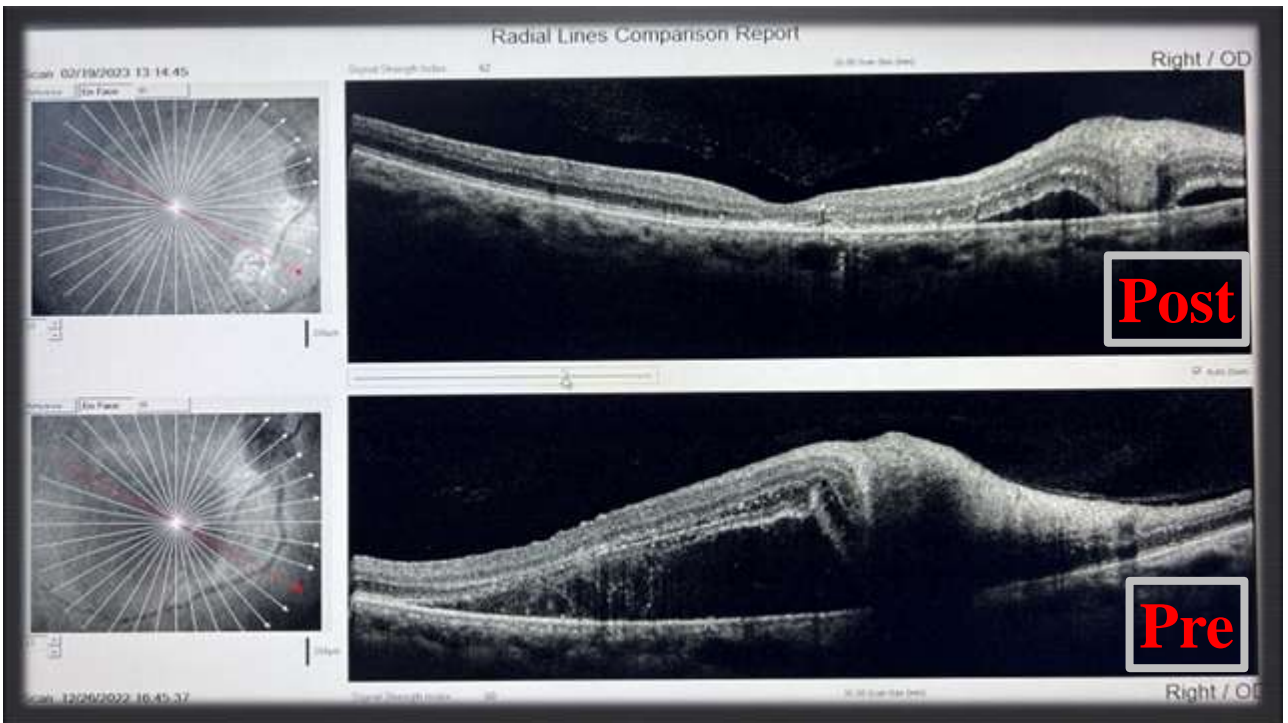
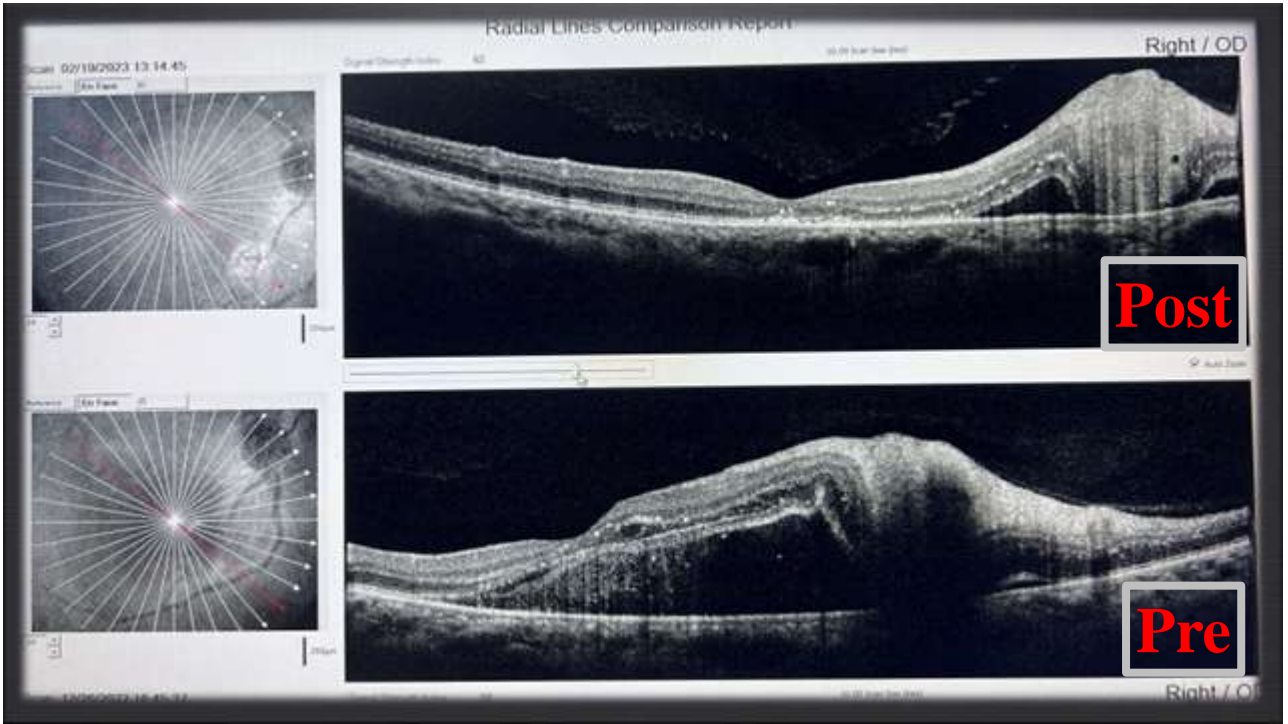












At the end ...

One should be aware about the **Astrocytic tumors**

Clinical picture  
Investigations  
Treatment

*Thank you for your attention*