

المؤتمر السنوي الدولي للجمعية المصرية  
INTERNATIONAL CONGRESS OF THE

EGYPTIAN OPHTHALMOLOGICAL SOCIETY

**EOS 2023**



## **Patient Selection for Lasik**

**Mortada Abozaid, MD**  
**Prof. of Ophthalmology-Sohag**  
**University**



***No Conflict of Interest***

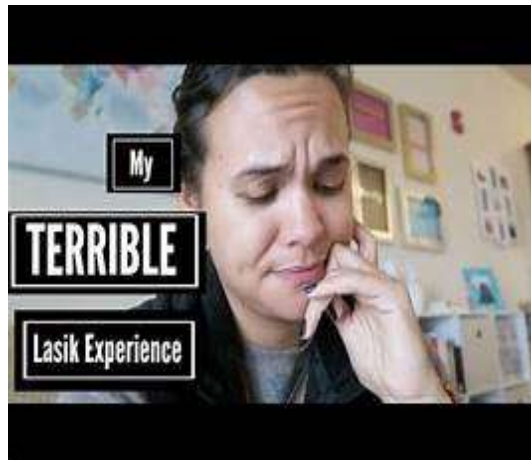

**EOS 2023**

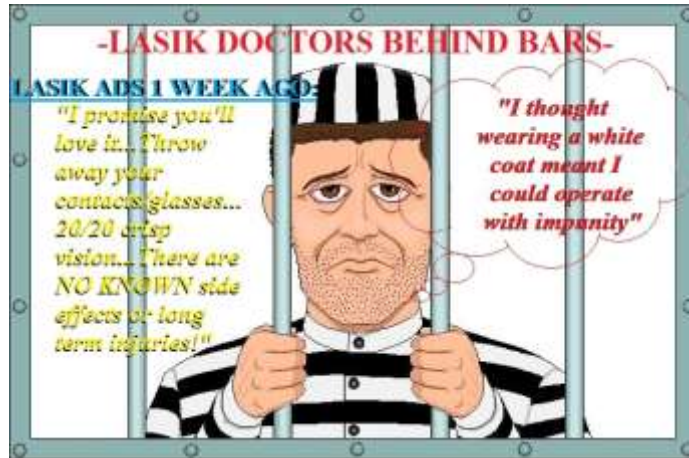
## *The happy patient*



## *The unhappy patient*



## Medico-legal Problems



EOS2023



## Indications

- Patient more than 18 year old
- **Stable Error of refraction:**
  1. Myopia (-1.00 to -12.00 D)
  2. Hyperopia (+1.00 to +6.00 D)
  3. Astigmatism (up to 5 D)
- **Normal corneal tomography and adequate corneal thickness.**
- Realistic expectations



EOS2023



## *Absolute contraindications*

### **A) General**

- Pregnancy
- Systemic collagen vascular disease
- Diabetes mellitus – uncontrolled
- AIDS



EOS 2023



## *Absolute contraindications*

### **B) Ocular**

- Keratoconus or PMD
- Severe dry eye
- Active eye inflammation or infection
- Past herpes eye infection.
- Advanced or uncontrolled glaucoma



EOS 2023



## *Absolute contraindications*

### C) Surgical technical exclusions

- Preoperative central corneal thickness less than 480  $\mu\text{m}$ .
- Preoperative central corneal curvature more than 48 D or less than 40 D.
- Postoperative stromal bed thickness less than 300  $\mu\text{m}$ .
- PTA > 40%
- Postoperative central corneal curvature not less than 35 D (myopic lasik) and not greater than 49 D (hyperopic lasik)



EOS2023



## *Relative contraindications*

### A) General:

- **Diabetes mellitus – controlled**
- **Patients receiving systemic steroids or hormone replacement therapy or isotretinoin.**
- **Breast-feeding**



EOS2023



## *Relative contraindications*

### **B) Ocular:**

- **Dry eye – mild**
- **Glaucoma – controlled, minimal nerve damage**
- **Epithelial basement membrane dystrophy**
- **Sunken globe, blepharophimosis and narrow palpebral fissure**

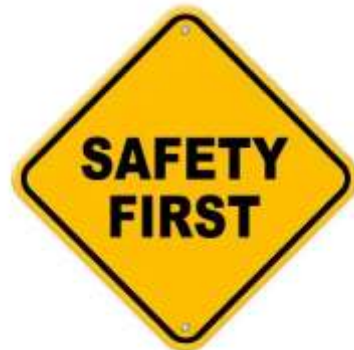

EOS2023



## *Precautions*

- Family history of ectasia
- **Strabismus**
- **Amblyopia**
- **Taking Amiodarone or Sumatriptan**
- **Large pupils**
- **Activities in dim Light**
- **Activities that could damage the flap**
- Allergy or eye rubbing



EOS2023



## *The Ideal Candidate*

The **younger** you are, the more you think about **what can go right.**

The **older** you are, the more you think about **what can go wrong.**



EOS2023



## *Preoperative Examination*

- Healthy eye
- Success defined by the patient
- Separate day
- Identify candidates
- Patients expectations
- Presbyopic patients

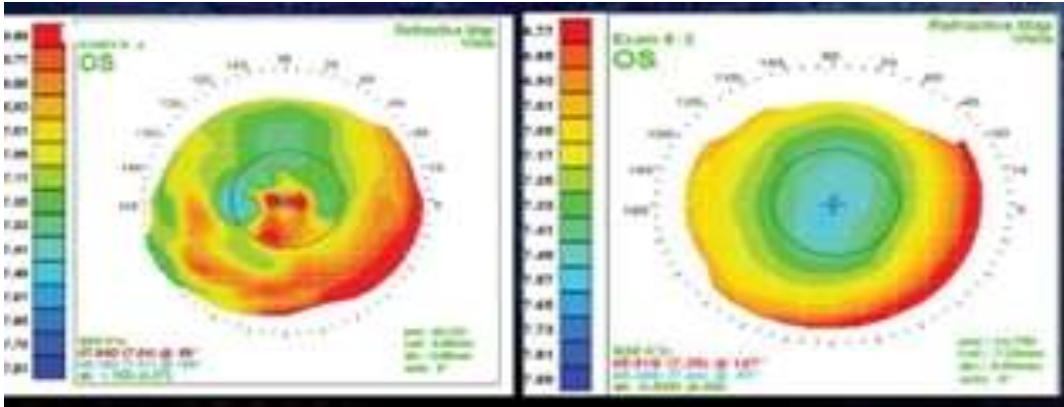
**What do patients expect?**



EOS2023



## *Discontinuation of CL wear*



EOS 2023



## *Visual Acuity & Refraction*

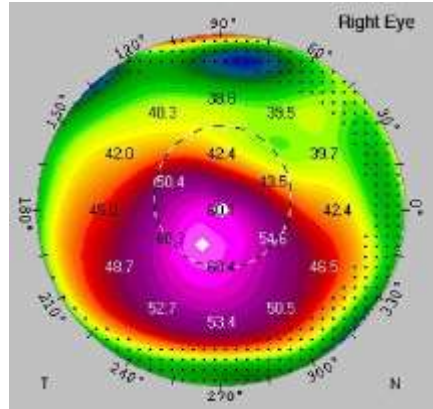
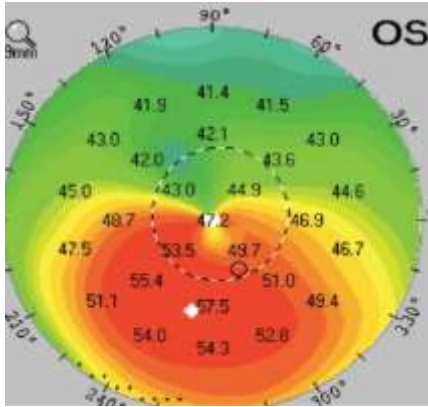


EOS 2023





# Corneal Tomography



EOS2023



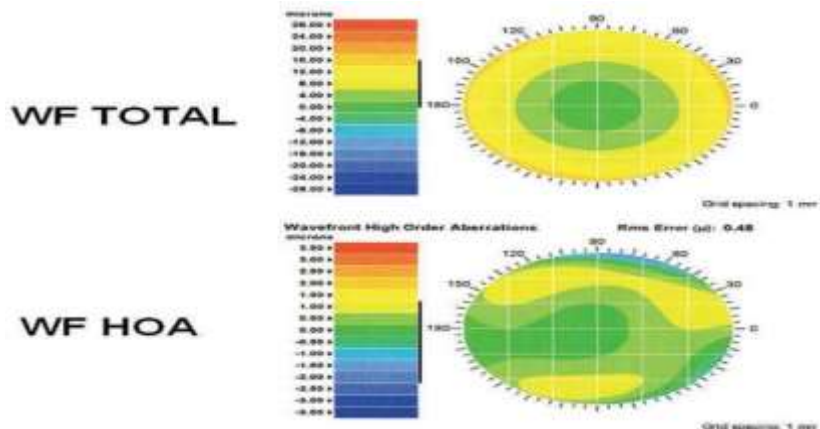
# Pupil Size



EOS2023



## Wavefront Aberrometry



EOS2023



## Other Tests

- IOP
- Dilated Fundus Examination
- Ocular dominance
- Ocular position and motility
- Gonioscopy
- Specular microscopy
- ORA

EOS2023



## *Informed Consent*

- Alternatives
- Contraindications
- Complications
- What to expect within 6 months
- Long-term side effects
- Future eye health



EOS2023



## *Glare*

No Glare ←

→ Severe Glare



EOS2023



# *Halo*

No Halo ← → Severe Halo



EOS 2023



# *Starburst*


No Starburst ← → Severe Starburst



EOS 2023



## *Double Vision*



EOS 2023



## *Take home message*

It is always much **easier** to explain to a patient why he **can't have surgery** than why he developed a **significant complication**.

**5 Ps: Proper Preparation Prevents Poor Performance.**



EOS 2023





# THANK YOU

*See you next year*

المؤتمر السنوي الدولي للجمعية الرمحية المصرية  
INTERNATIONAL CONGRESS OF THE

**EGYPTIAN  
OPHTHALMOLOGICAL SOCIETY**

**EOS 2024**

**24-26 APRIL 2024**

InterContinental Citystars, Cairo, Egypt

