

# Phaco in Narrow Pupil



Mahmoud N. Afifi, *MD*  
*Research Institute Of Ophthalmology*  
**CAIRO - EGYPT**



## Causes of narrow pupil:

- ❑ Pseudoexfoliation:
  - fibrotic sphincter
  - atrophic capsule
  - friable zonules
- ❑ Anterior uveitis
- ❑ DM
- ❑ IFIS
- ❑ Glaucoma
- ❑ Old age
- ❑ Trauma



## Management:

---

### Pharmacological:

- Atropine 1%
- Cyclopentolate 1%
- Phenylephrine 2.5 % - 10 %
- Tropicamide 1 % (Mydriacyl)
- NSAID



## Surgical:

---

### Synechialysis:

Viscodissection

Blunt surgical dissection

Membrane peeling

### Iris stretch (pupil expand. devices):

Iris hooks

Morcher ring

Malugin ring

Beehler dilator (3)

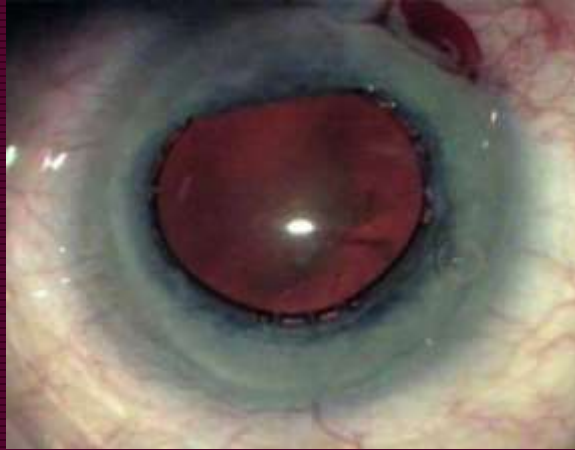
Iris retractors

*(Dinsmore,1998, Fine,2000, & Gimbel,2001)*

---

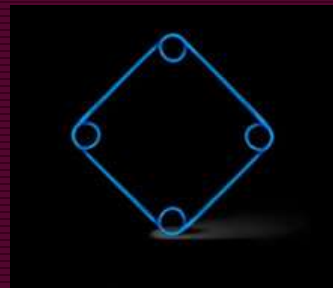
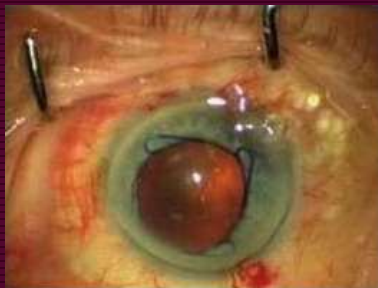
## Morcher ring:

---




## Malugin ring:

---



## Pupil Dilator Rings :



- Open ring:
  - a Perfect ring
  - b Morcher dilator
- Closed ring:
  - c Graether 2000
  - d Malugin ring
  - e Oasis iris expander
  - f Xpand NT iris speculum

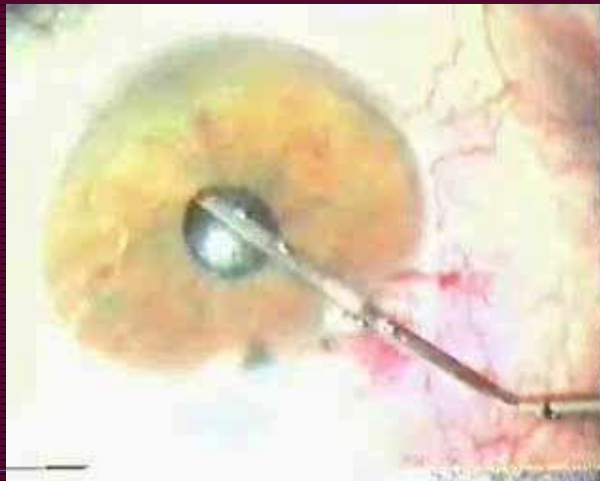
*(Grzbowski and Kanclers, 2020)*



- Multiple sphincterotomies  
0.5 mm – up to 8 in number
- Sector iridectomy

*(Graether & Fine, 2000)*

Synechialysis, Peeling, Iris hooks :



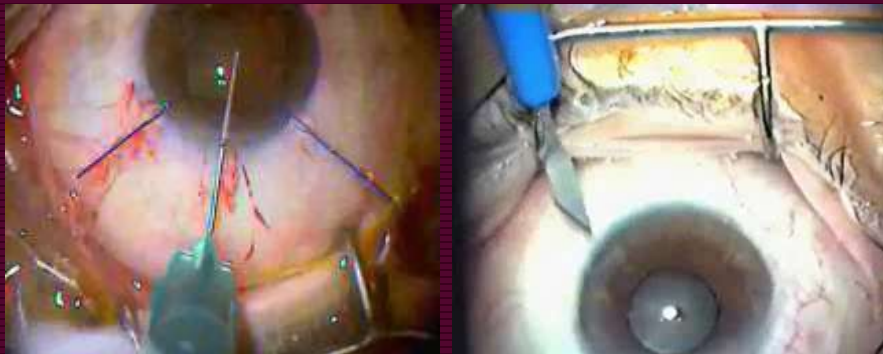
## In synechialysis, *You have to:*

---

- Be slow
  - Watch the capsule and iris
  - 360 degrees (*complete*)
  - Look for membrane, (*transparent*)
  - Manage near pupillary edge
- 

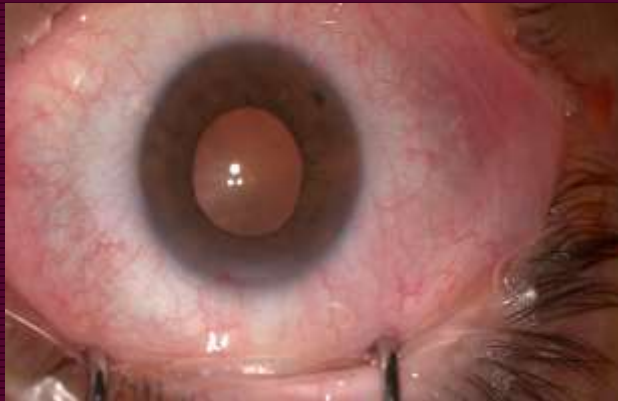## Iris retractors :

---



## Iris Retractors in IFIS :

---



## Iris Retractors VS Malyugin ring:

---

### *With Iris Retractors:*

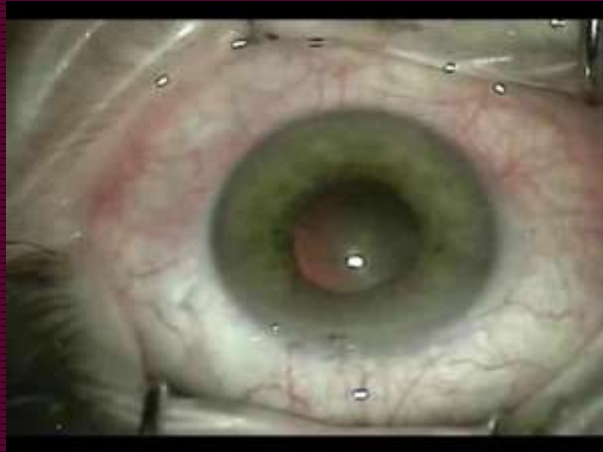- Longer Op time (*4 mins*)
- Can fit any pupil
- Less PO ant uveitis & corneal edema
- Less sphincter damage
- More economic
- No significant diff in CR, zonular dialysis and PO-DVA

*(Nderitu and Ursell , 2019)*

---

## Useful Iris Entangling(IFIS):

---



## Consequences of iris manipulations:

---

- Flail iris
- Iris prolapse
- Iris injury
- Iridodialysis
- Capsular injury
- PO distorted pupil



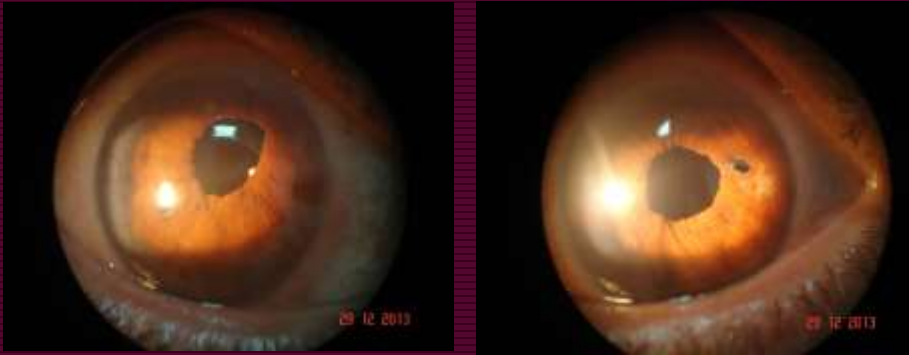
*( Masket,1998, & Allan,1995)*

---



## Postoperative distorted pupil :

---



## Surgical plan:

---

- Diminish iris manipulations
- Limbal stab location
- Diminish infusion
- Diminish vacuum
- Tight wound
- Generous visco application



( Samuelson,1999)

---

## Take home message (5 Pearls):

- ❑ Pharmacologic dilatation
- ❑ Know the **cause** of narrow pupil
- ❑ Membrane dissection (**look for it**)
- ❑ Retractors **OR** rings **OR** hooks dilatation
- ❑ Ask about **general medications**

***THANK YOU***

