

المؤتمر السنوي الدولي للجمعية الرمادية المصرية
INTERNATIONAL CONGRESS OF THE
EGYPTIAN OPHTHALMOLOGICAL SOCIETY
EOS 2023



Recipient Preparation

Prof. Dr. Tarek Katamish
Cairo University



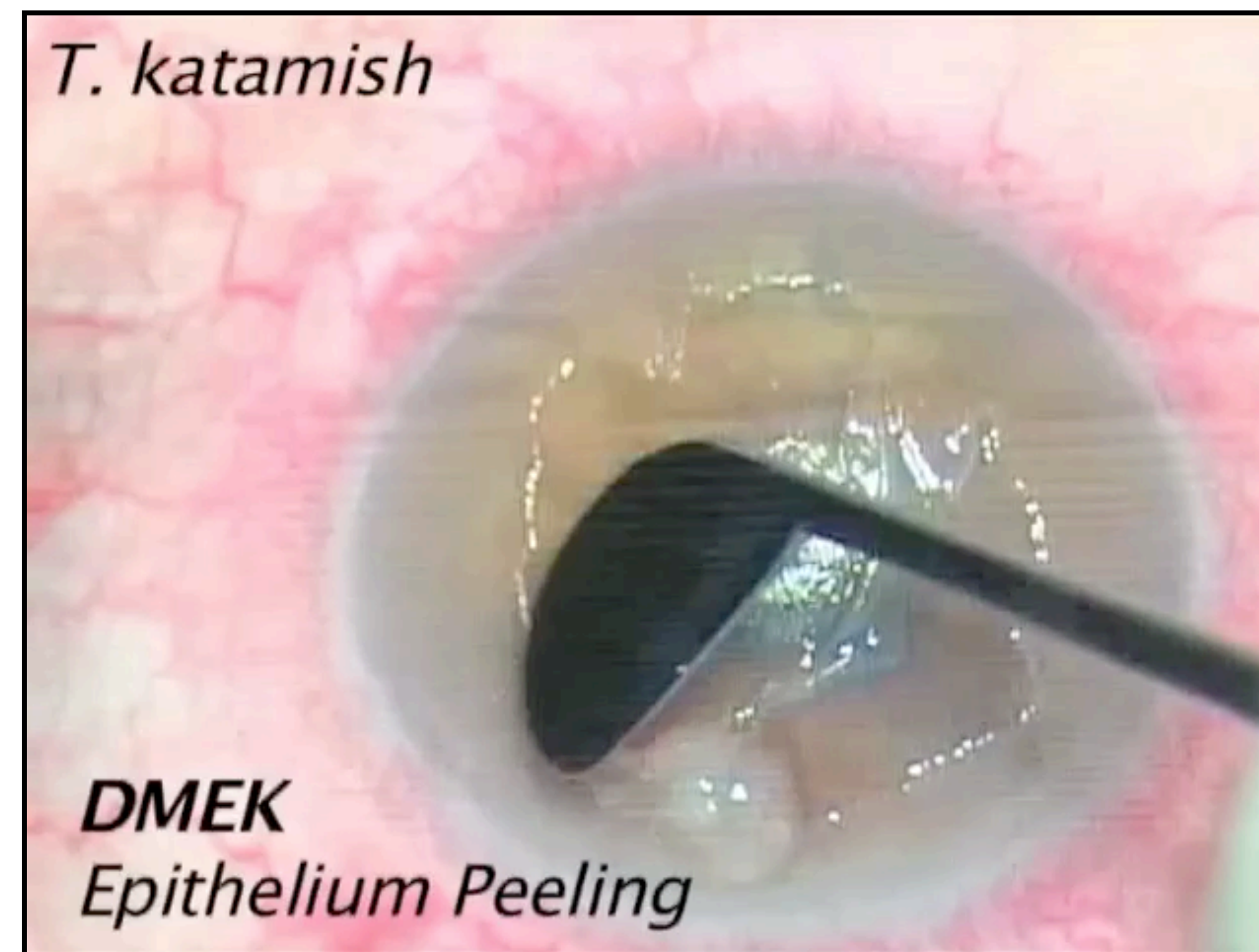
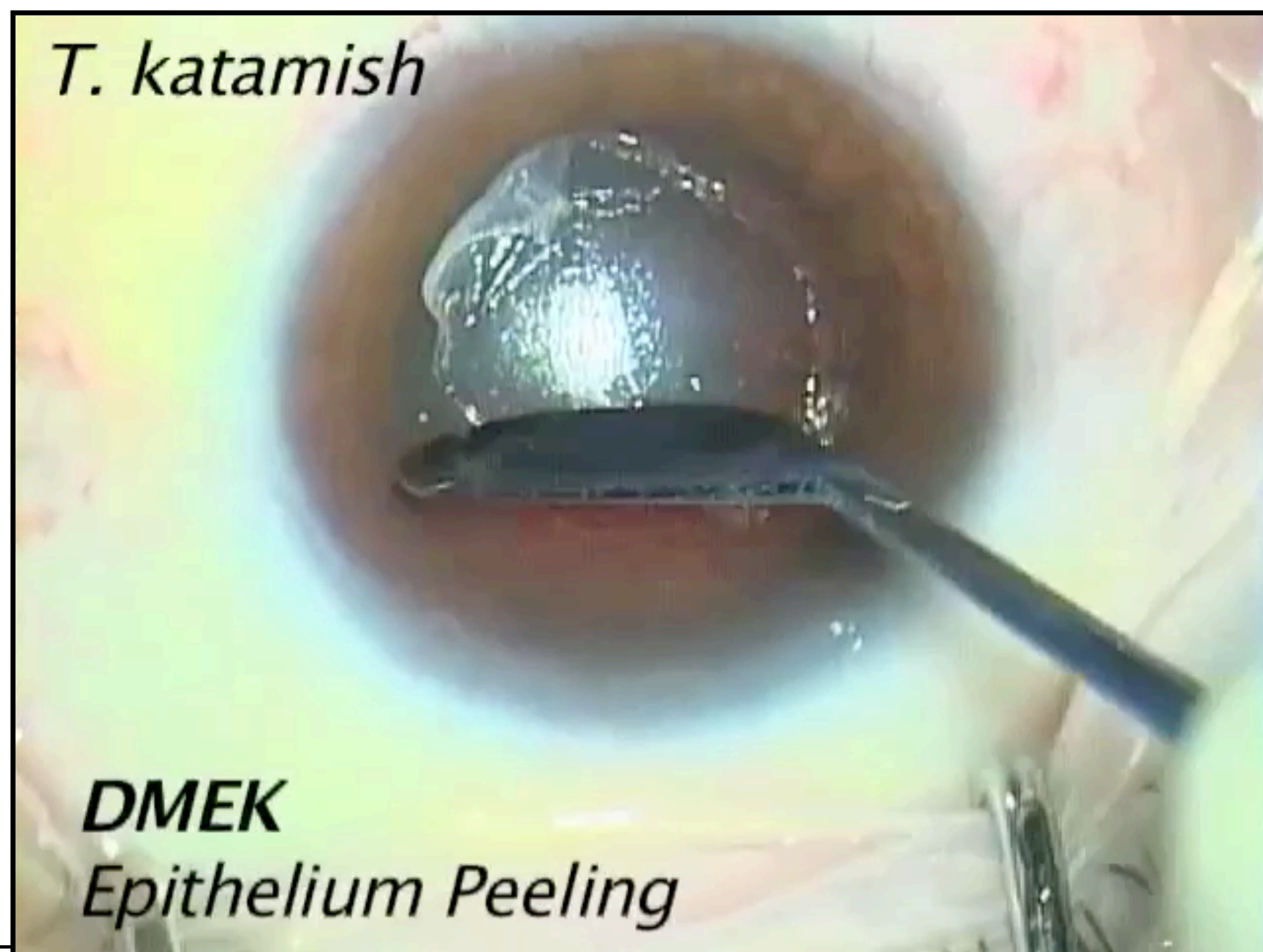
Recipient Preparation

is as important as donor preparation!

- Proper visualization >>> master your technique
- Perfect wound construction >>> stability of AC
- Meticulous DM-Rhexsis >>> smooth underling stroma
- Inferior iridectomy >>> guard against pupillary block

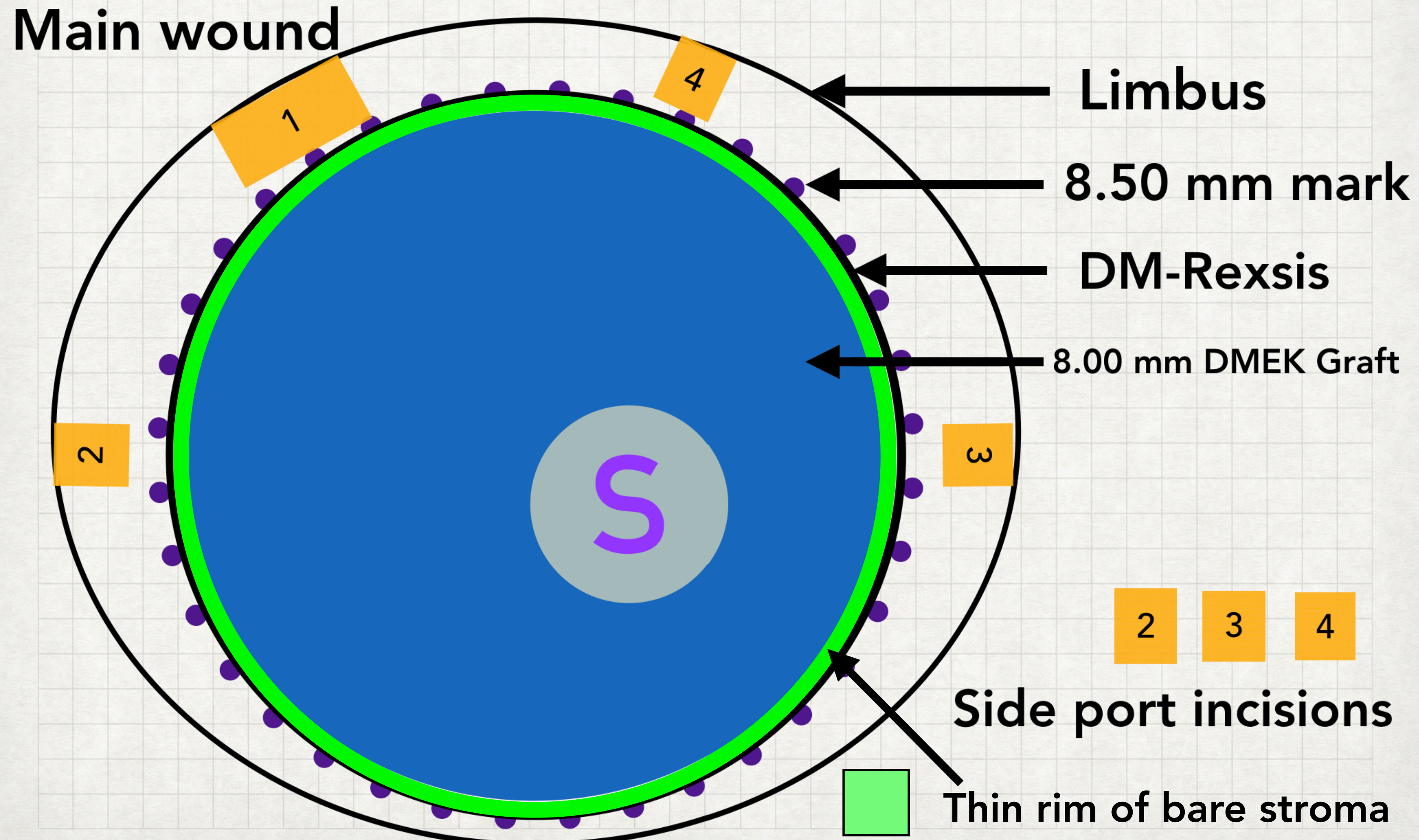
Recipient Preparation

A. Improve Visualization



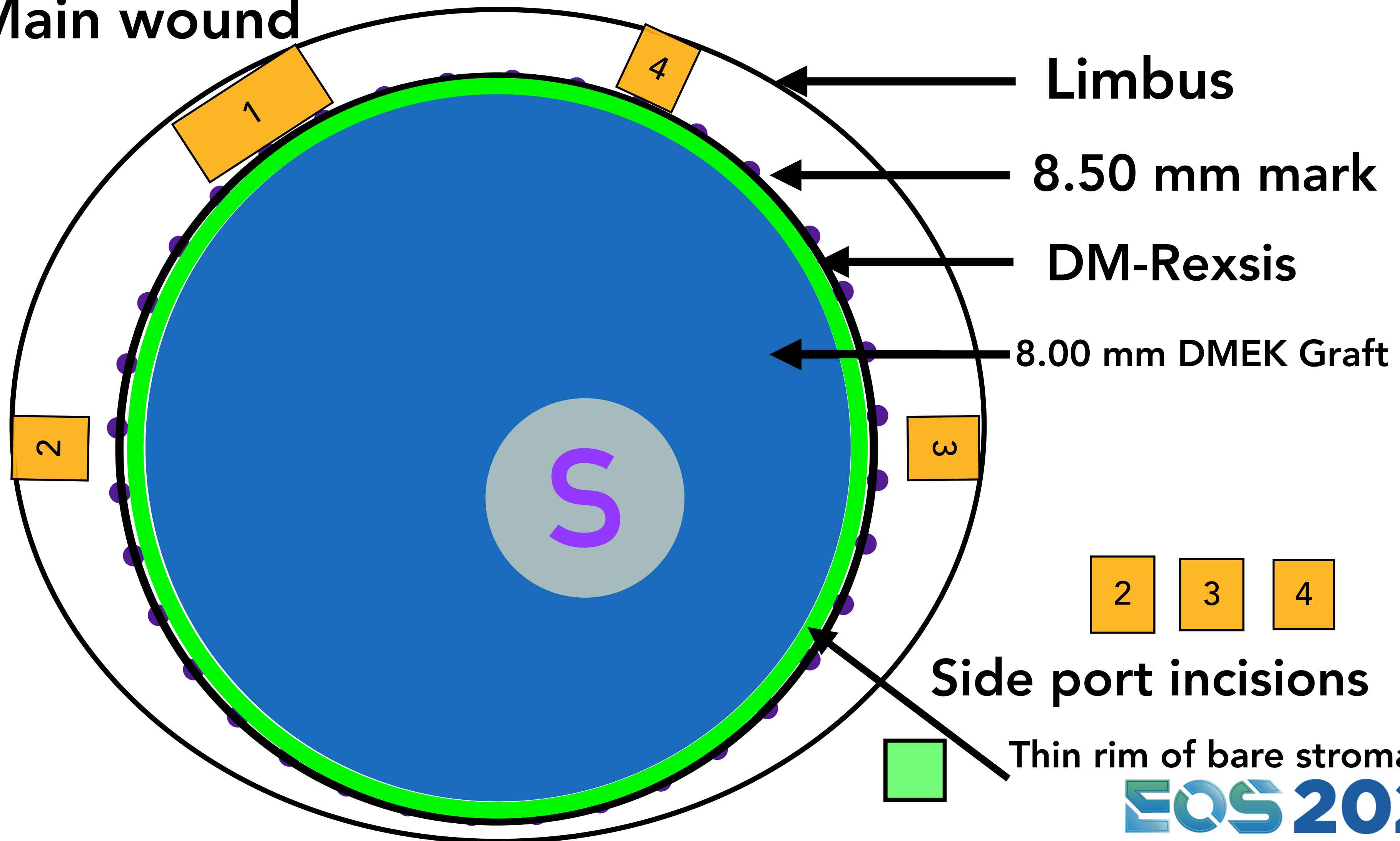
Recipient Preparation

B. Wound Construction



WOUND CONSTRUCTION & MARKING

Main wound



Limbus

8.50 mm mark

DM-Rexsis

8.00 mm DMEK Graft

2 3 4

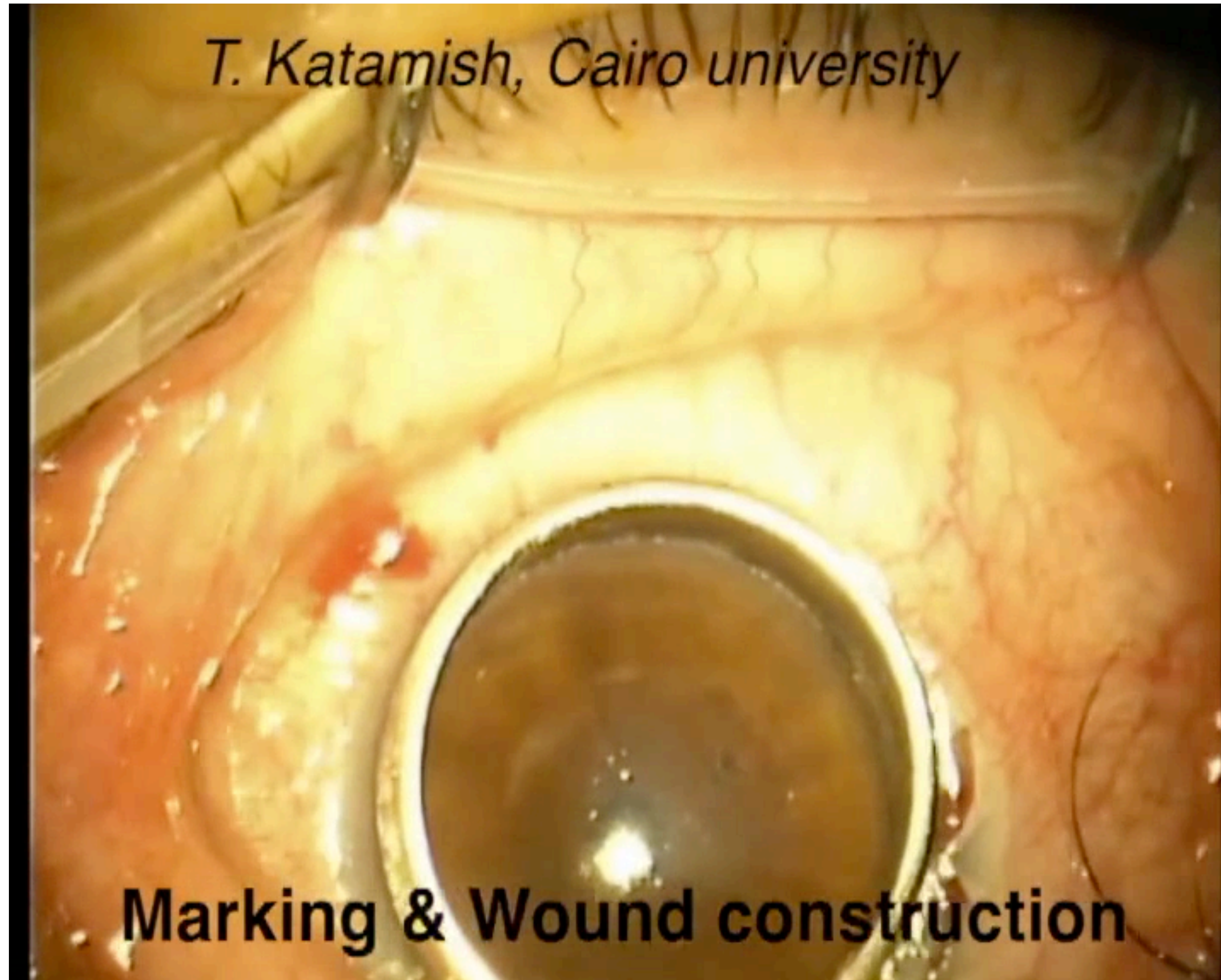Side port incisions

Thin rim of bare stroma

EOS 2023



Wound construction & marking



Recipient Preparation

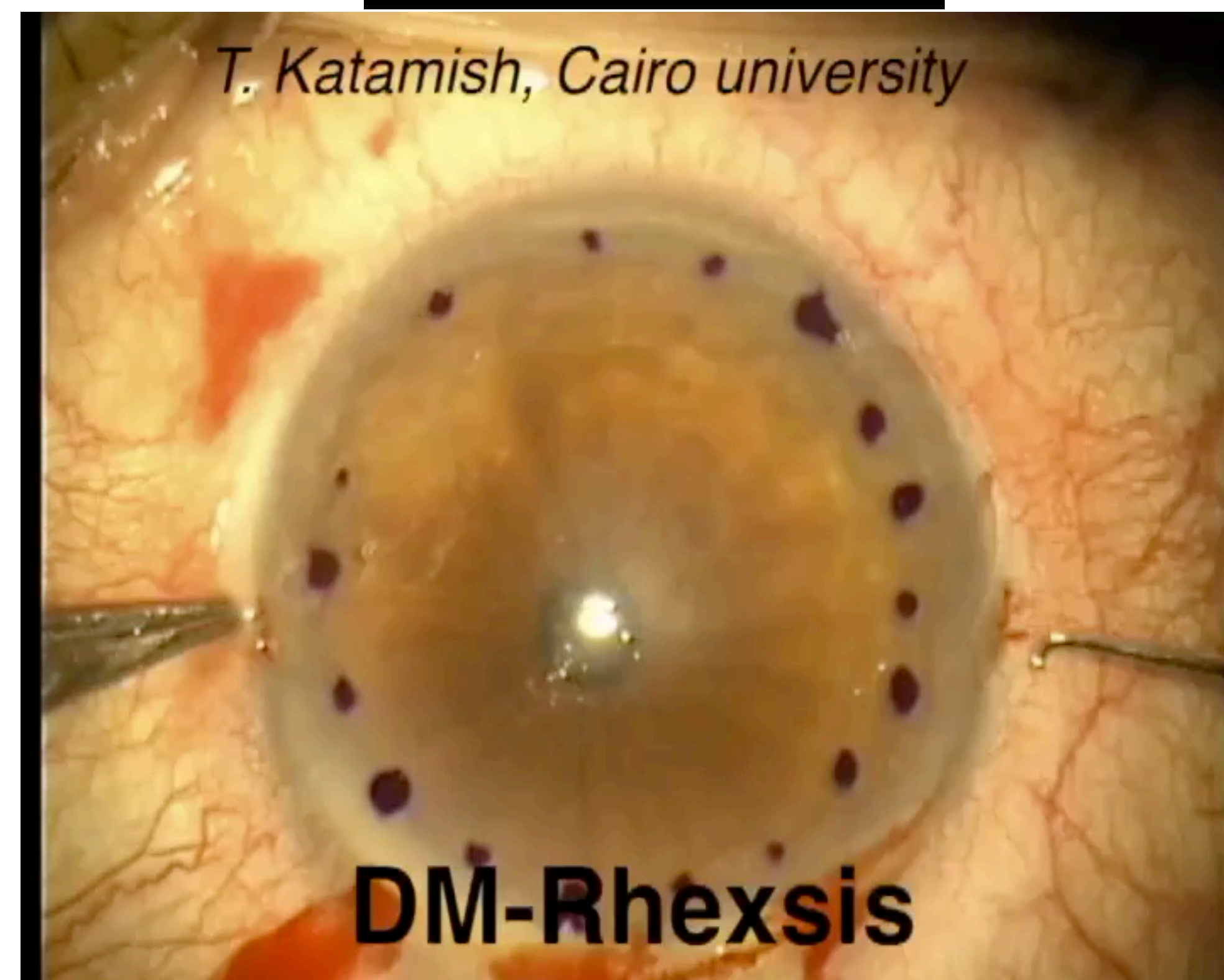
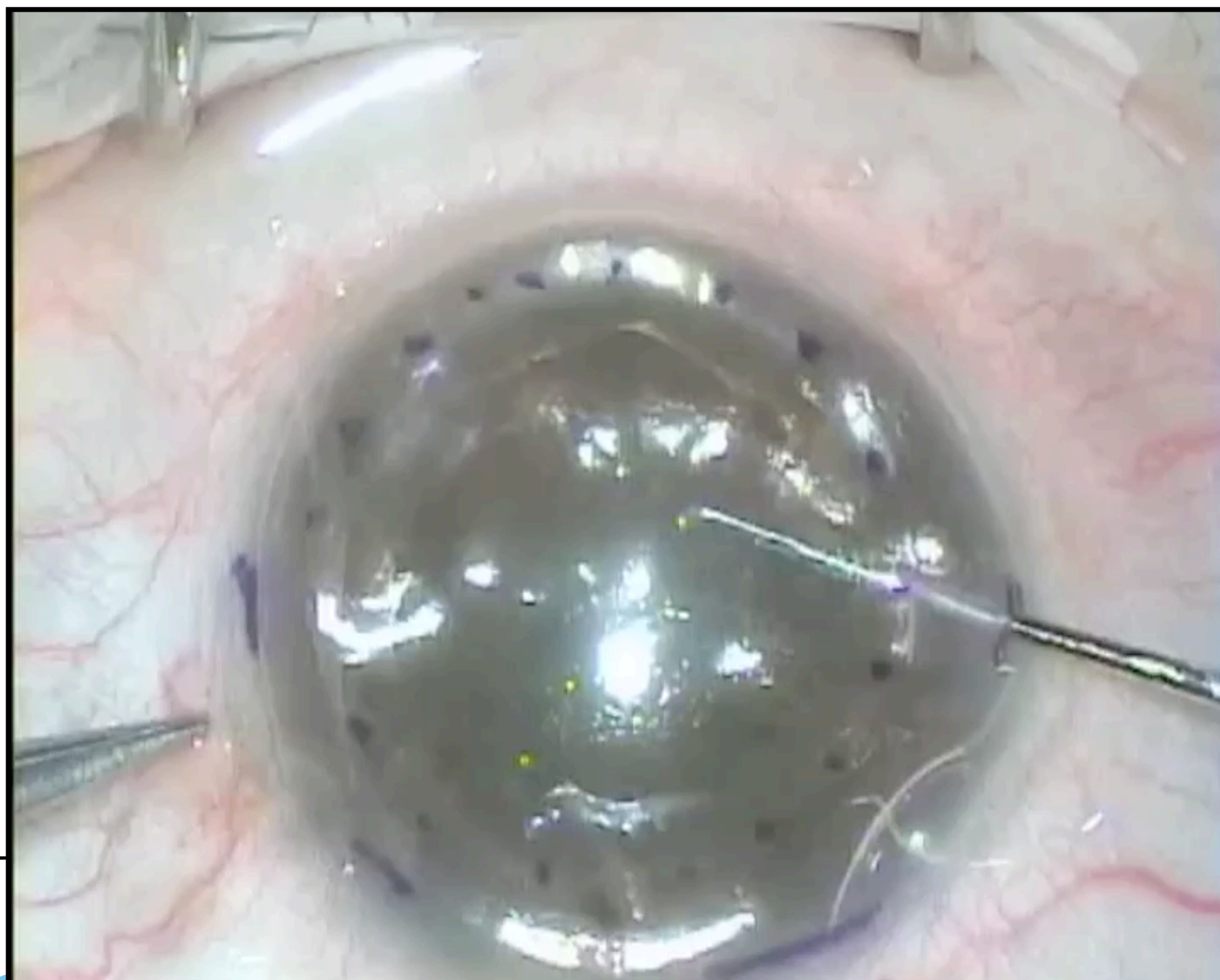
AIR

Excellent Visibility

C. DM-Rhexis

**Cohesive
Viscoelastic**

AC Stability



Recipient Preparation

T. Katamish, Cairo university

- Reversed Sinsky hook

- Scoring D.M.

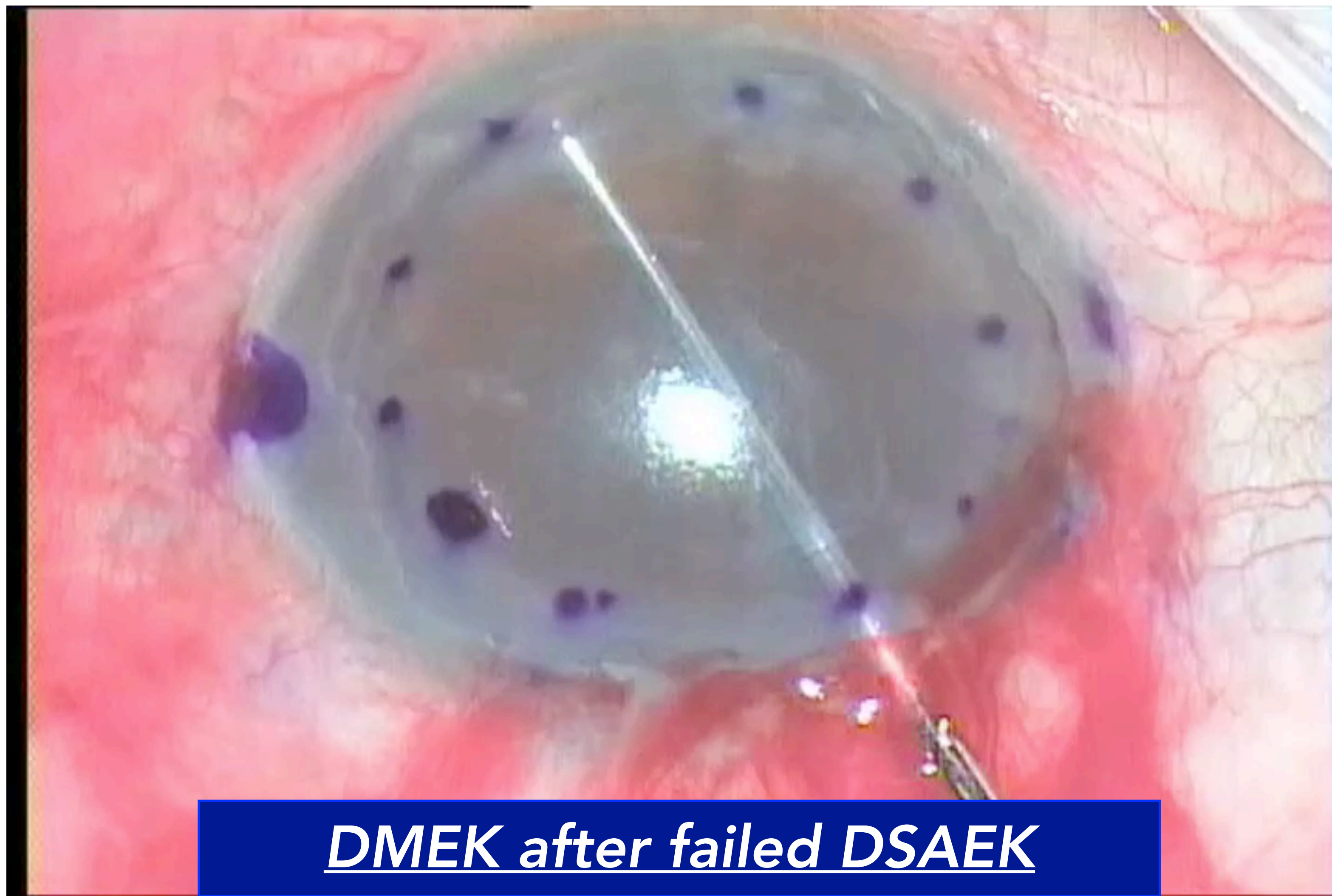- Striping D.M.

- Ensure complete stripping of D.M.

DM-Rhexsis



Recipient Preparation



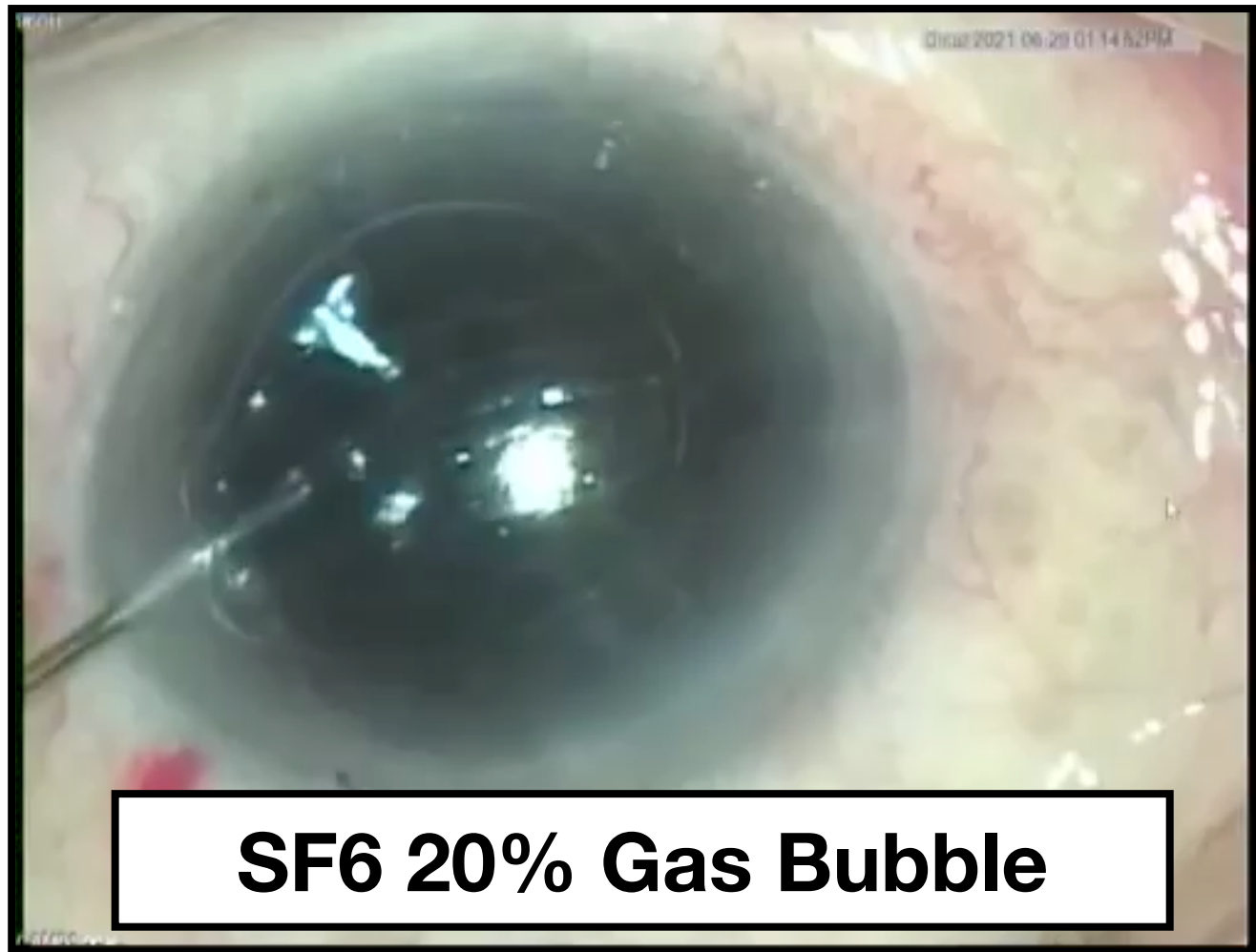
DMEK after failed DSAEK



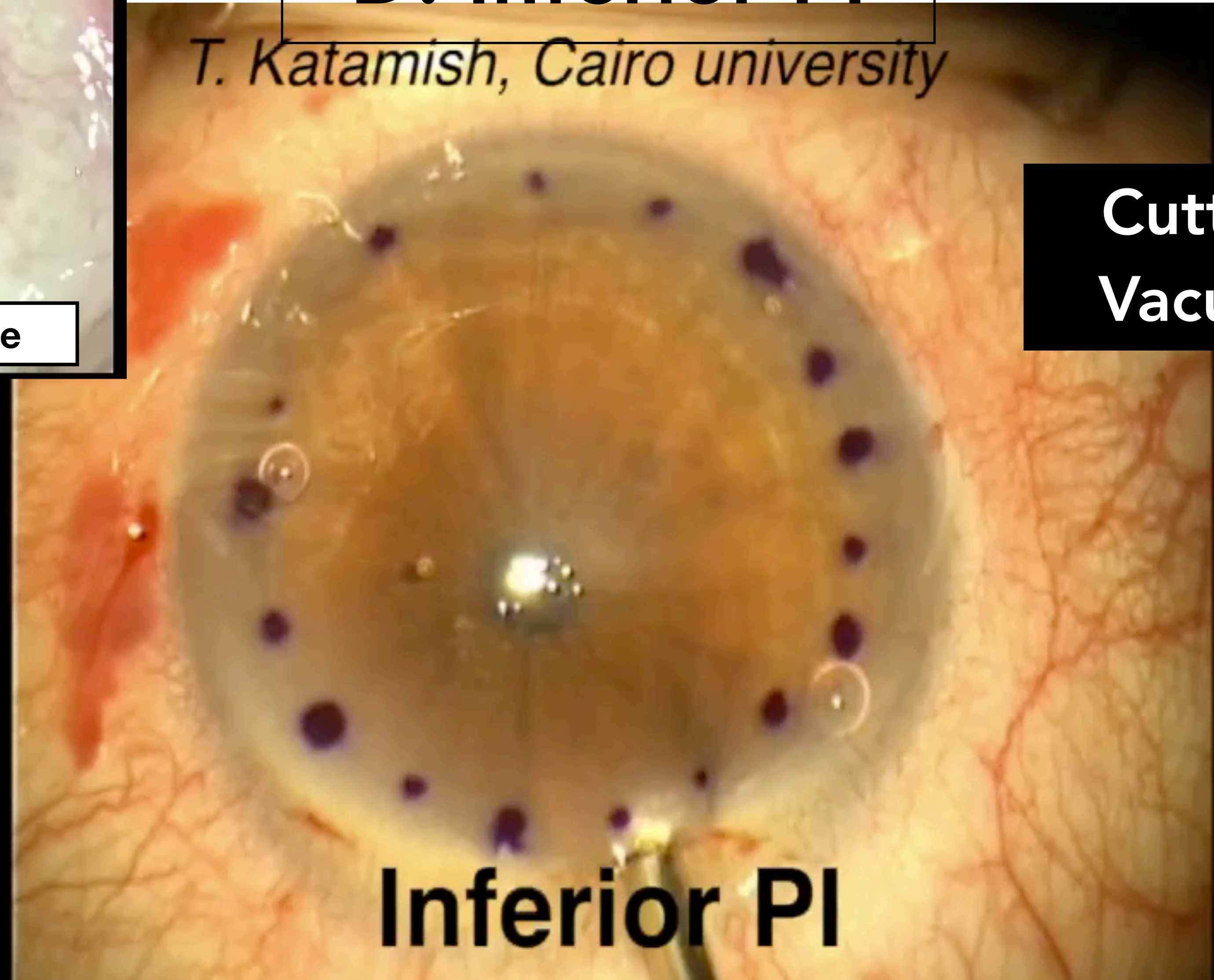
Recipient Preparation

D. Inferior PI

T. Katamish, Cairo university



Cutting Rate: 100
Vacuum: 250



Recipient Preparation

- Be Patient ...
- Make PERFECT Homeostasis ...
- Blood & Fibrin are Enemies to DMEK ROLL unfolding ...

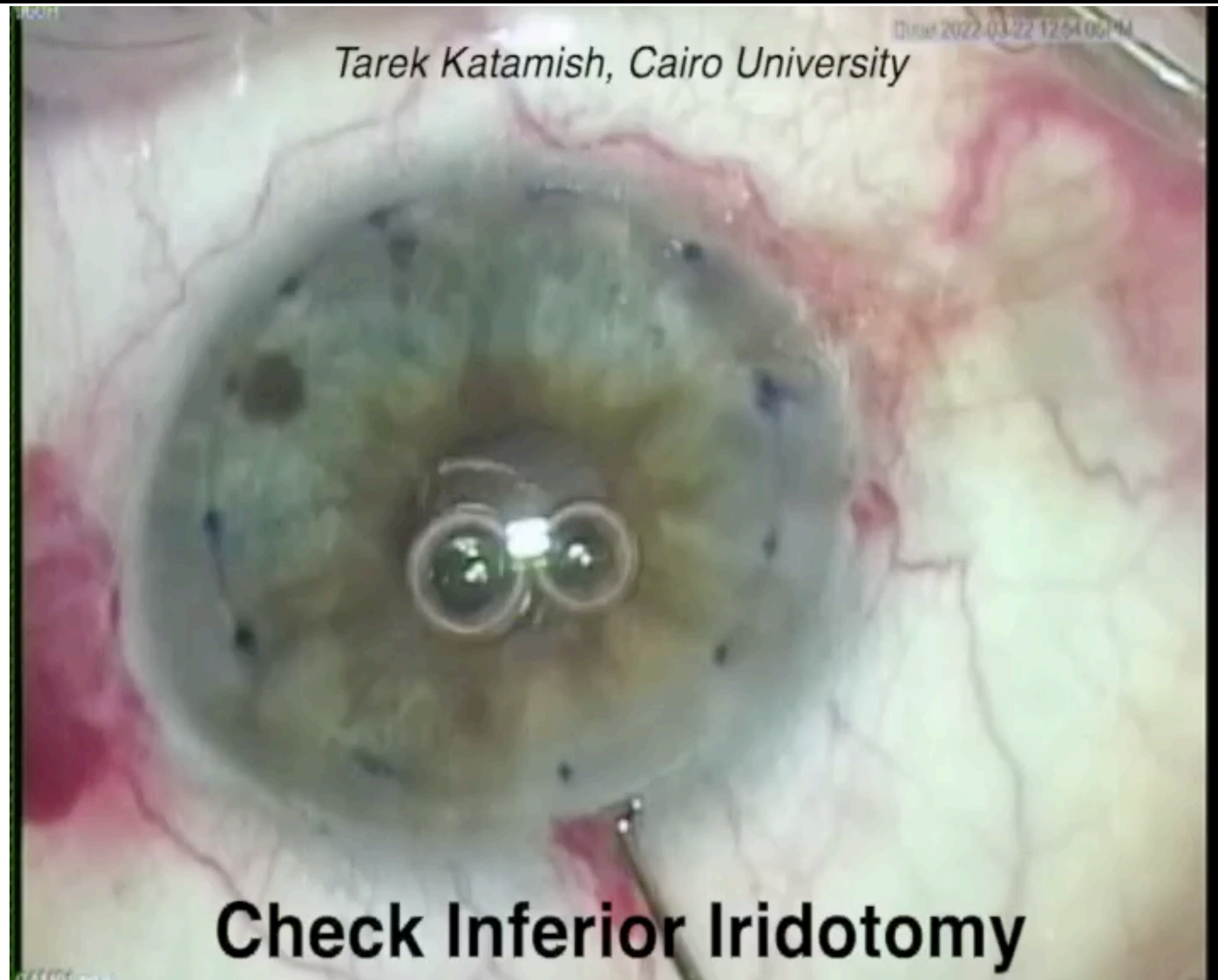
SF6 20% Gas Bu

DMEK
Inferio

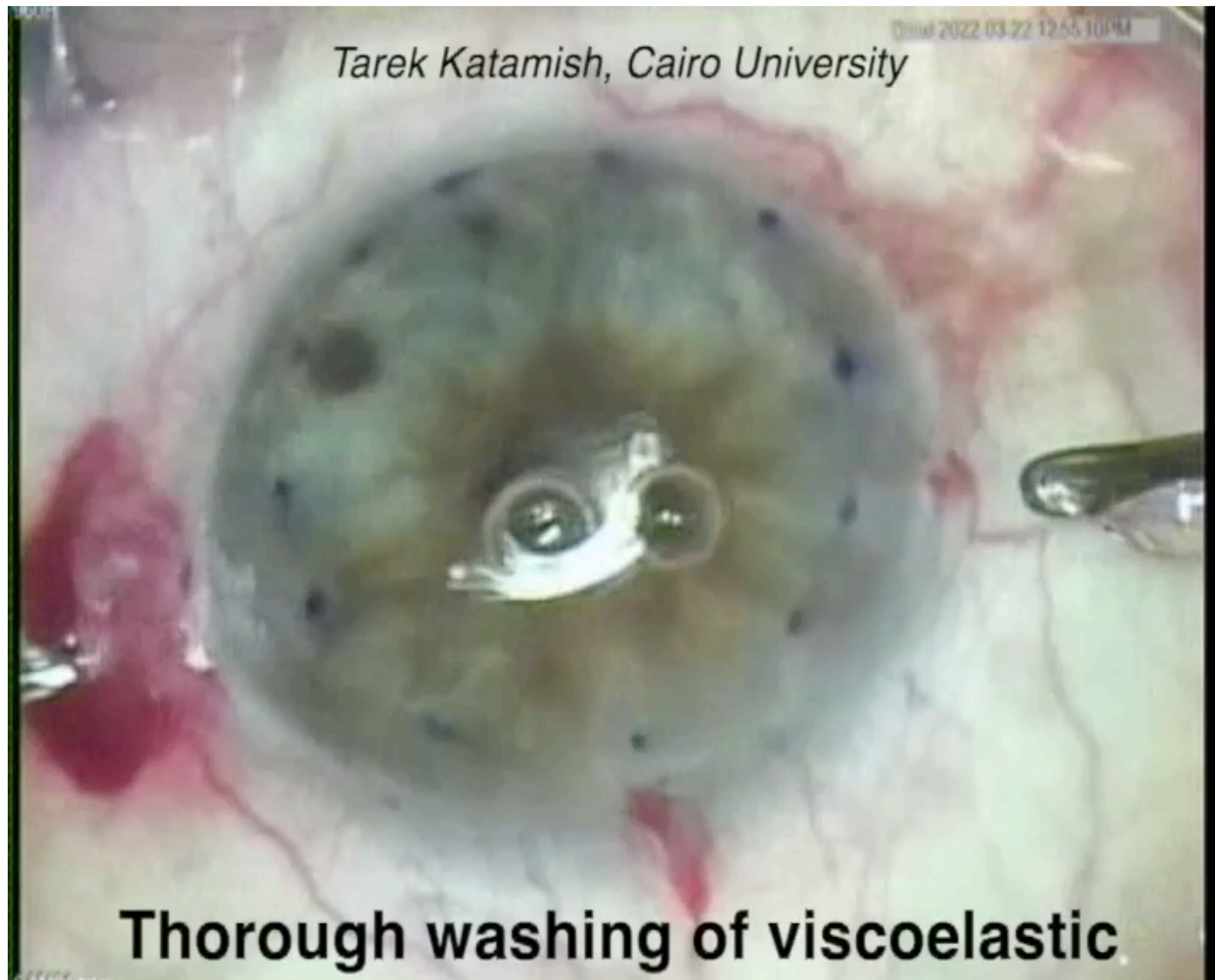BLEEDING



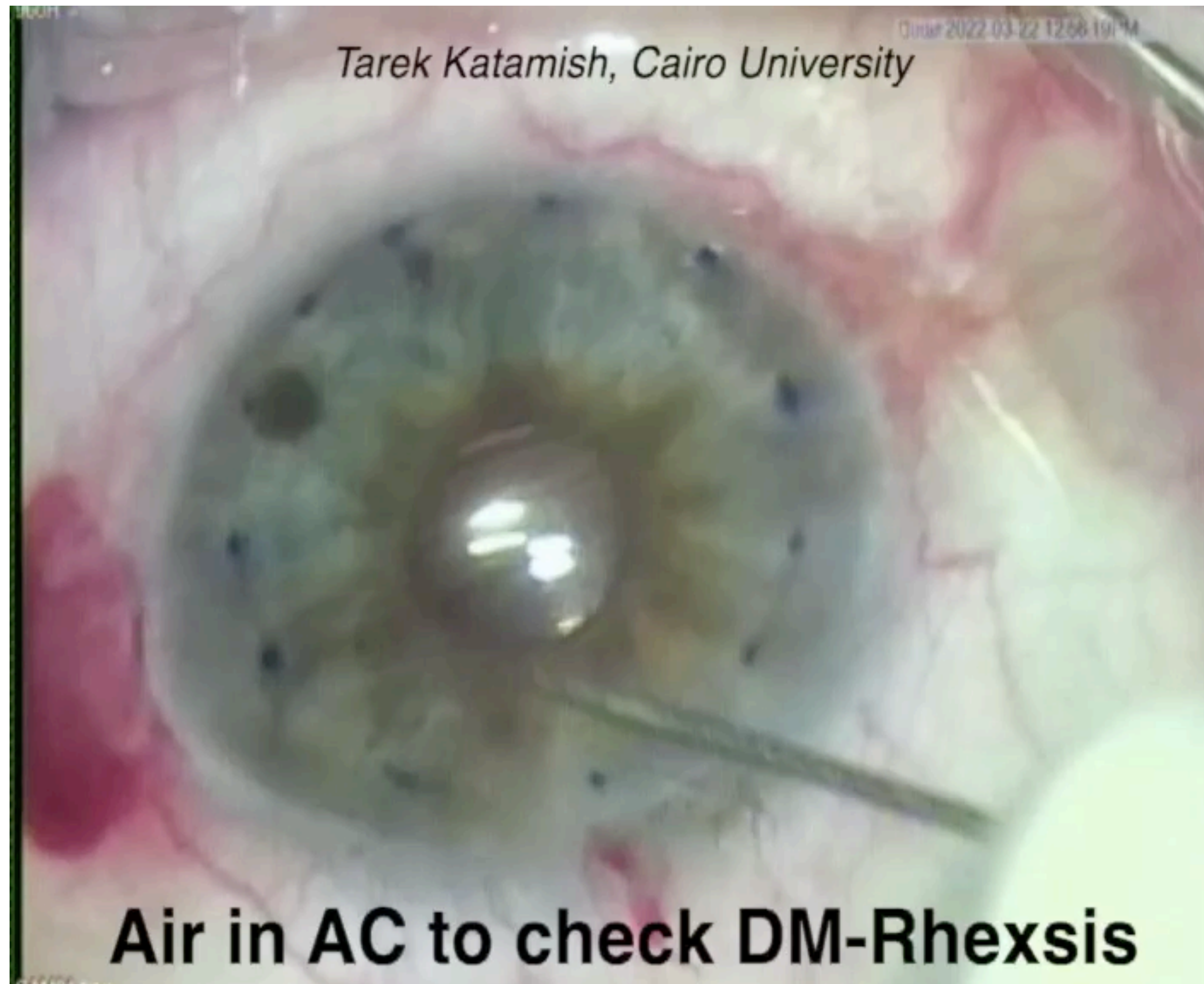Recipient Preparation



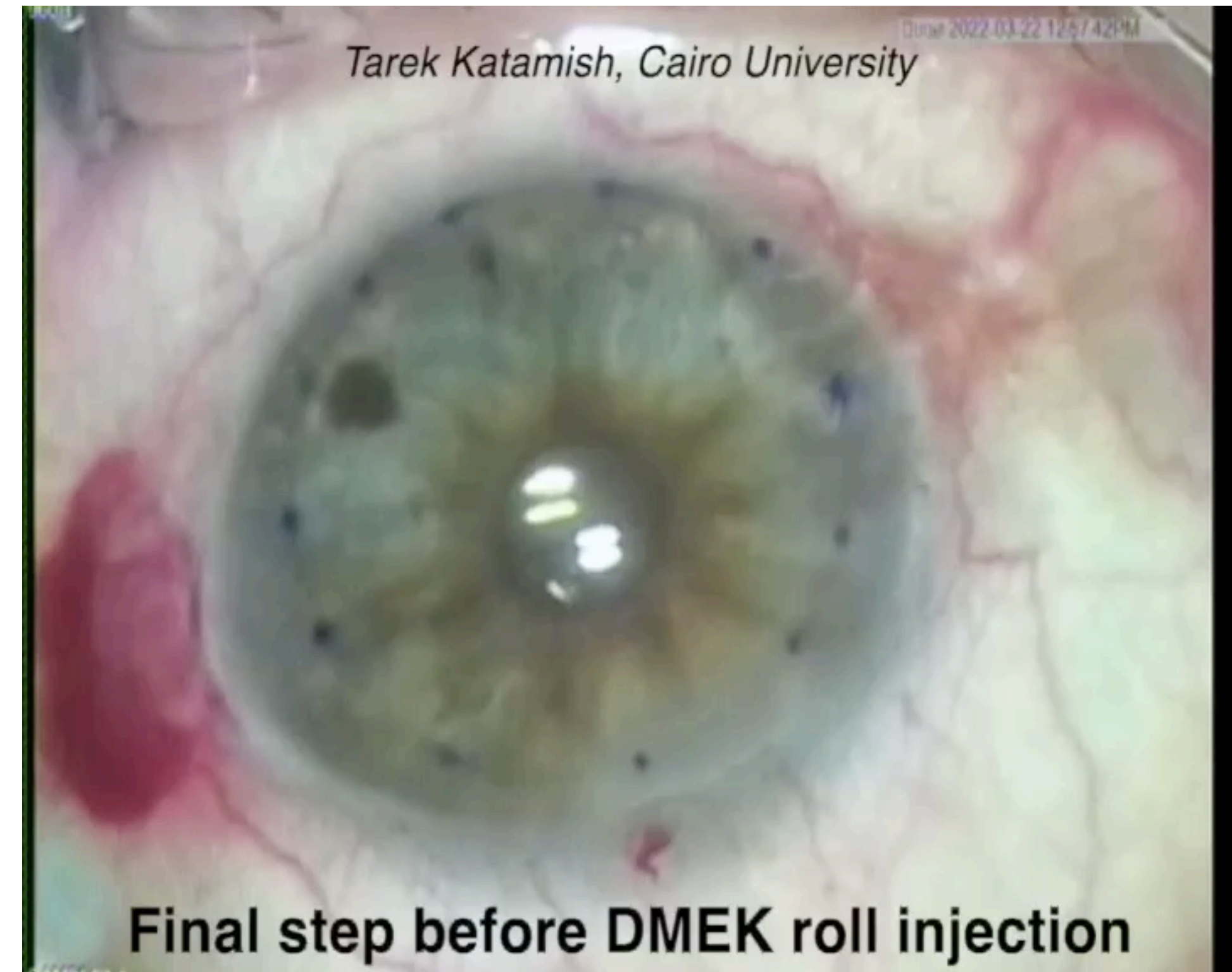
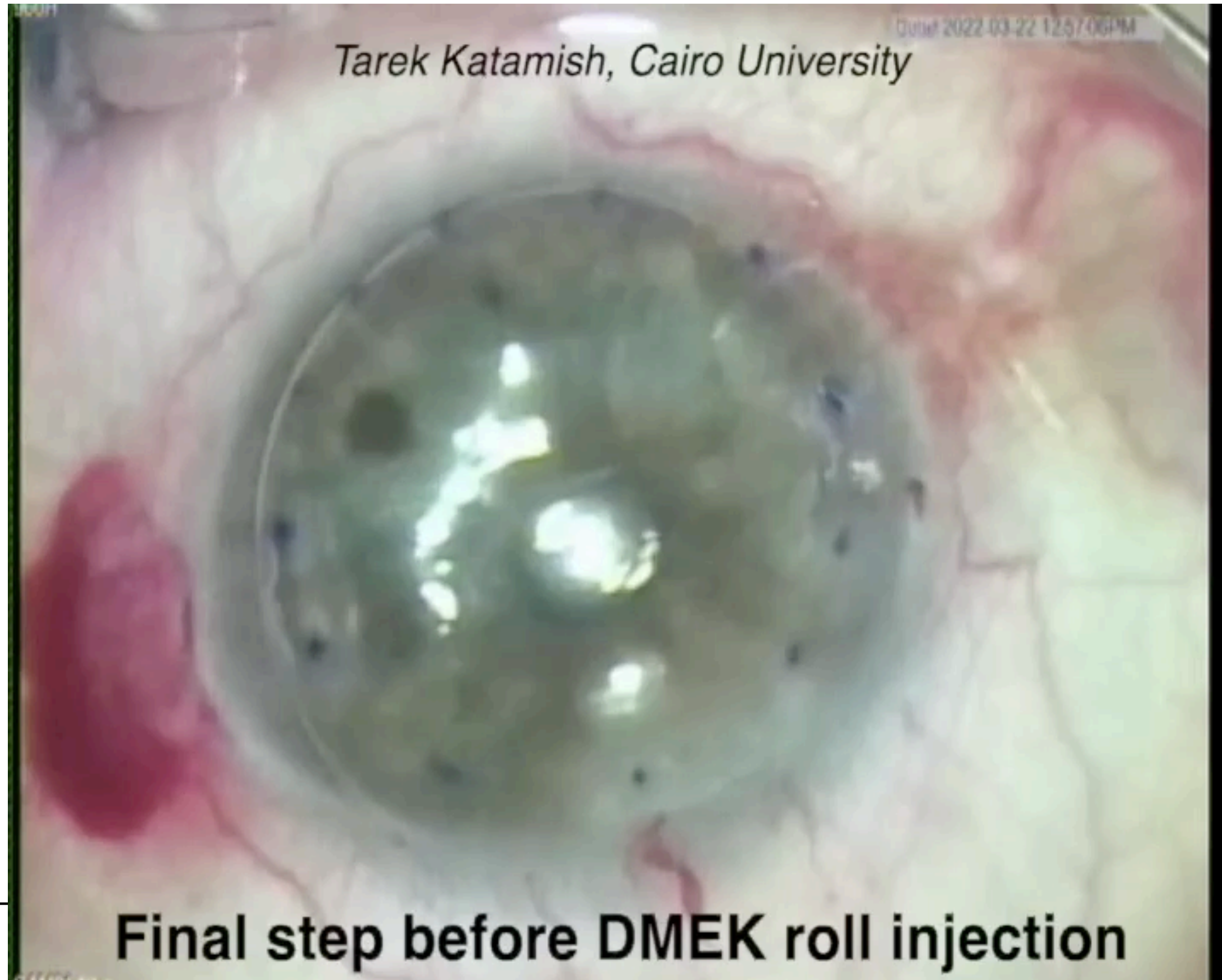
Recipient Preparation



Recipient Preparation



Recipient Preparation





THANK YOU

See you next year

المؤتمر السنوي الدولي للجمعية الرمدية المصرية
INTERNATIONAL CONGRESS OF THE

**EGYPTIAN
OPHTHALMOLOGICAL SOCIETY**

EOS 2024

24-26 APRIL 2024

InterContinental Citystars, Cairo, Egypt

