

المؤتمر السنوي الدولي للجمعية الزيمية المصرية
INTERNATIONAL CONGRESS OF THE
EGYPTIAN OPHTHALMOLOGICAL SOCIETY

EOS 2023

since 1902

**OCT biomarkers
in
Uveitis**

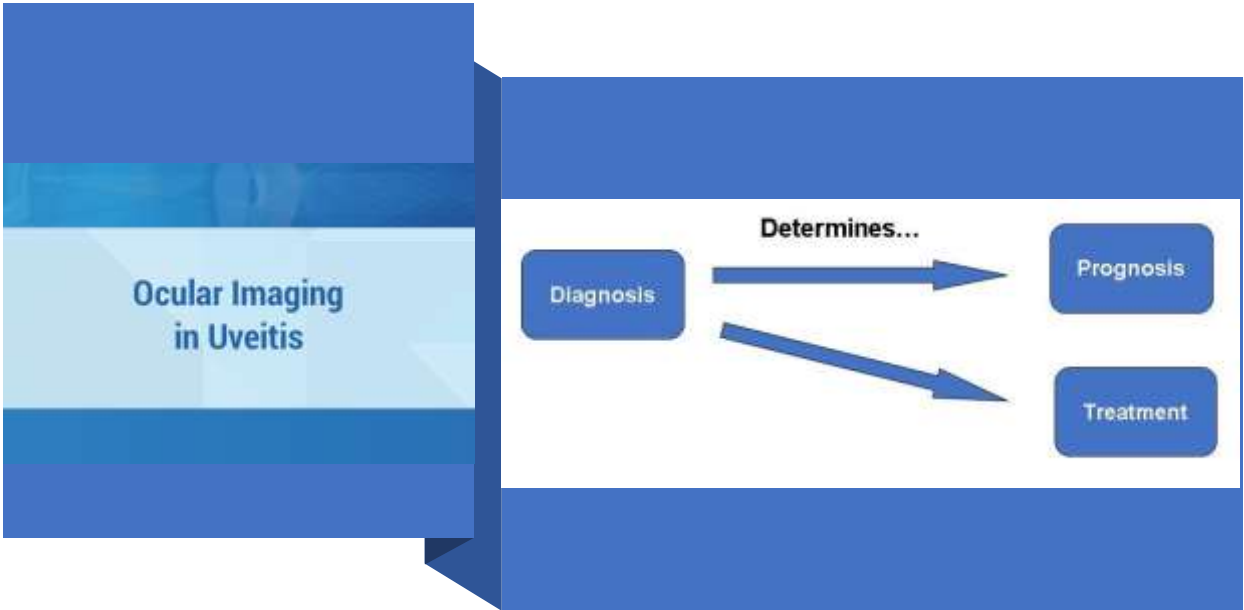
Mohamed Ahmed ELShafie
MD, HMS alumni



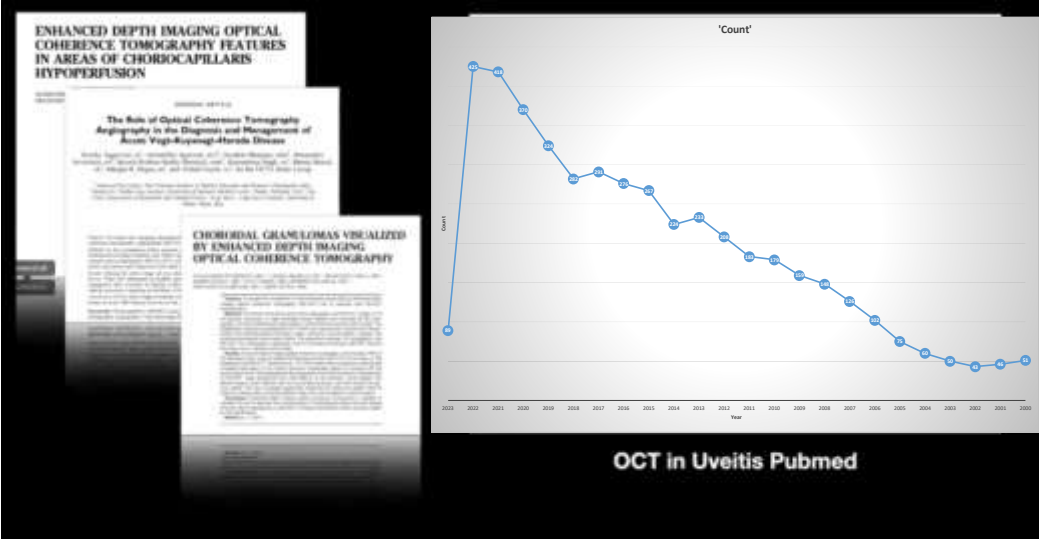

Uveitis assessment is complex

- Heterogeneity across the different uveitic phenotypes.
- Fluctuations with disease severity and flares.





The use of OCT in UVEITIS is increasing



What's new?

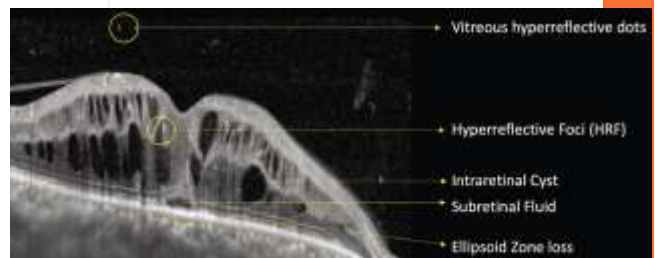
OCT alternative applications

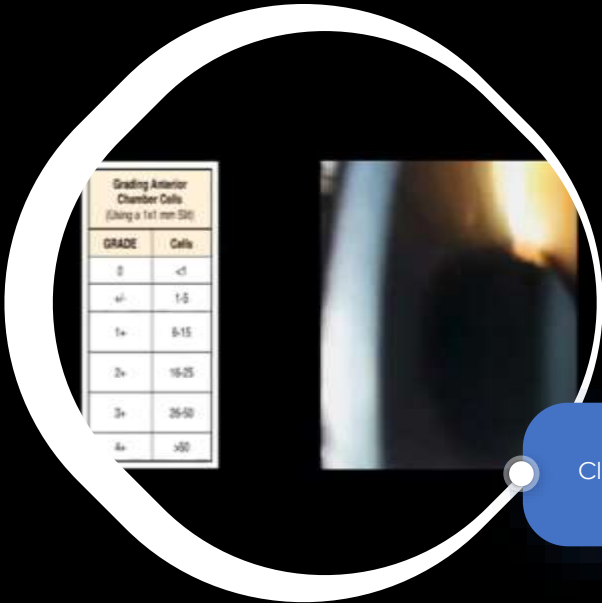
- Inflammation grading
- Differential Diagnosis
- Prognosis/Management
- Follow-up and Response to therapy



Ideal biomarker for uveitis

- reliable.
- noninvasive.
- easy to acquire in routine clinical practice.
- large clinical databases available for validation

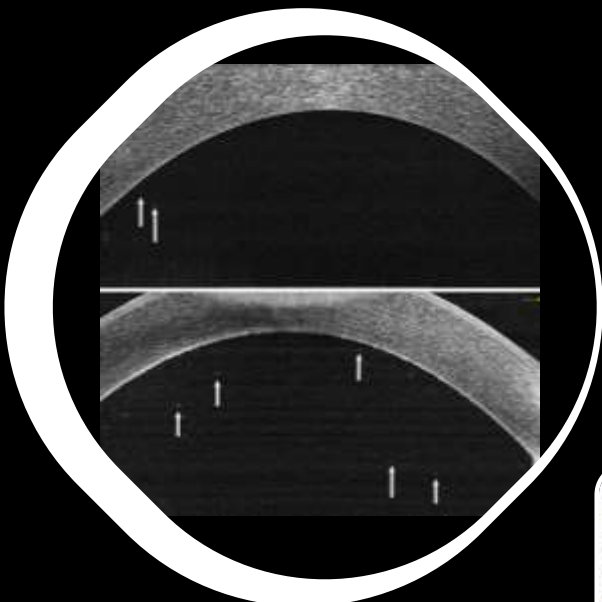




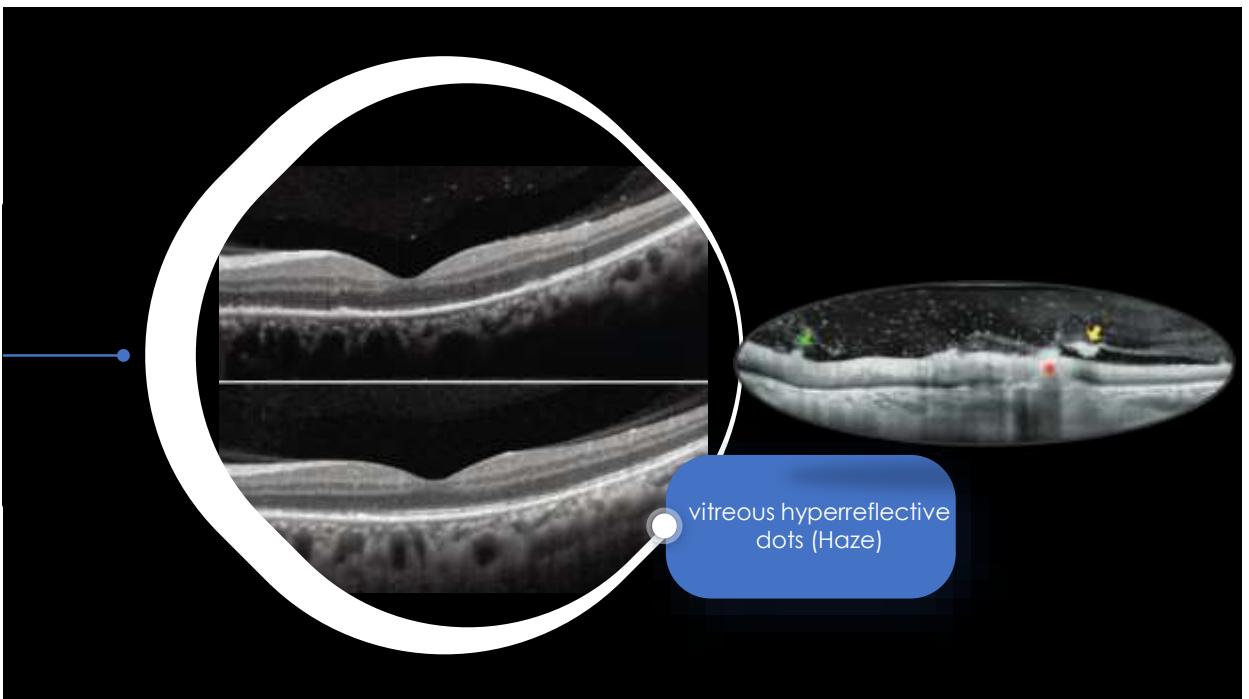
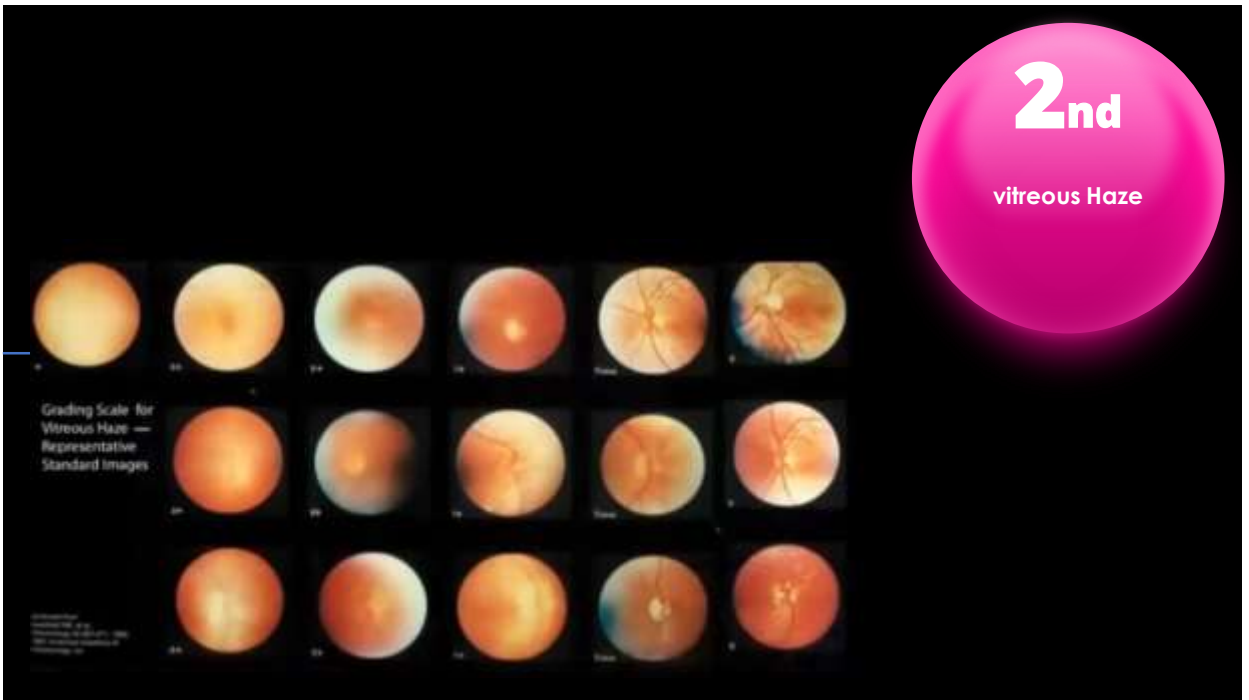
1ST
Anterior chamber cells


Grading Anterior Chamber Cells (Using a 1x1 mm slit)	
GRADE	Cells
0	<5
+	1-5
1+	6-15
2+	16-25
3+	26-50
4+	>50

Clinical Grading



Objective Quantification of Anterior Chamber Inflammation
Measuring Cells and Flare by Anterior Segment Optical Coherence Tomography





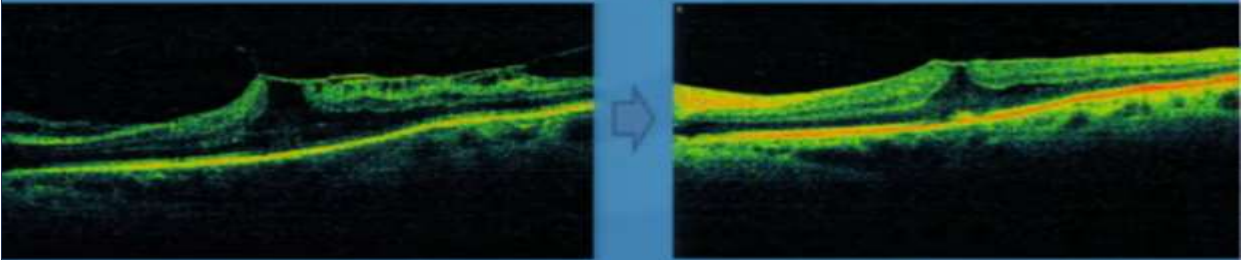
3rd
Vitreomacular interface

ERM thickness increase with uveitis duration

In most eyes with uveitis and ERM, VA remains stable if ocular inflammation and comorbidities are addressed appropriately.

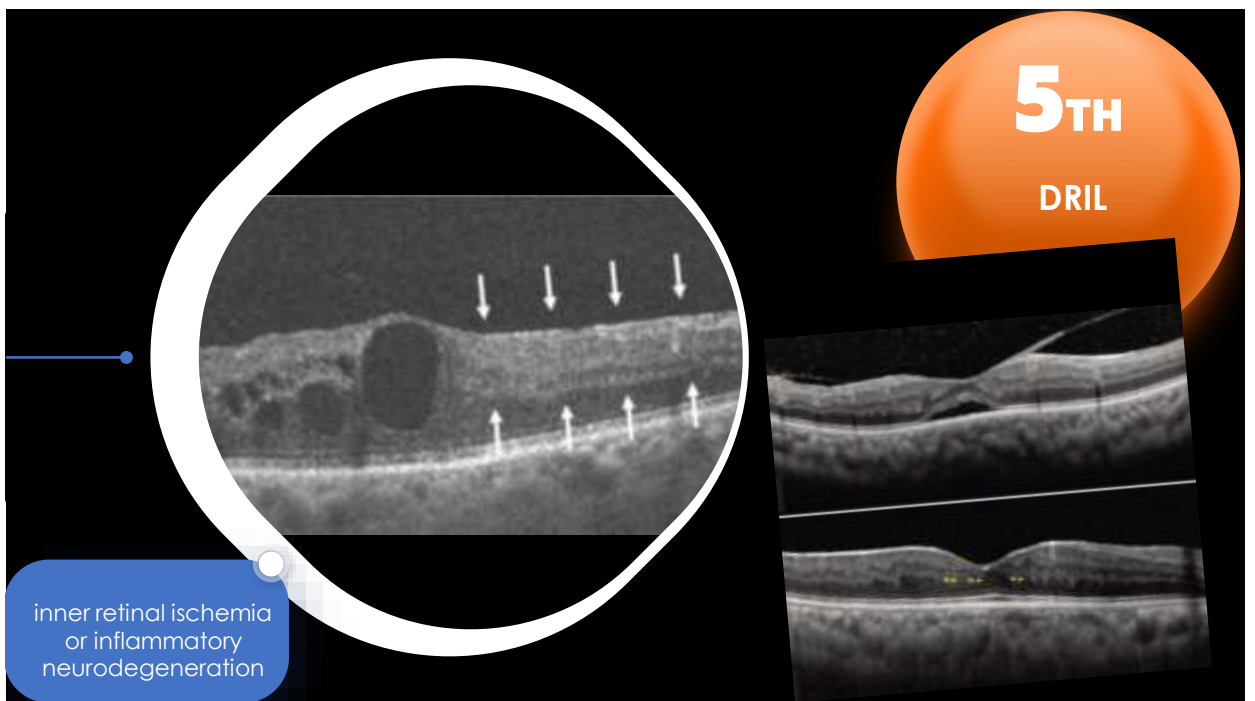
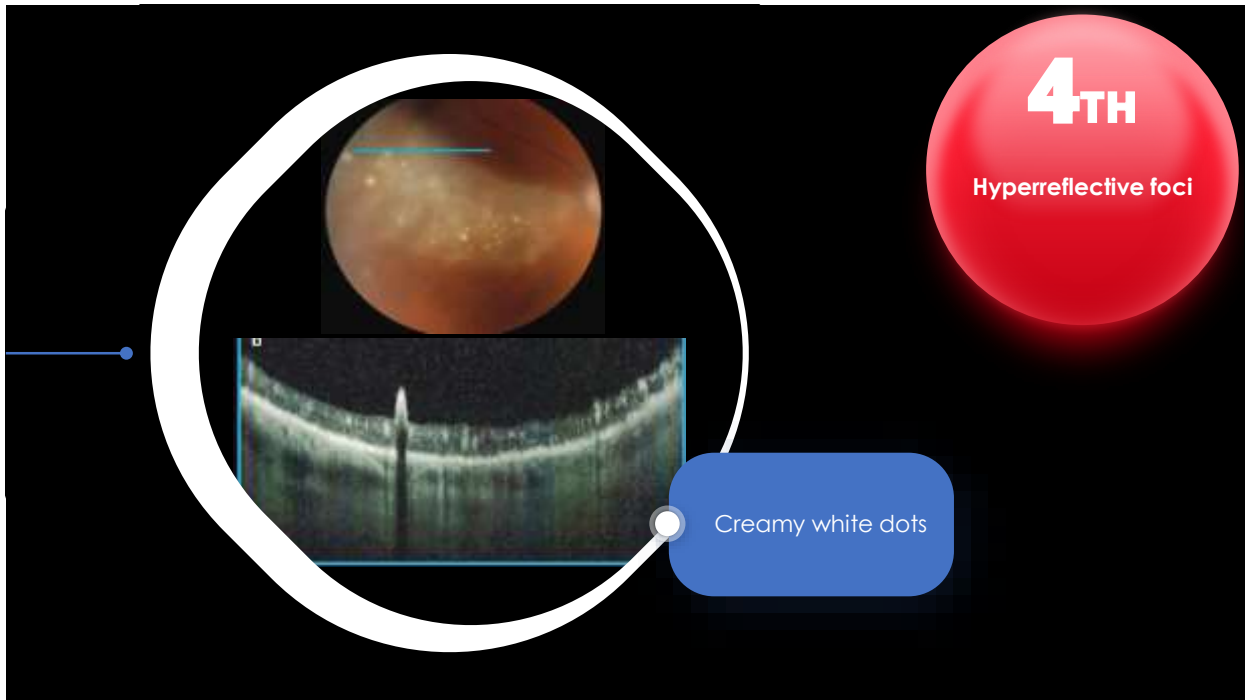
The image displays four OCT scans in a 2x2 grid. The top row shows a normal vitreomacular interface with a clear vitreous space. The bottom row shows a vitreomacular traction (VMT) with a thickened vitreous layer pulling on the macula. A red circle highlights the text '3rd Vitreomacular interface'. A blue rounded rectangle contains the text 'ERM thickness increase with uveitis duration'. A red caption at the bottom states: 'In most eyes with uveitis and ERM, VA remains stable if ocular inflammation and comorbidities are addressed appropriately.'

V-shaped VMT (A-P) + ERM



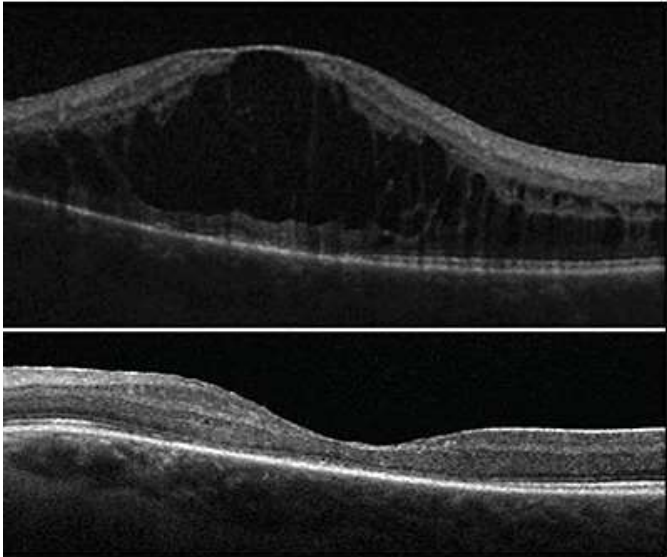
EOS 2023

The image shows two OCT scans side-by-side, separated by a blue arrow pointing right. The left scan shows a V-shaped vitreomacular traction (VMT) with a thickened vitreous layer. The right scan shows a similar V-shaped VMT but with a more pronounced ERM. The text 'V-shaped VMT (A-P) + ERM' is centered above the scans. The EOS 2023 logo is in the bottom right corner.

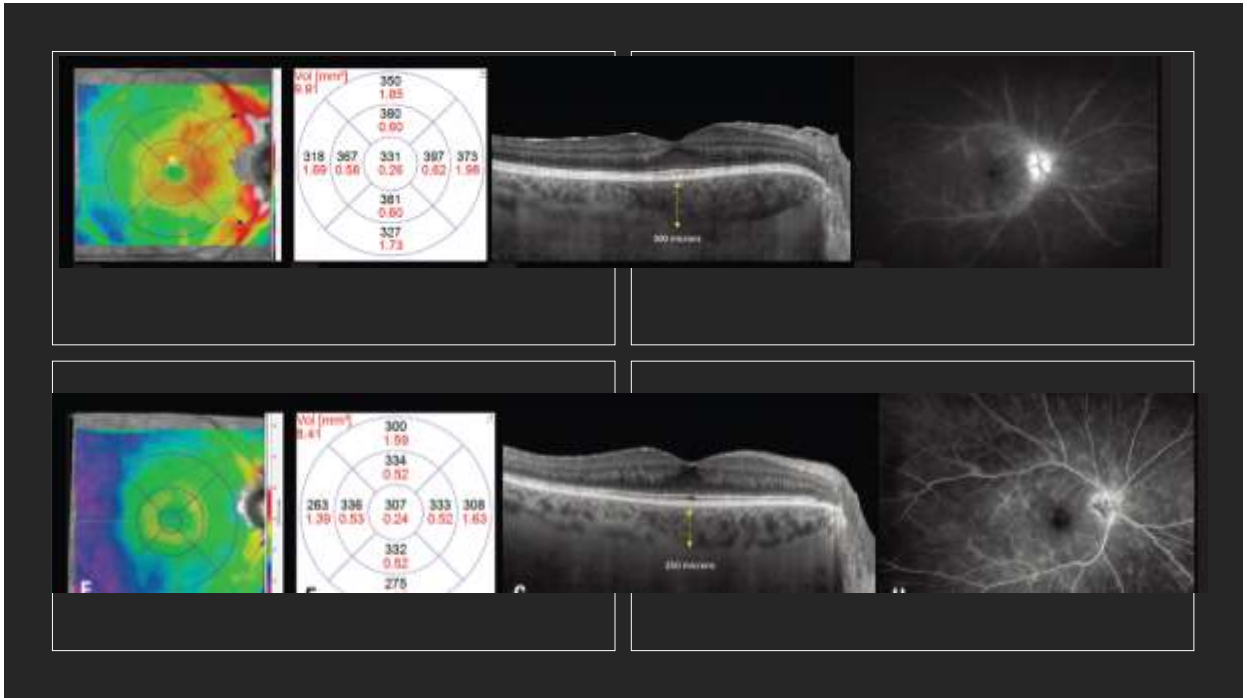




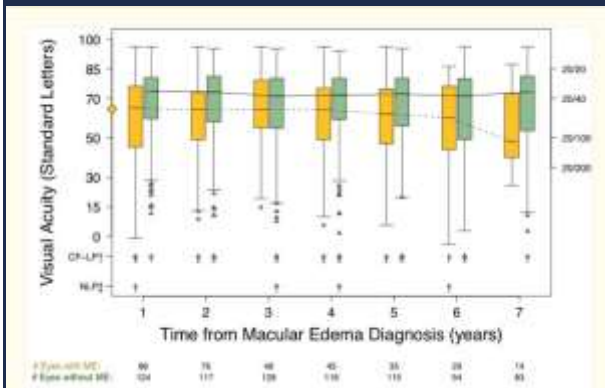
why visual acuity may not fully recover to baseline even after UME resolves.



irreversible disruption of retinal neural network and permanent visual acuity loss

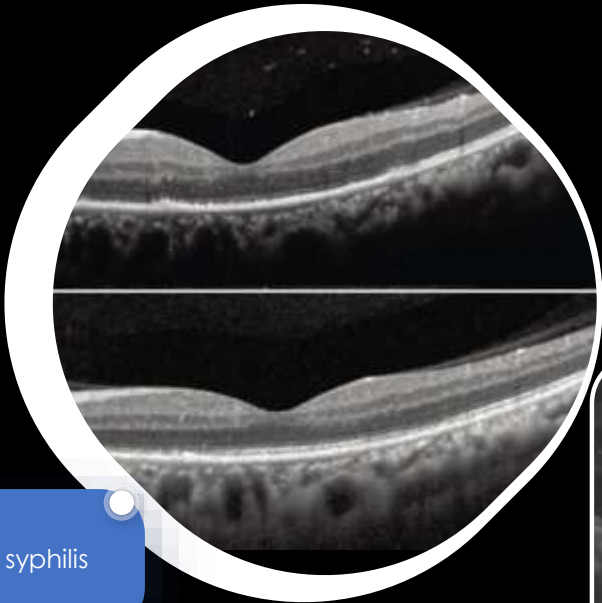


Seven-year outcomes of uveitic macular edema: the Multicenter Uveitis Steroid Treatment (MUST) Trial and Follow-up Study results. Ophthalmology. 2021 May ; 128(5): 719–728



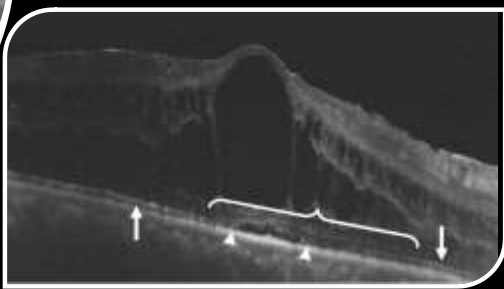
each 100- μ m reduction in CST = 6.5-letter increase in VA
 20-percent reduction in CST should be used as a clinically meaningful improvement in visual acuity



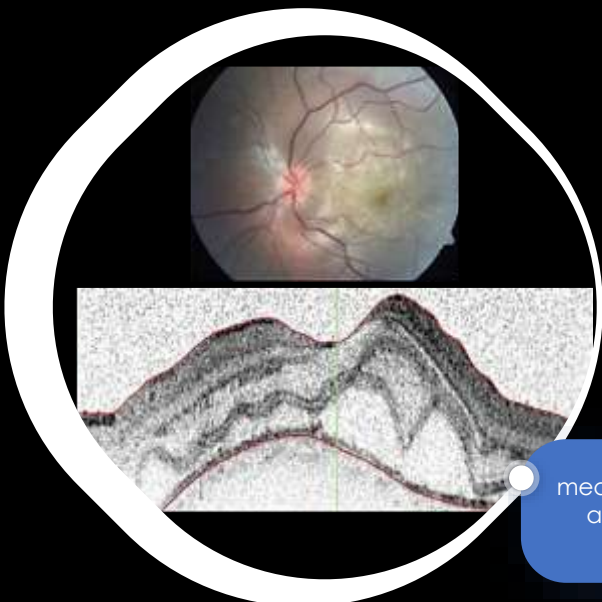


7TH
Integrity of
ellipsoid zone

placoid syphilis

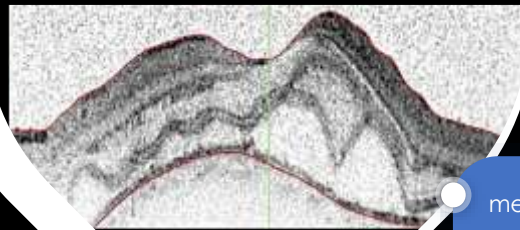


This slide illustrates the OCT findings in placoid syphilis. The main OCT scan shows a normal, well-defined ellipsoid zone, indicating the integrity of this layer. A blue callout box on the left identifies the condition as 'placoid syphilis'. A pink circular graphic on the right is labeled '7TH Integrity of ellipsoid zone'. An inset OCT scan on the right shows a dome-shaped lesion with arrows pointing to the ellipsoid zone, which remains intact despite the overlying lesion.



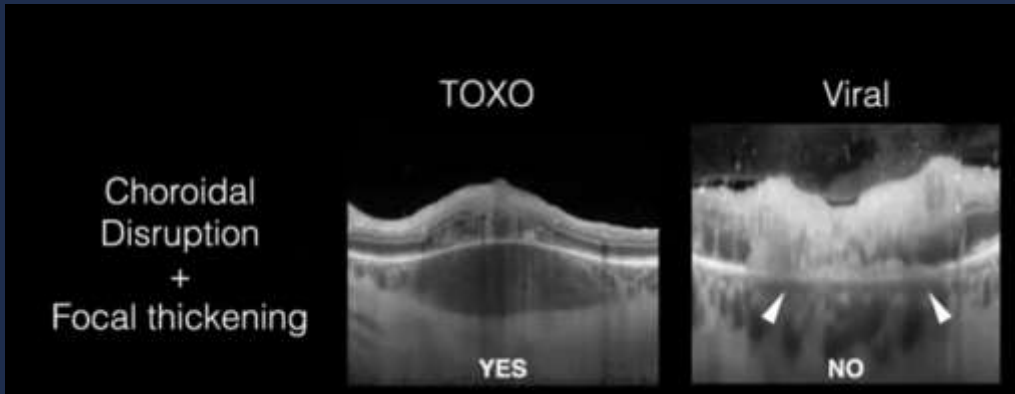8TH
Choroidal
thickness

measurement in the
acute stage of
choroiditis



This slide illustrates the OCT findings in choroiditis. The main OCT scan shows significant thickening of the choroid, with a blue callout box on the right indicating 'measurement in the acute stage of choroiditis'. A pink circular graphic on the right is labeled '8TH Choroidal thickness'. An inset fundus photograph at the top shows a yellowish lesion in the choroid, and an inset OCT scan at the bottom shows the corresponding thickened choroid.

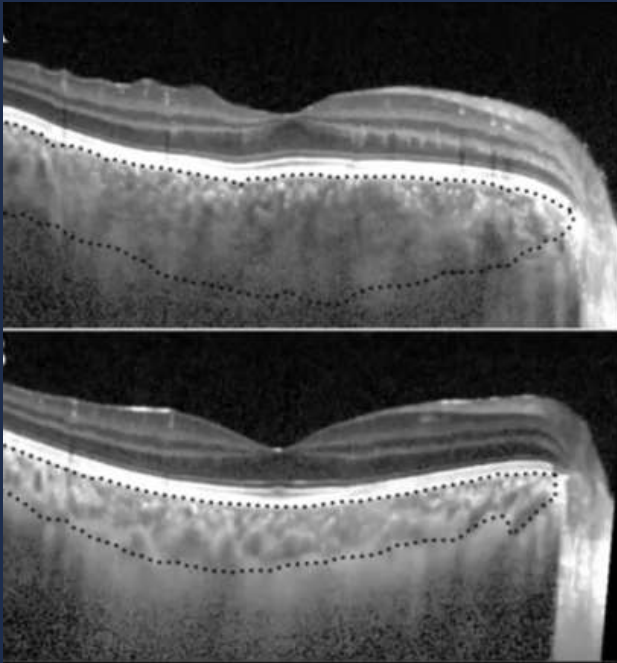
DD



EOS 2023

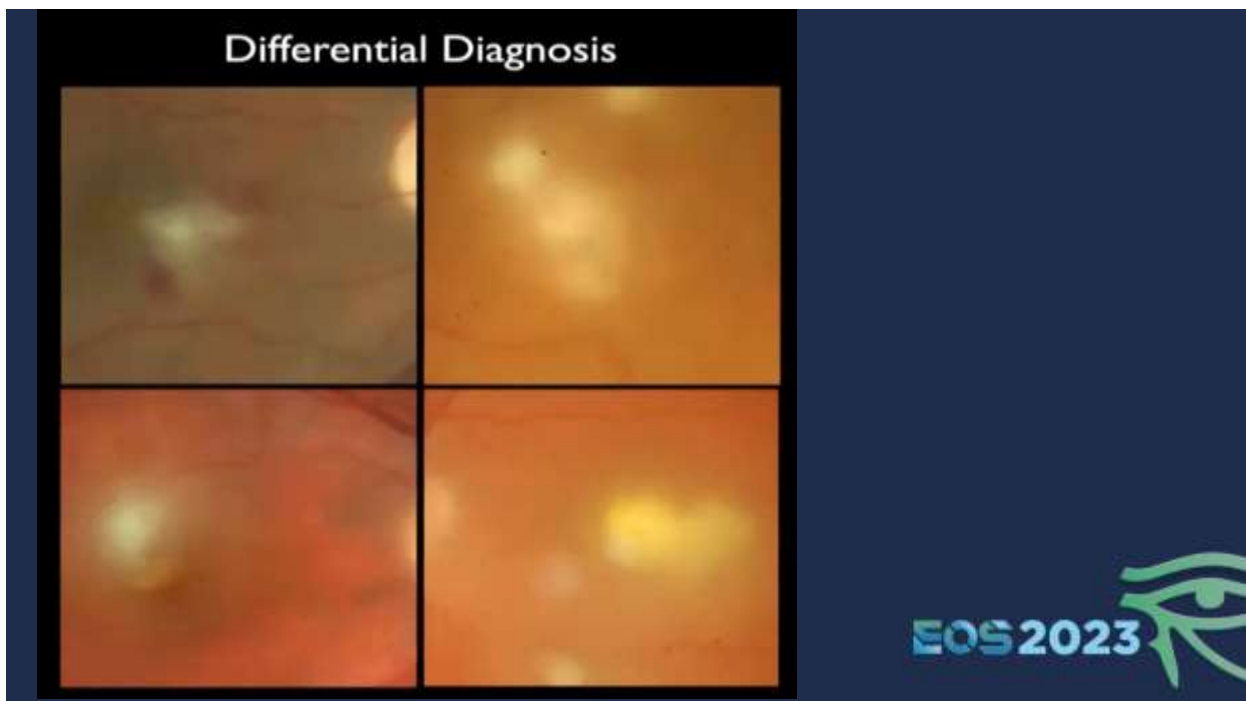
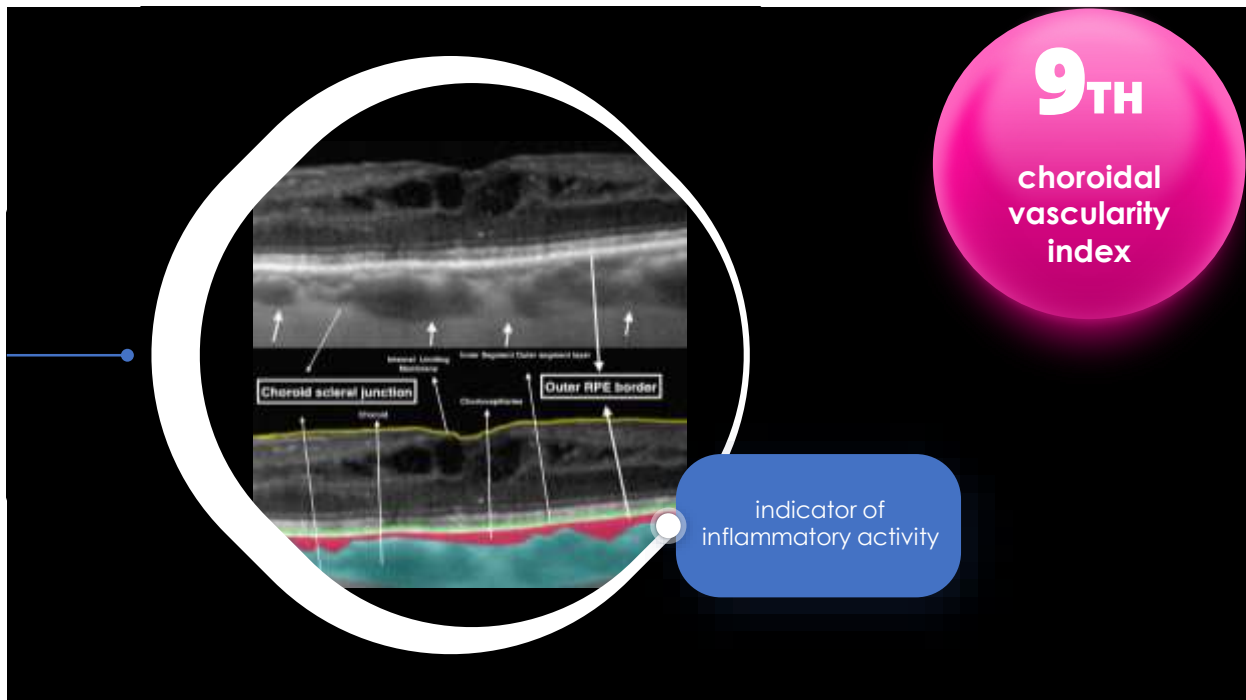






Monitor TTT Response



EOS 2023





	Behcet disease
	Sarcoidosis
	Toxoplasmosis
	Endogenous Candida

EOS 2023 