

المؤتمر السنوي الدولي للجمعية المصرية
INTERNATIONAL CONGRESS OF THE
EGYPTIAN OPHTHALMOLOGICAL SOCIETY
EOS 2023




Inferior Oblique graded recession

Dina Hossam, MD, FRCS
Cairo University

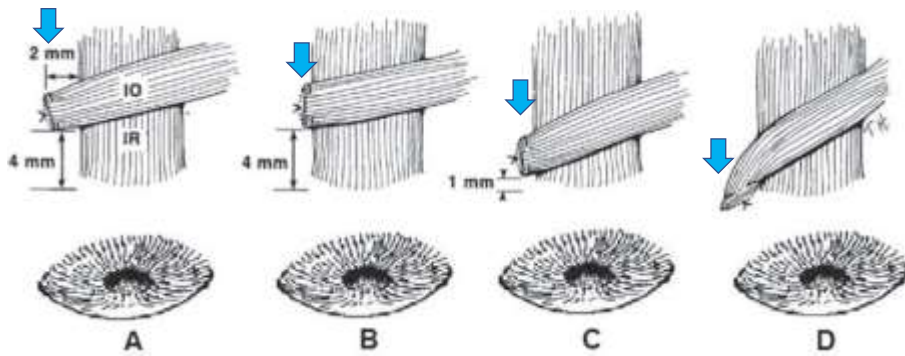


Graded Recession(Anteriorization)





Dina Hossam



Quantification of Surgery

Wright K, Strube Y (2015); Color atlas of strabismus surgery.



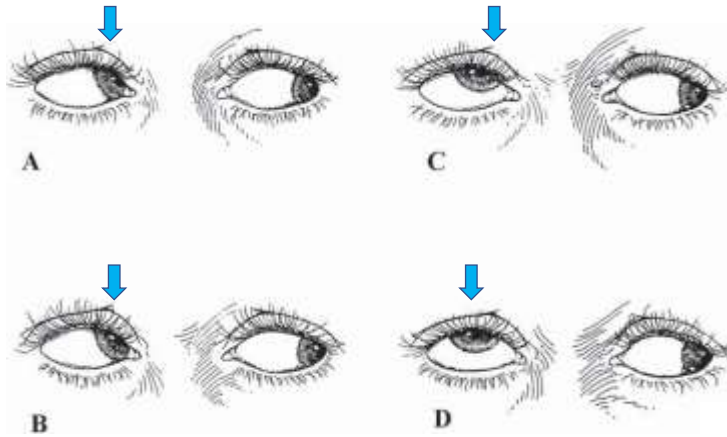
Advantages:

- **Tailored** weakening procedure based on the degree of overaction
- The muscle can be **recovered** again if needed
- **Avoids the uncontrolled local reattachment** after myectomy



Thank you





Inferior Oblique Overaction

Wright K, Strube Y (2015); Color atlas of strabismus surgery.



Primary IOOA commonly develops in:

- Infantile esotropia (often after surgical treatment of the original horizontal strabismus) **70%**
- Accommodative esotropia **>30%**
- Intermittent exotropia. **>30%**



Wilson ME, Parks MM. Ophthalmology. 1989



Other less common indications:

- Superior oblique palsy
- Duane syndrome with up-shoot
- Cases where the inferior rectus muscle was severed or lost
- Similarly inferior rectus aplasia and these patients benefit from anterior transposition

