


المؤتمر السنوي الدولي للجمعية المصرية  
INTERNATIONAL CONGRESS OF THE  
EGYPTIAN OPHTHALMOLOGICAL SOCIETY

**EOS 2023**

since 1902

**Co-existing challenges.  
Plan a head**

Ahmed Mostafa Abdelrahman, MD, FRCSED  
Professor of Ophthalmology, Cairo University  
MEACO Symposium



Case description

---

A 36-year-old male

---

Previous glaucoma operation

---

BCVA 3/60.


---

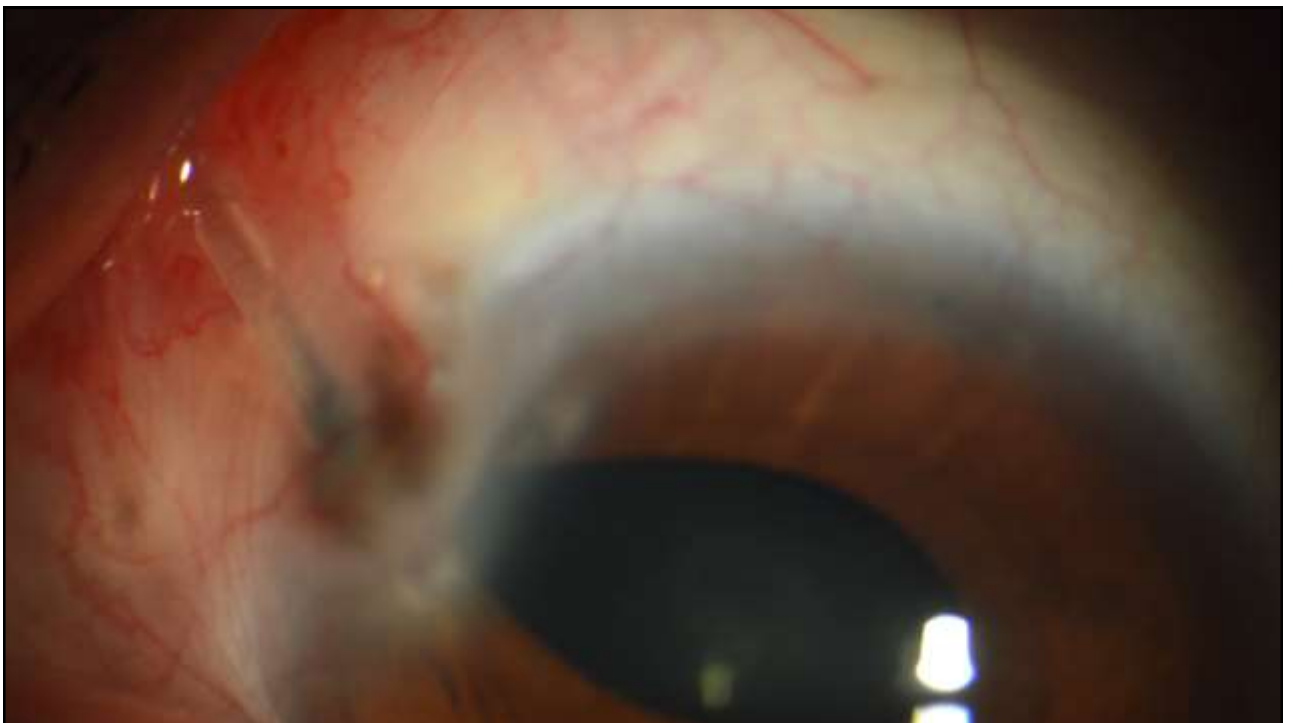
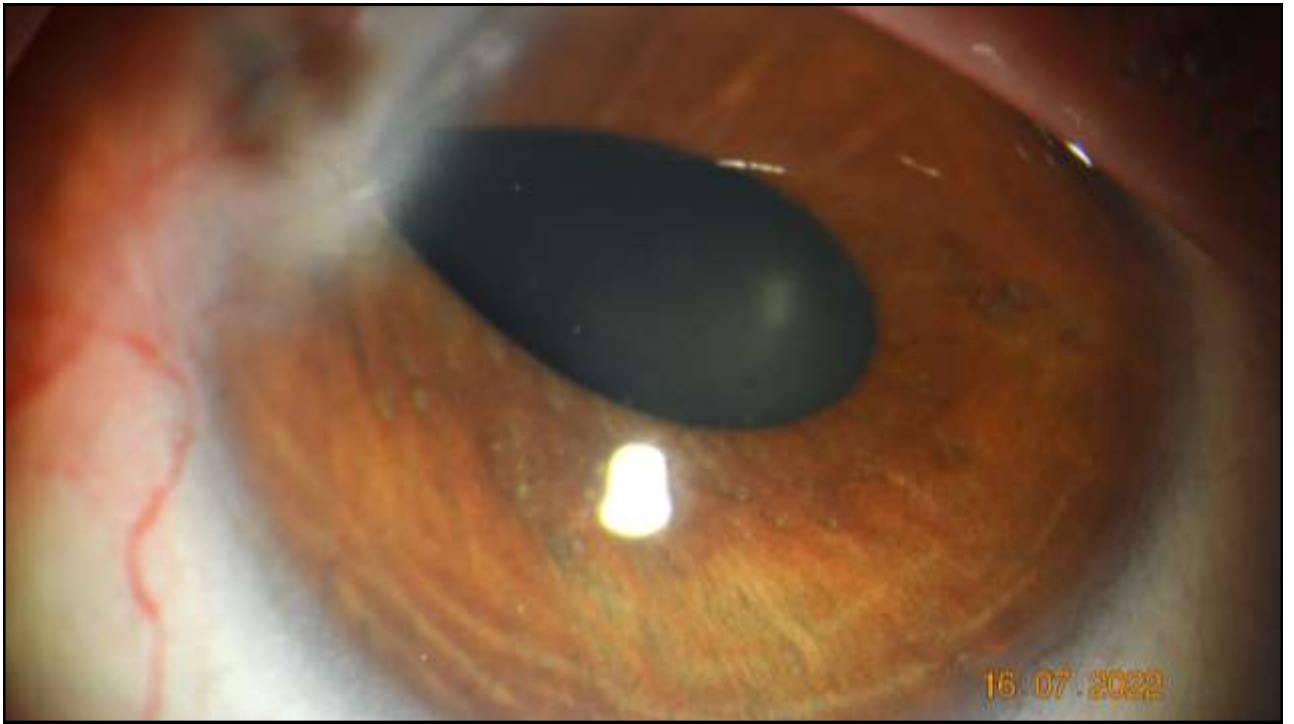IOP : 30 mmHg on full treatment

---

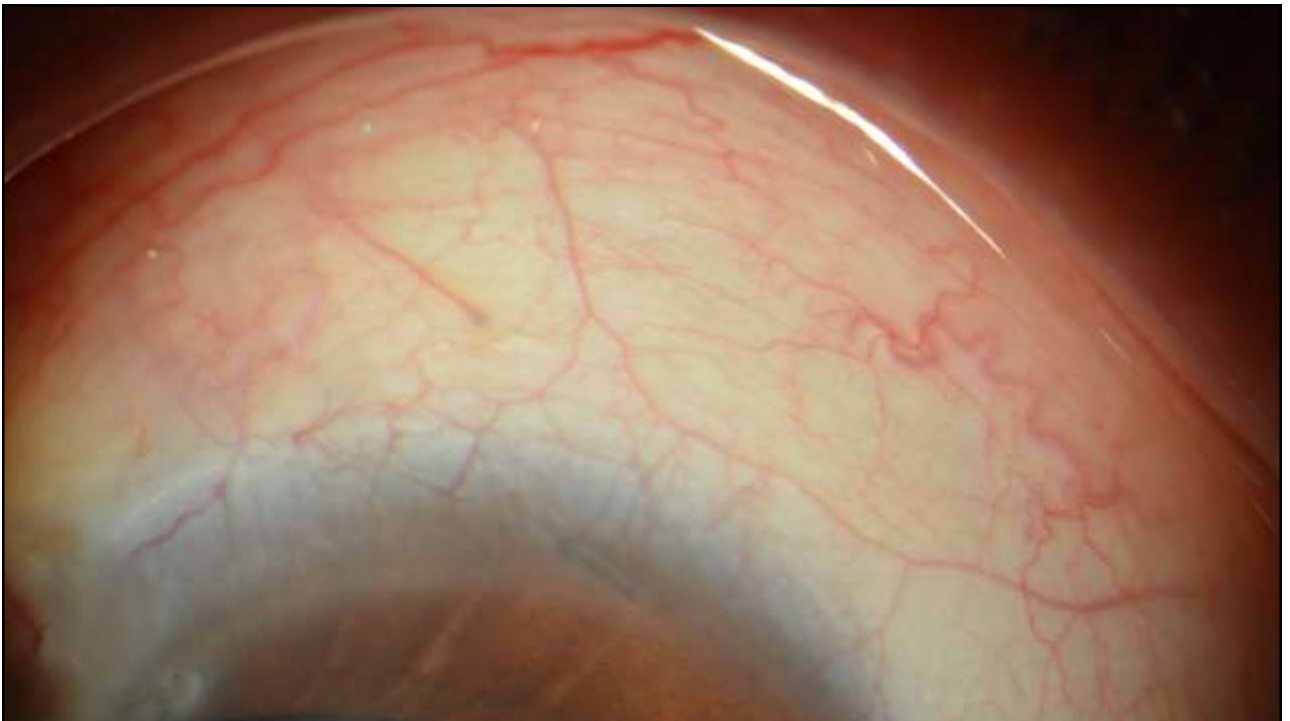C.D seen with difficulty (0.5)

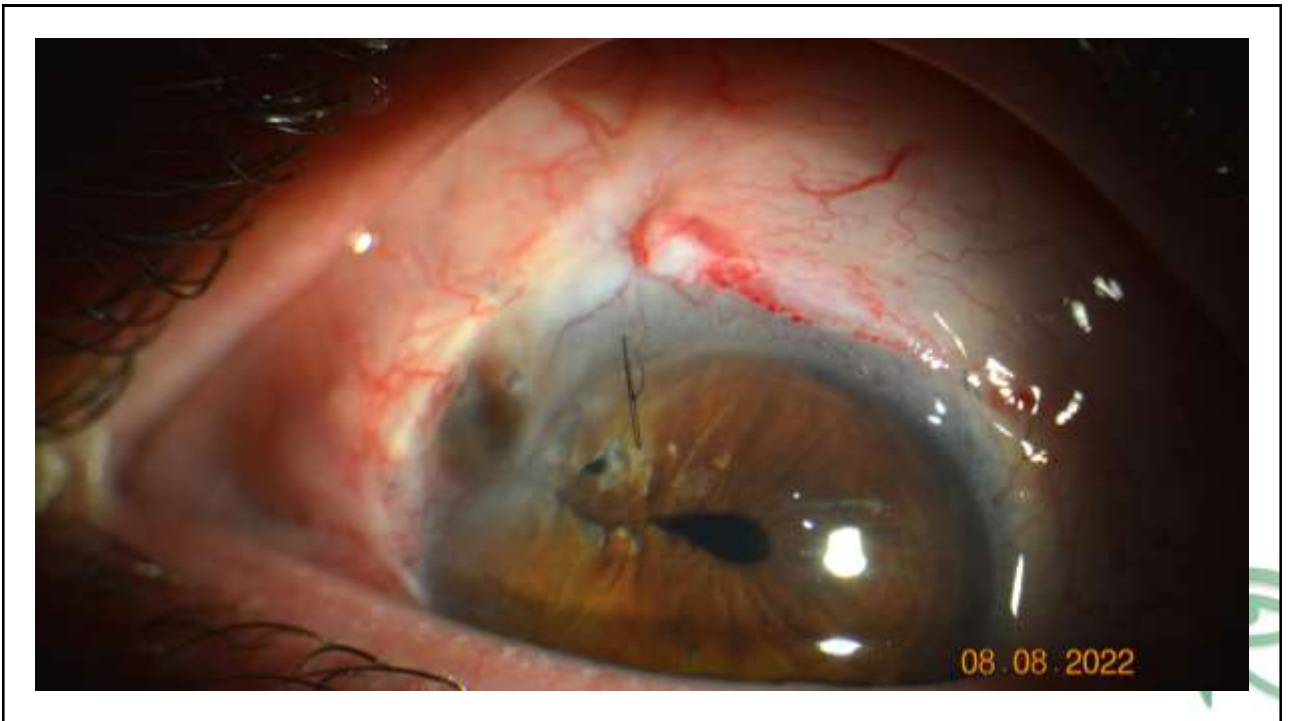
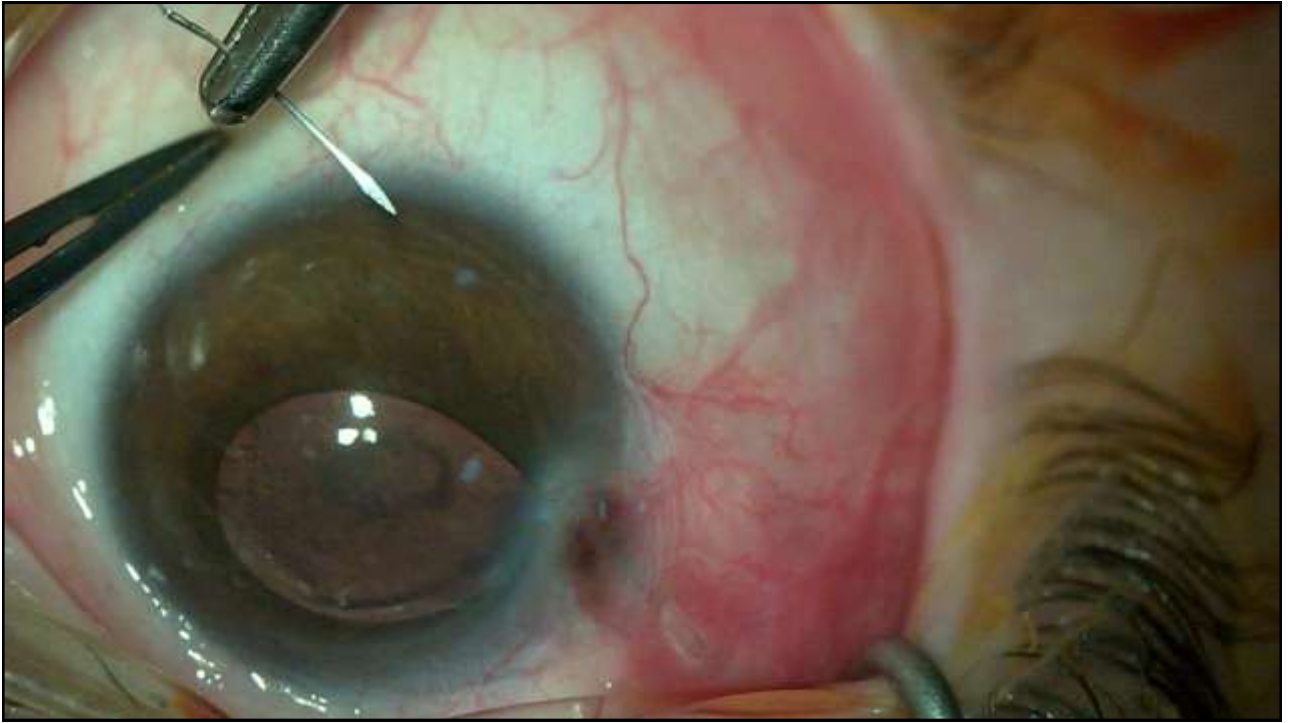
**EOS 2023**

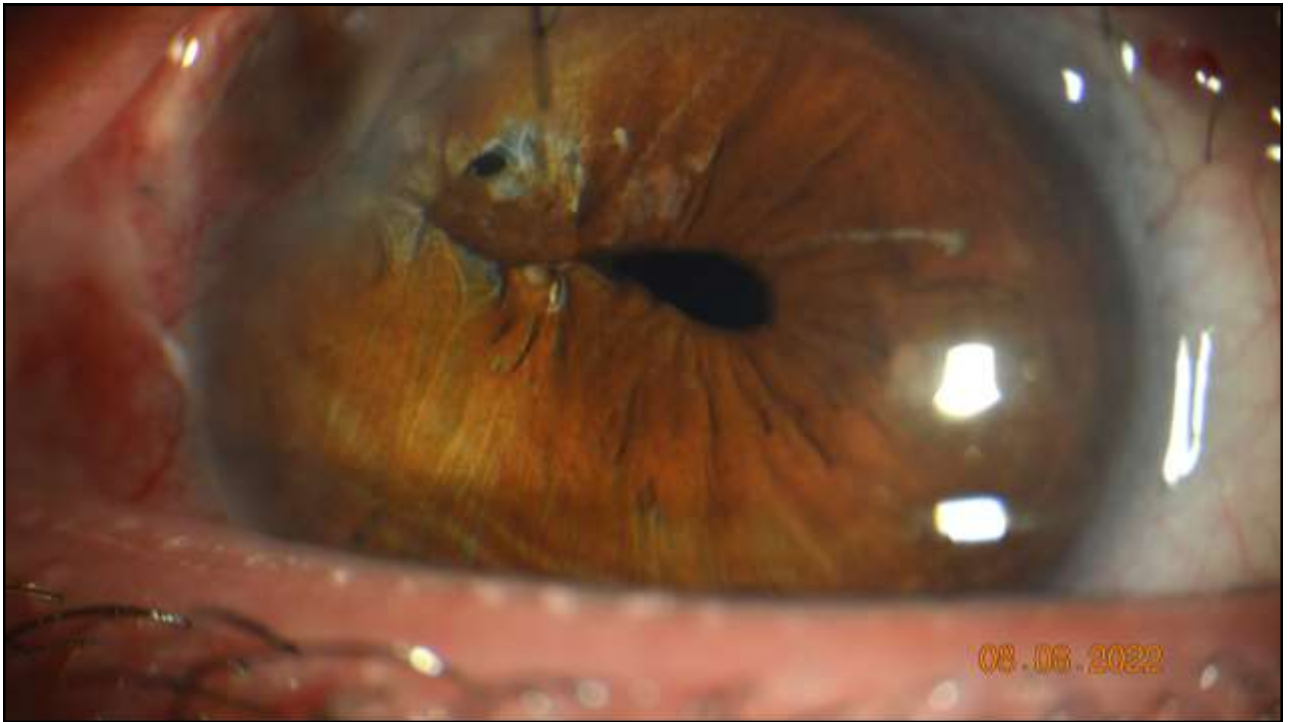



# Patient counselling



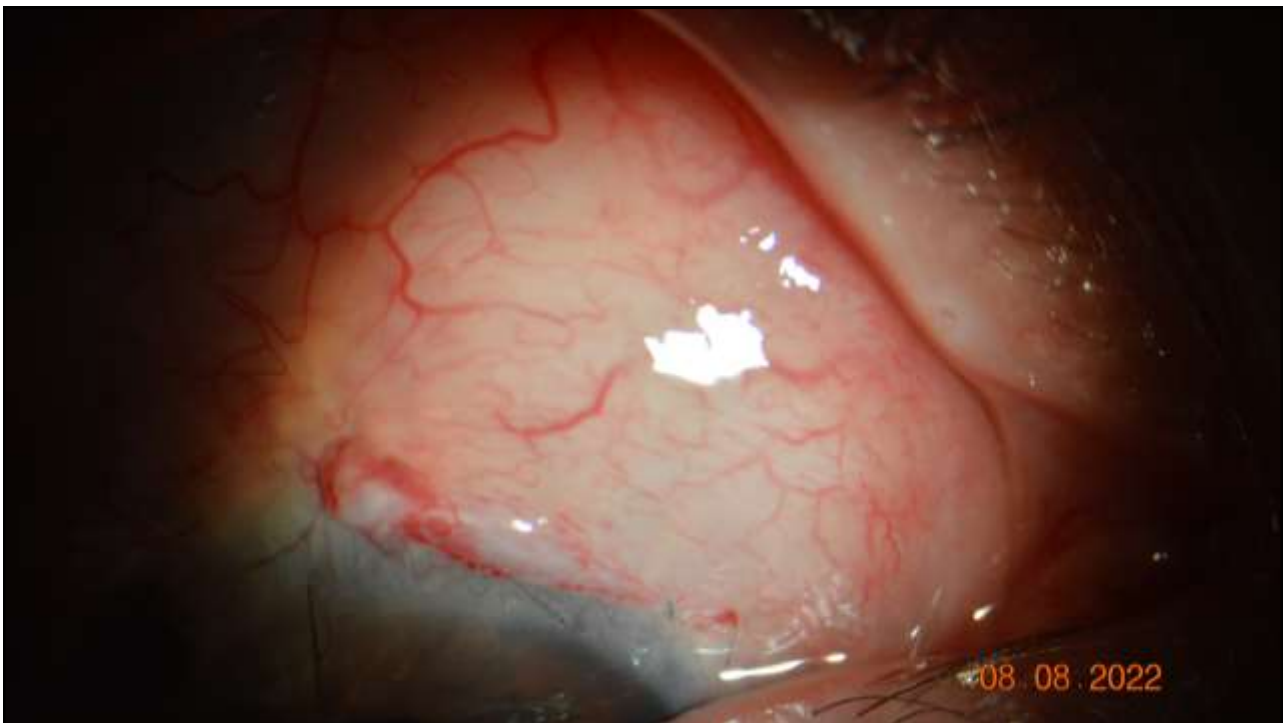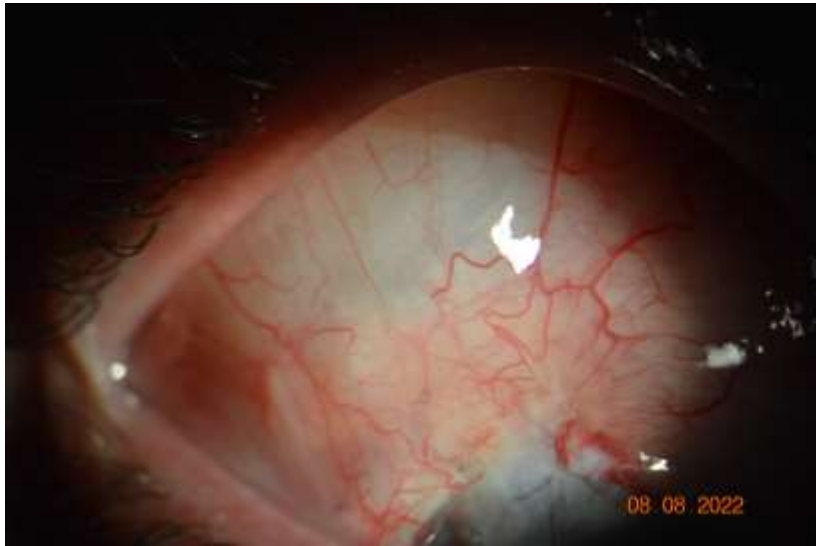


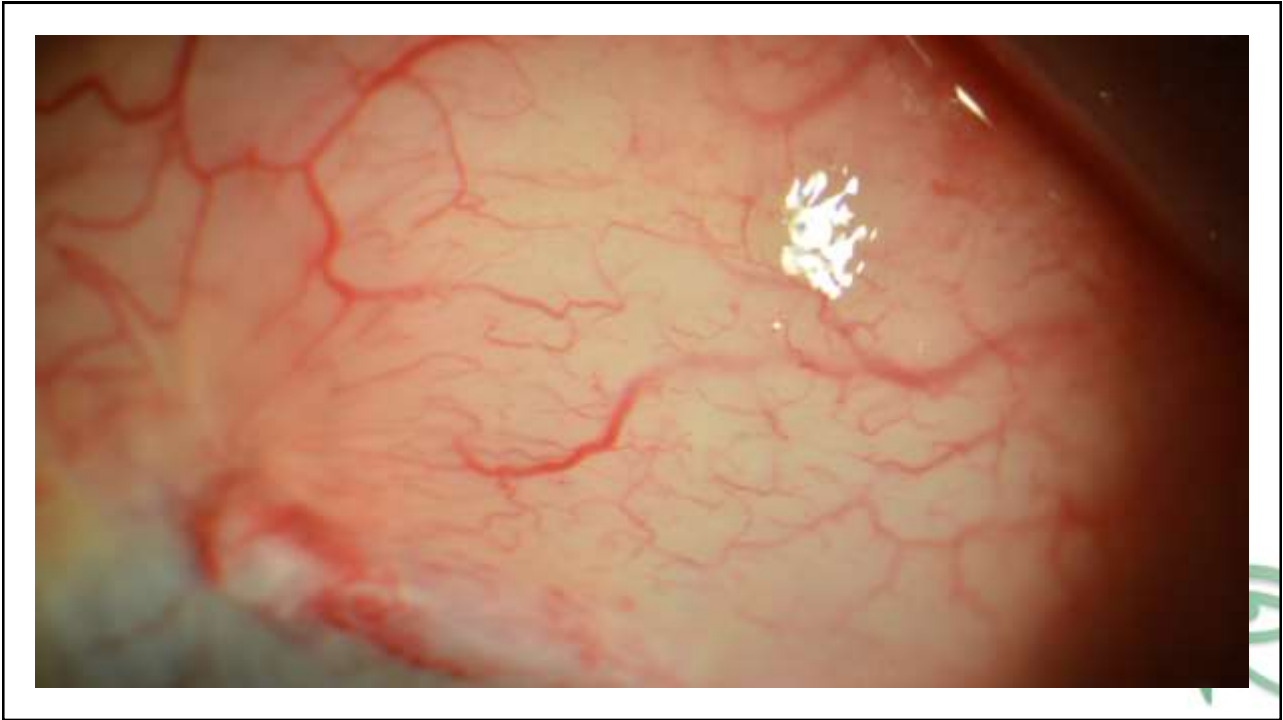


## Six months postoperative

- BVCA 6/9
- IOP : 9 mmHg
- No therapy







Lesson

Plan a head





# THANK YOU

*See you next year*

المؤتمر السنوي الدولي للجمعية الرمدية المصرية

INTERNATIONAL CONGRESS OF THE

**EGYPTIAN  
OPHTHALMOLOGICAL SOCIETY**

**EOS 2024**

**24-26 APRIL 2024**

InterContinental Citystars, Cairo, Egypt

