

المؤتمر السنوي الدولي للجمعية البعدية المصرية
INTERNATIONAL CONGRESS OF THE
EGYPTIAN OPHTHALMOLOGICAL SOCIETY
EOS 2023

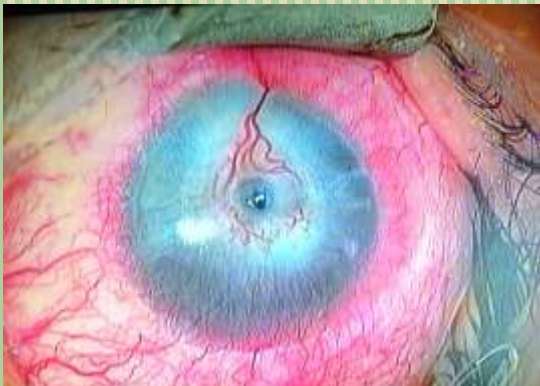
Prof. Mahmoud Ismail
Al Azhar University

*Descemato-Cele
&
Pre-DescematicCele*

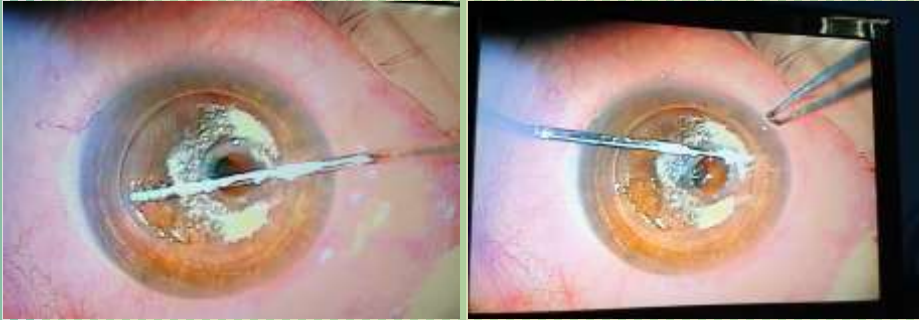


DescematoCele

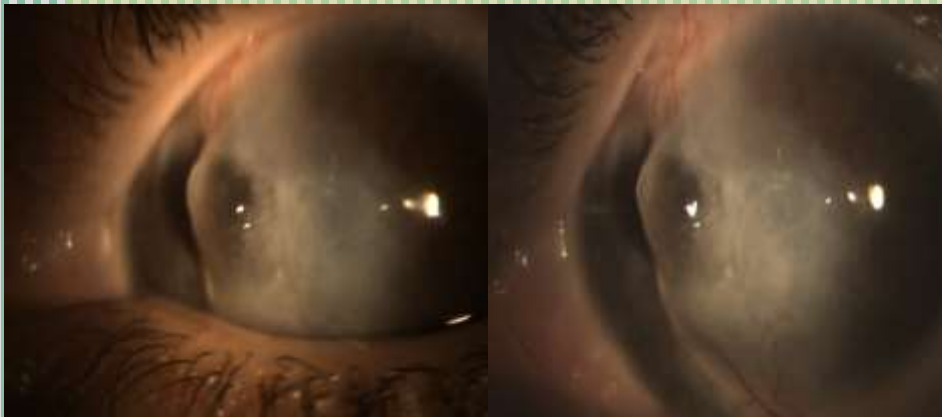
- Uncontrolled infection
- Corneal Melting
- Autoimmune conditions



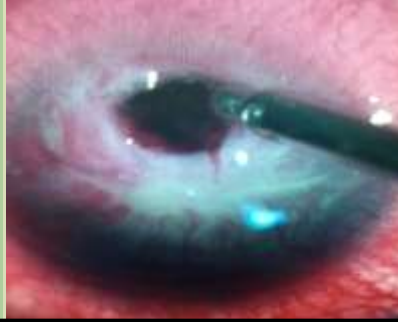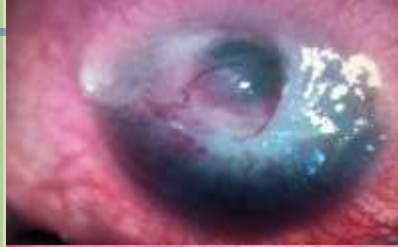
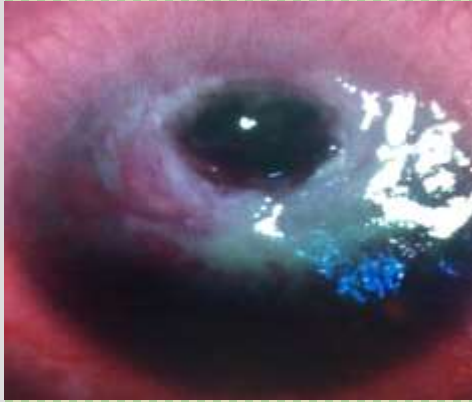With a clear Cleavage



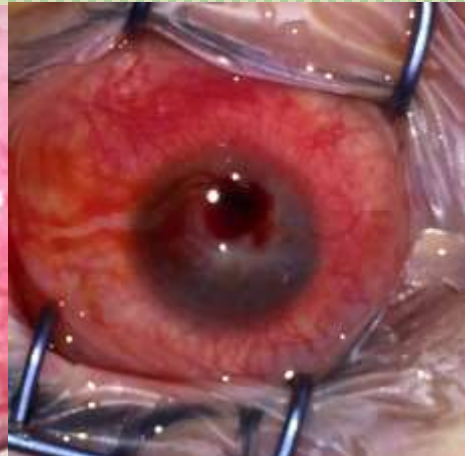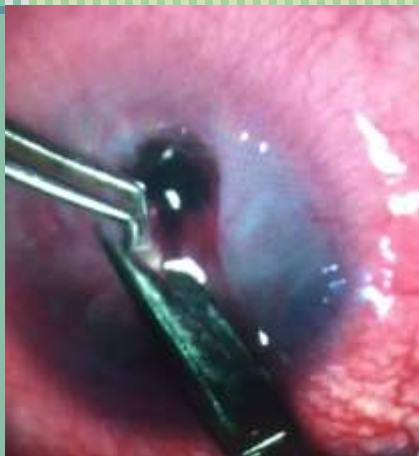Maybe Cold case



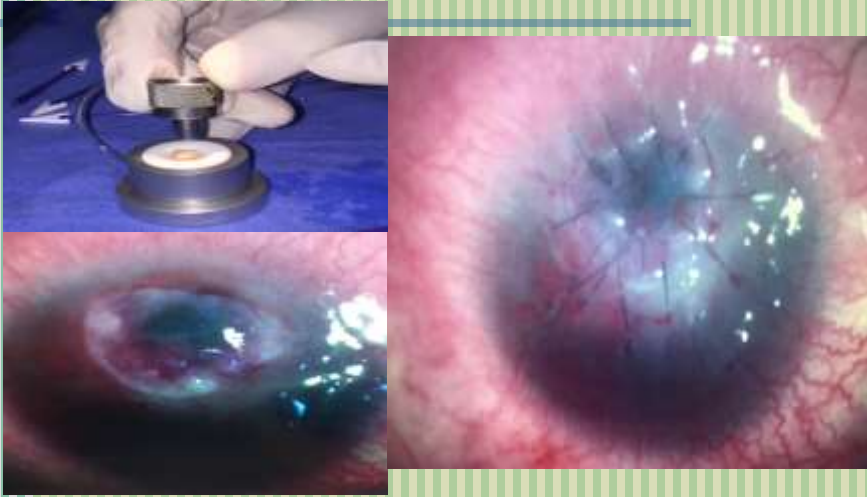
Rheumatoid ... Gives way



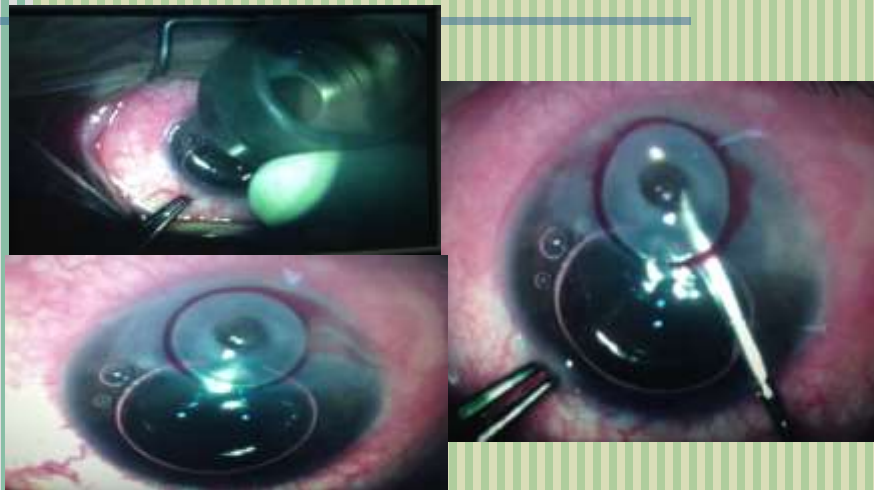Clean edge & media



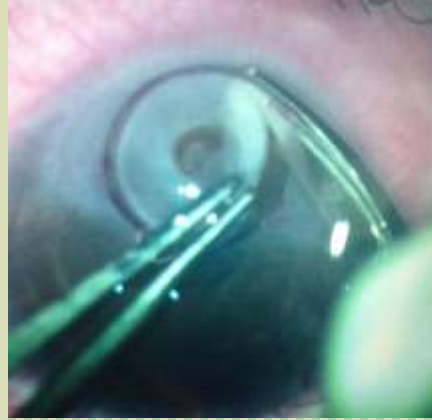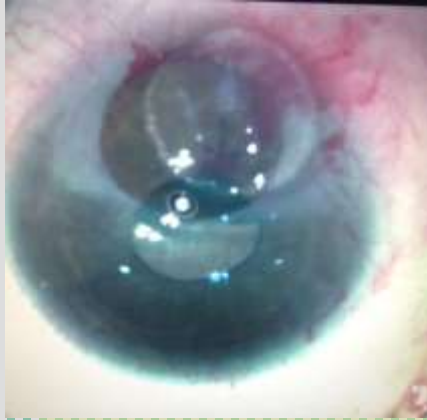Fashion a tectonic Graft



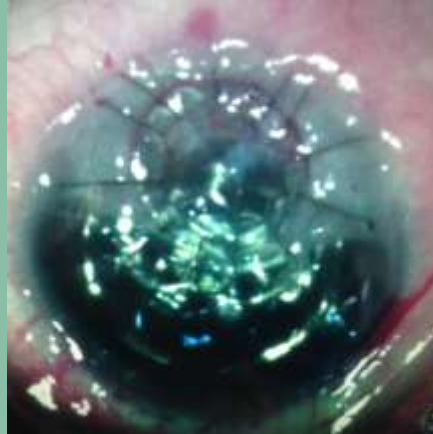Melted Cornea iris incarceration



Lagophthalmos



Postoperative

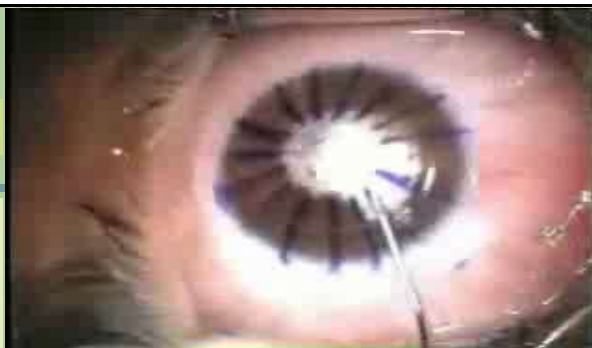

Dua's "Landmark"



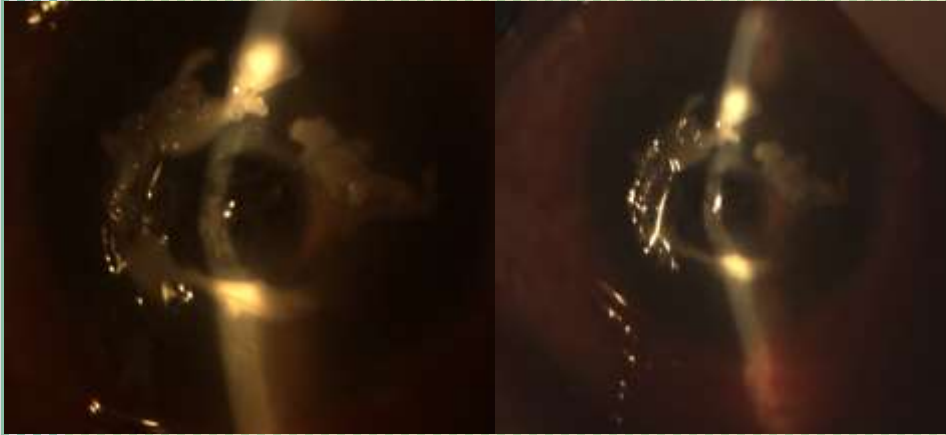Dua's Layer

- Collagen Type I
- 3-4 lamellae
- 10-15 microns
- Free of keratocytes

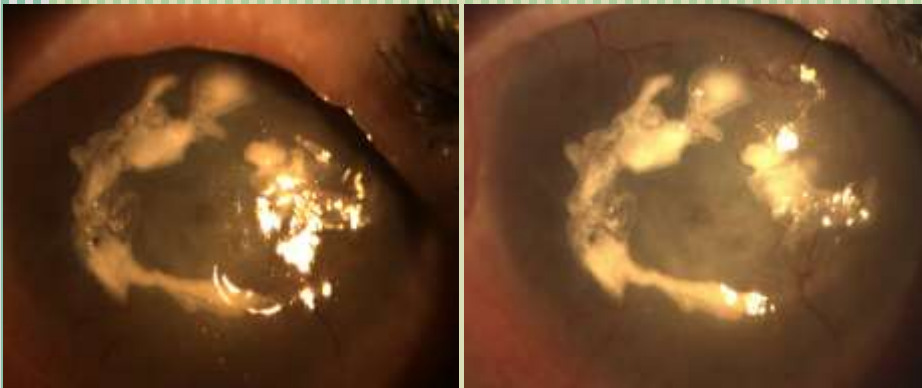


DALK Bubble	Type I	Type II
Location	Stroma & Dua	Dua & Decemet's
Between		
Size of bubble	Central	Extends to Limbus shiny
surface	Slightly rough fine bridges	Smooth No Bridges
perforation	Much Less	vulnerable
Incidence	70-80%	20-30%

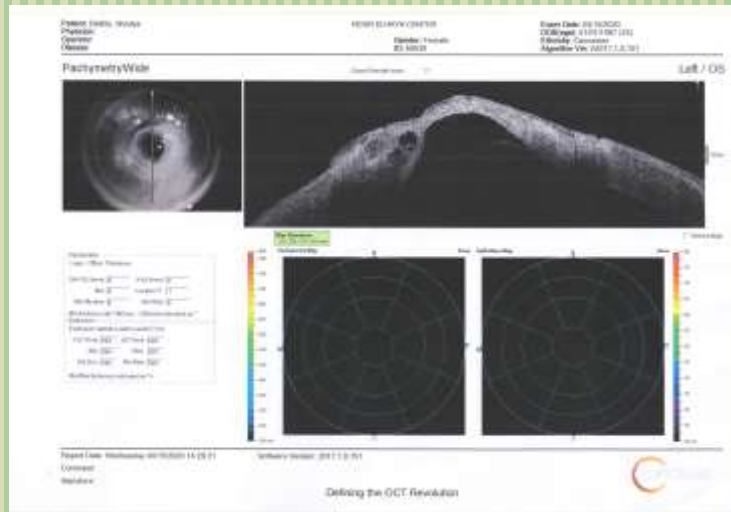
With infectious Keratitis



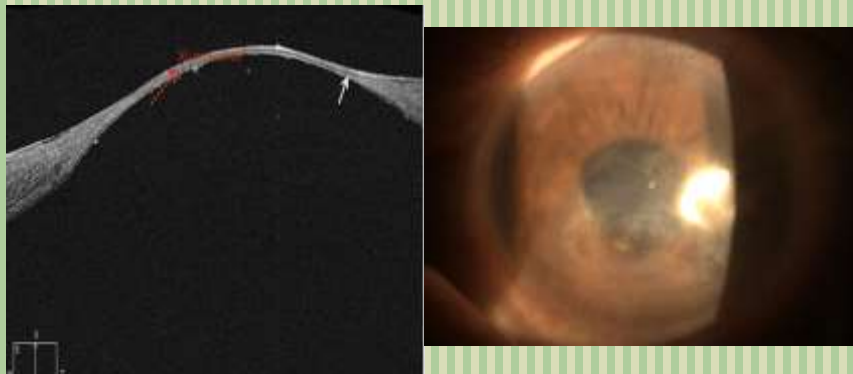
Medical Treatment ... Better !!!



Pre-DescemeticCele "DuaCele"



DecemeticCele



So "Dua-Cele"

■ *DescematoCele*

■ Pre-
DescematoCele

We do have difference

	Pre-descemetoCele	Descemetic-cele
Etiology	Infectious keratitis	Dry eye & Autoimmune
Picture	Rough surface	Glistening
Resilience	Resistant	Easily rupture
OCT	Epithelium cover	None
Shape	Minute or no bulge	Significant bulge

Welcome to EOS 2023



Thank you

