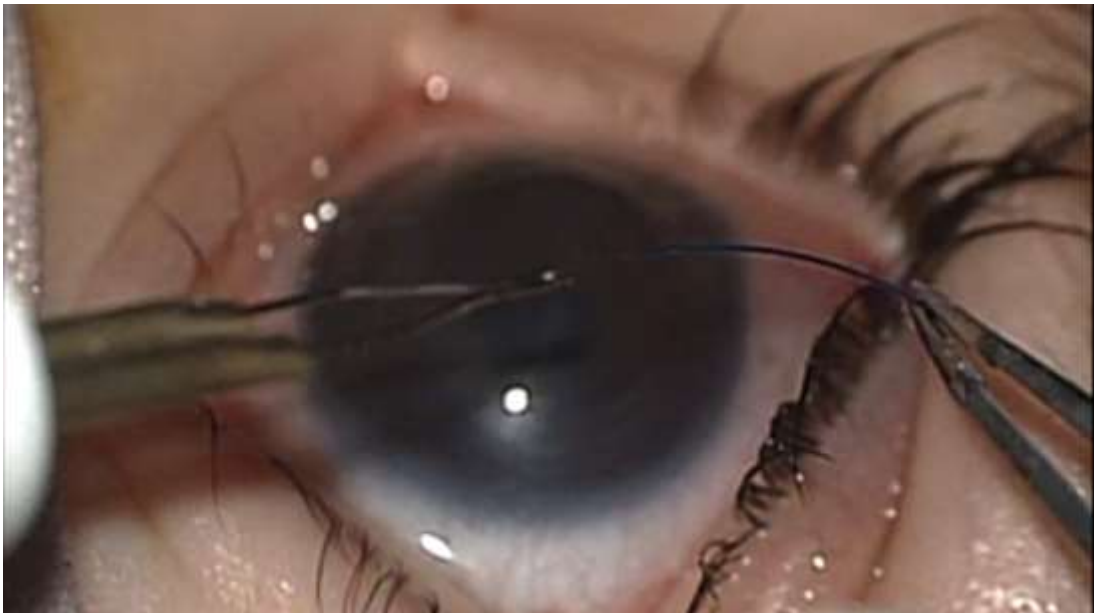




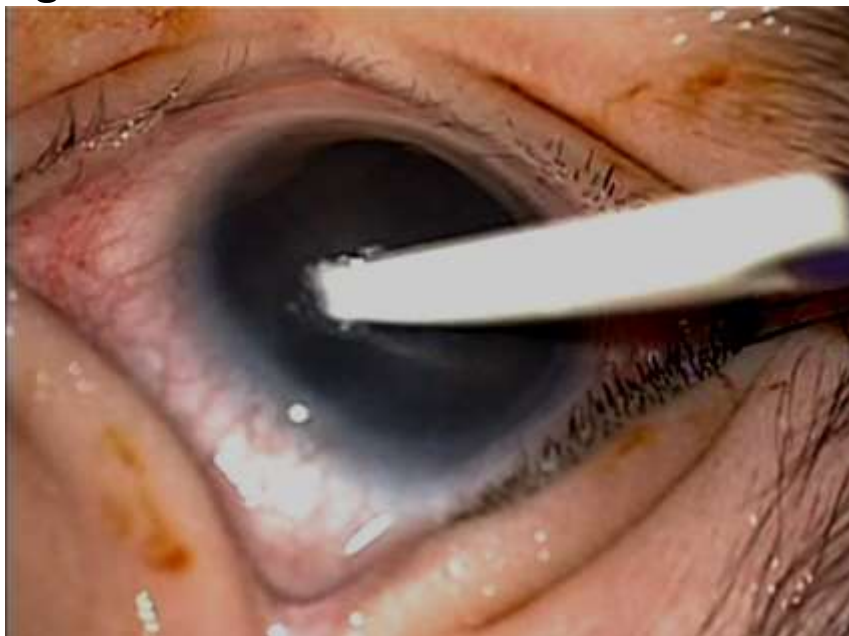Adventures With Gonioscopy-Assisted Transluminal Trabeculotomy

Hala Elhilali MD
Professor of Ophthalmology
Cairo University

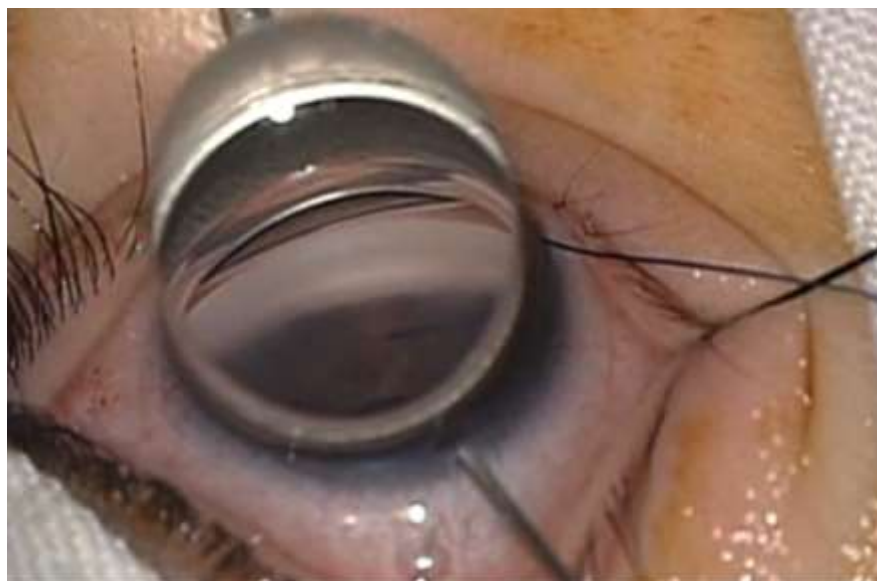Surgical Technique: GATT



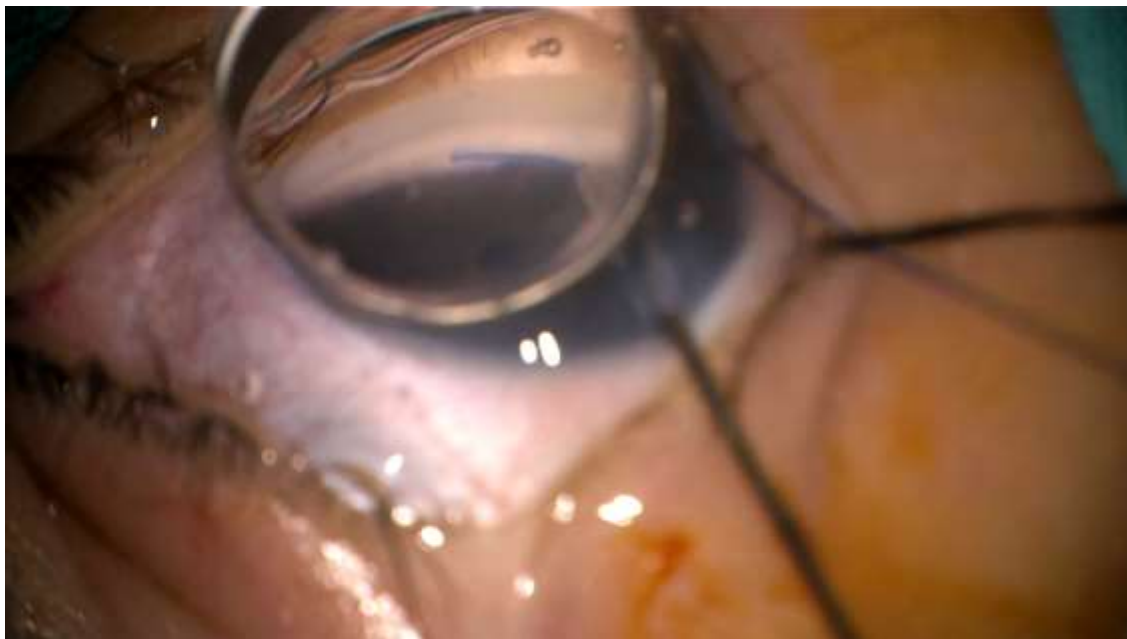
GATT: Going From The Other Side



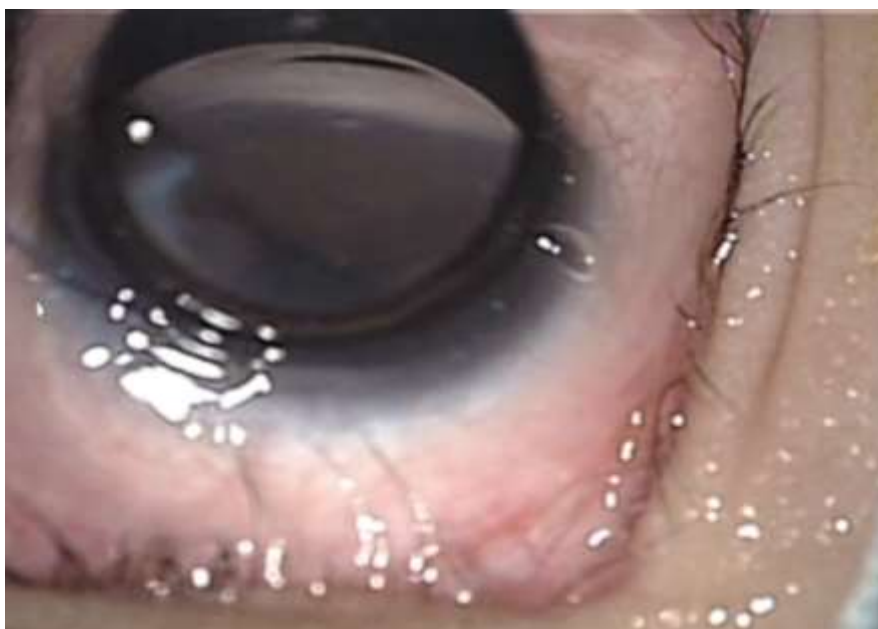When Incision Is In the Wrong Place



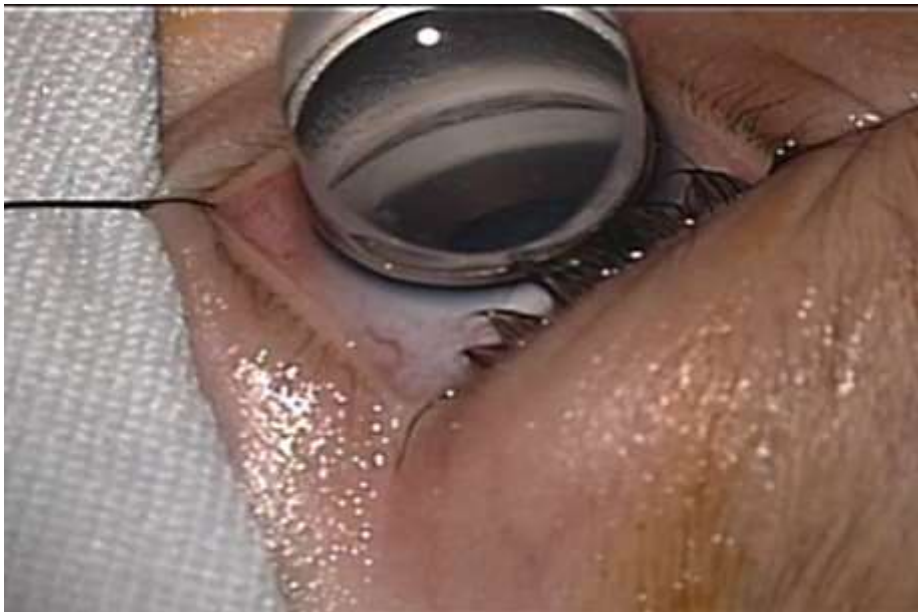When The Prolene Suture Stops



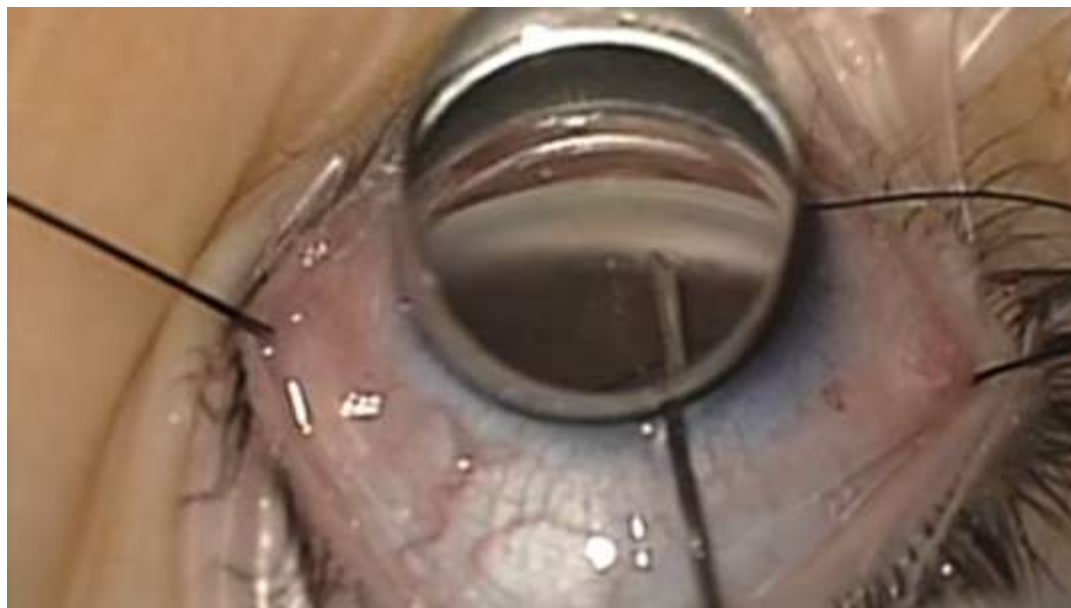
GATT With A Strip



The One That Was Too Thick



The One That Was Stuck



Pediatric Glaucoma Team

- Ghada Gawdat
- Yasmine El Sayed
- Dina Elfayoumy
- Amanne Faisal
- Sara Maher
- Reem Mamdouh

