



Neglected Eyelid Trauma



Sheriff Elwan, MD

**Professor of Ophthalmology
Ain Shams School of Medicine
Consultant Ophthalmic Plastic Surgeon
Ain Shams University Hospitals**



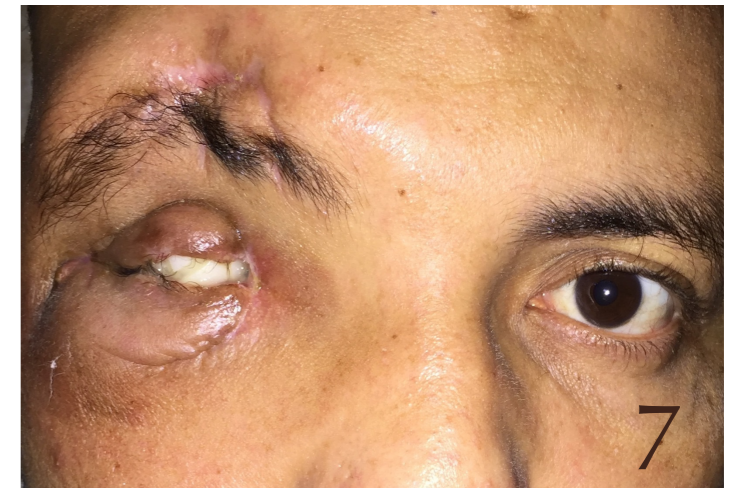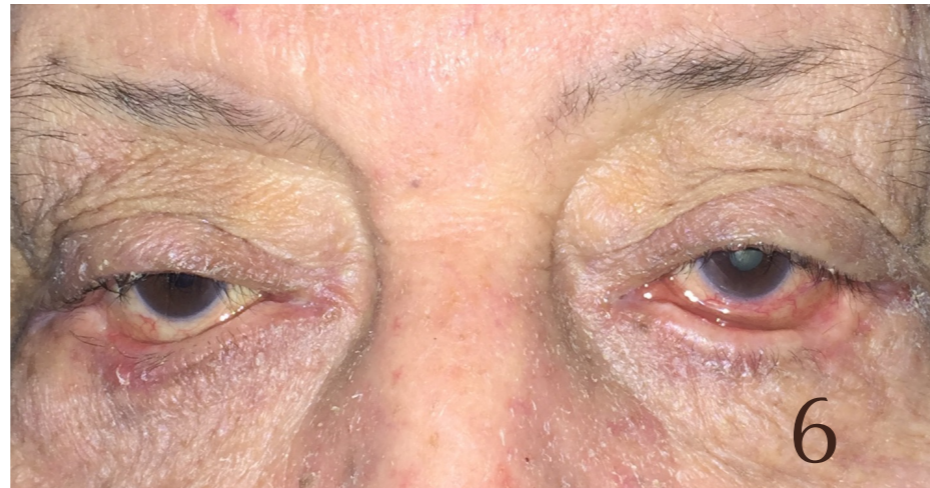
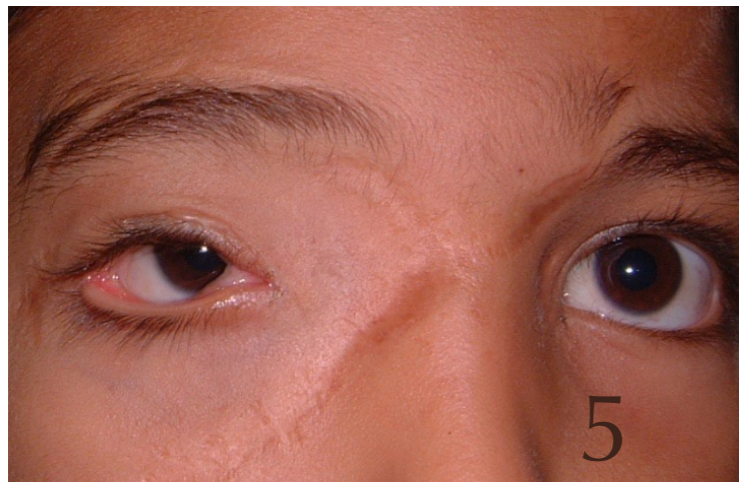
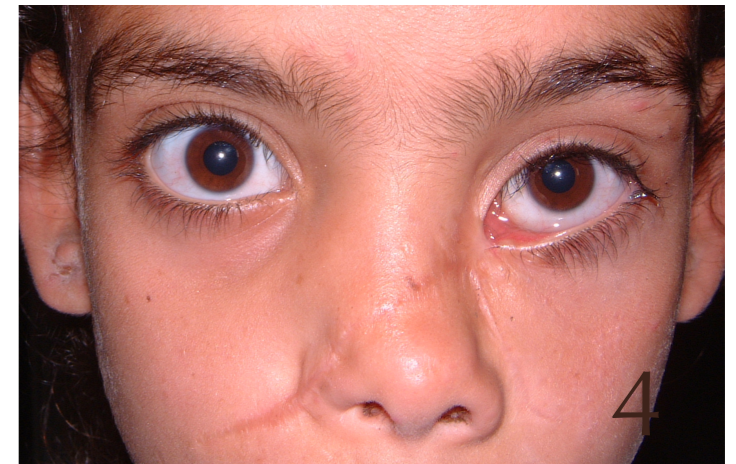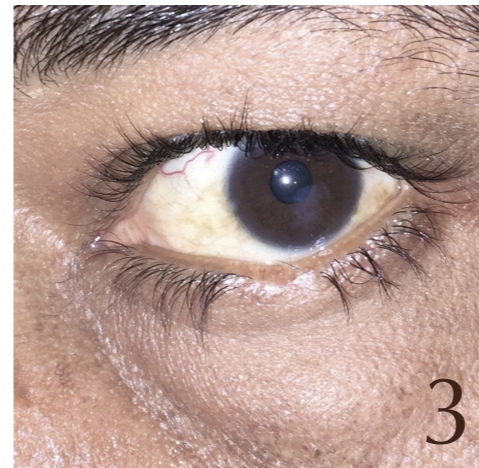
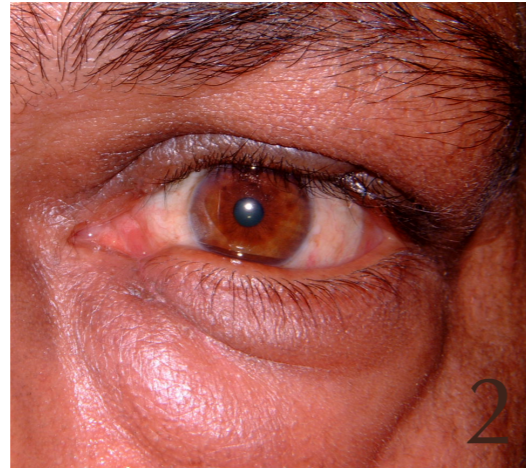
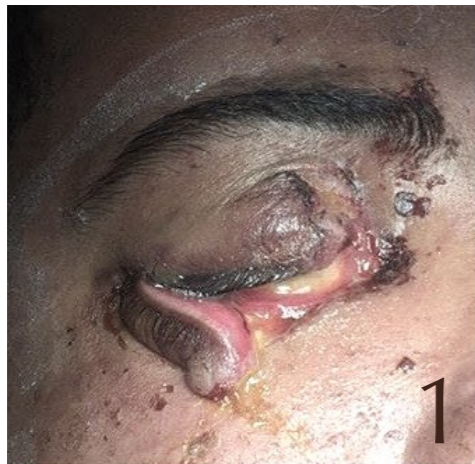NEGLIGENCE

1. No repair
2. Delayed repair
3. Mal-repair
 - a. No apposition
 - b. Non-anatomical apposition
 - c. Bad suturing techniques & materials (iatrogenic)





NEGLIGENCE





APPROACH

1. Good history
 - a. Type of trauma
 - b. Time of trauma
 - c. Details of repair (if applicable & available)

2. Examination:
 - a. Mal-positions
 - b. Scar mechanics

3. Indications for repair:
 - a. Functional
 - b. Cosmetic

4. Photography

Sheriff Elwan, MD



PRINCIPLES

1. Six-months rule
2. Scar excision
3. Anatomical apposition
4. Grafting
5. Multi-stepped approach
6. Suturing material & techniques

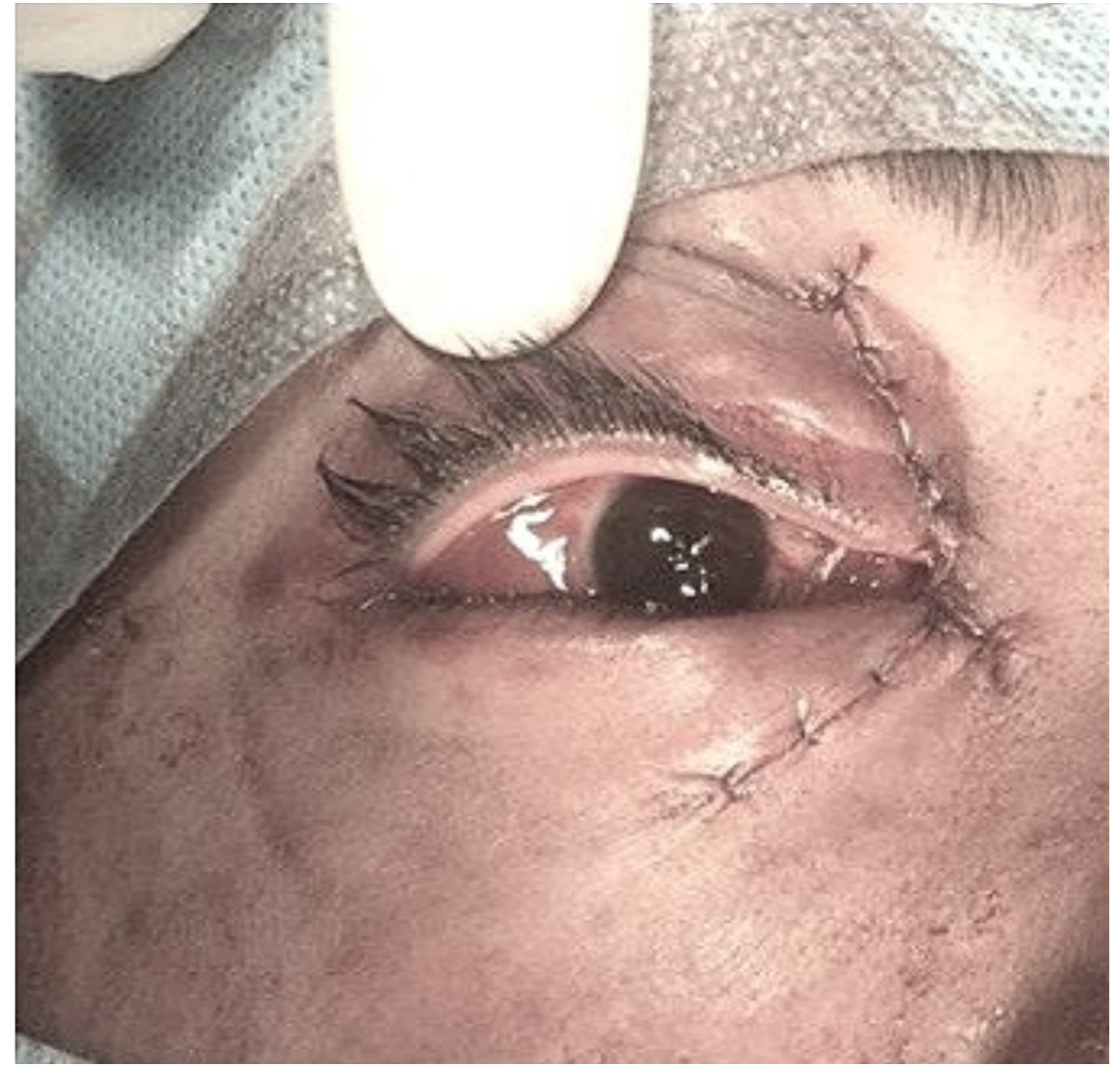
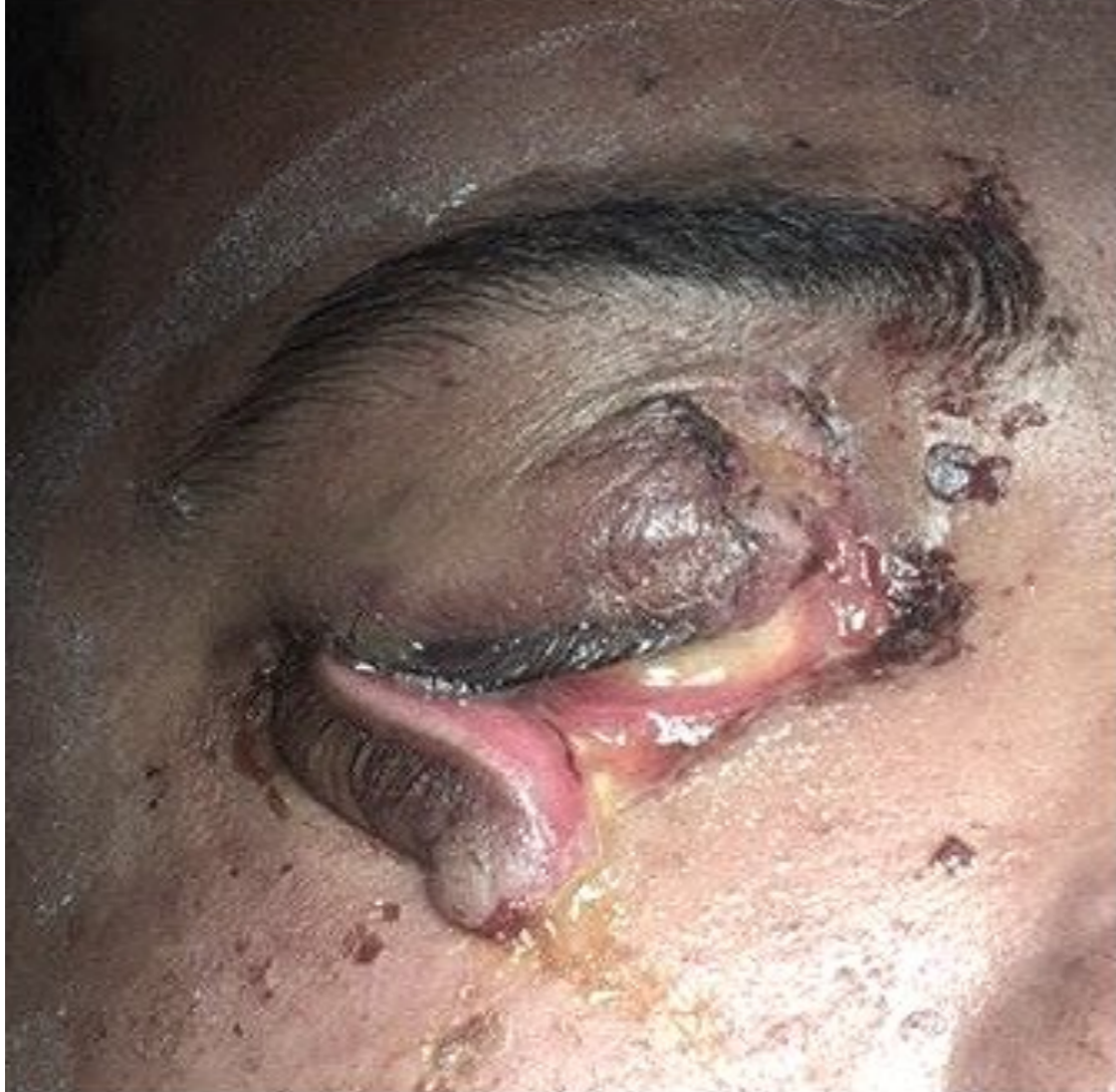
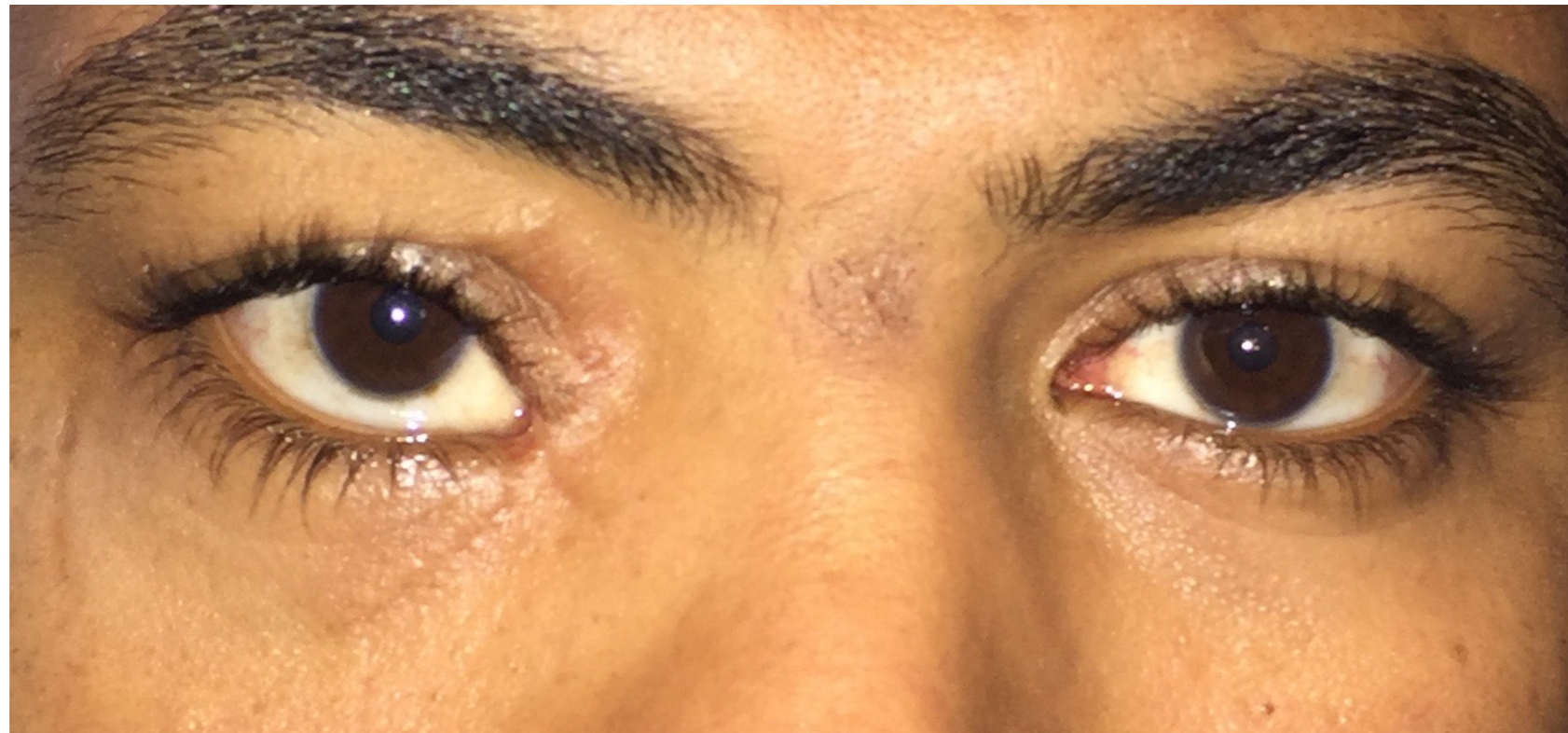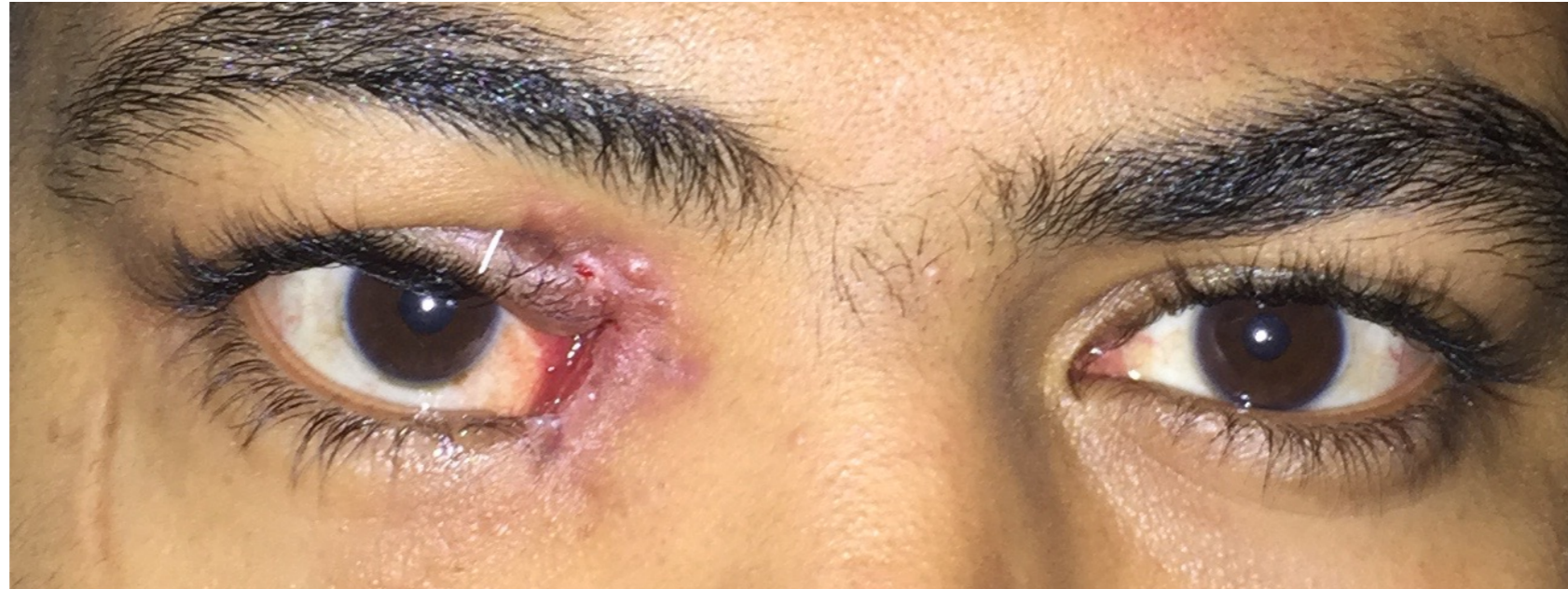No repair



Total Negligence

Blast Injury





Sheriff Elwan, MD

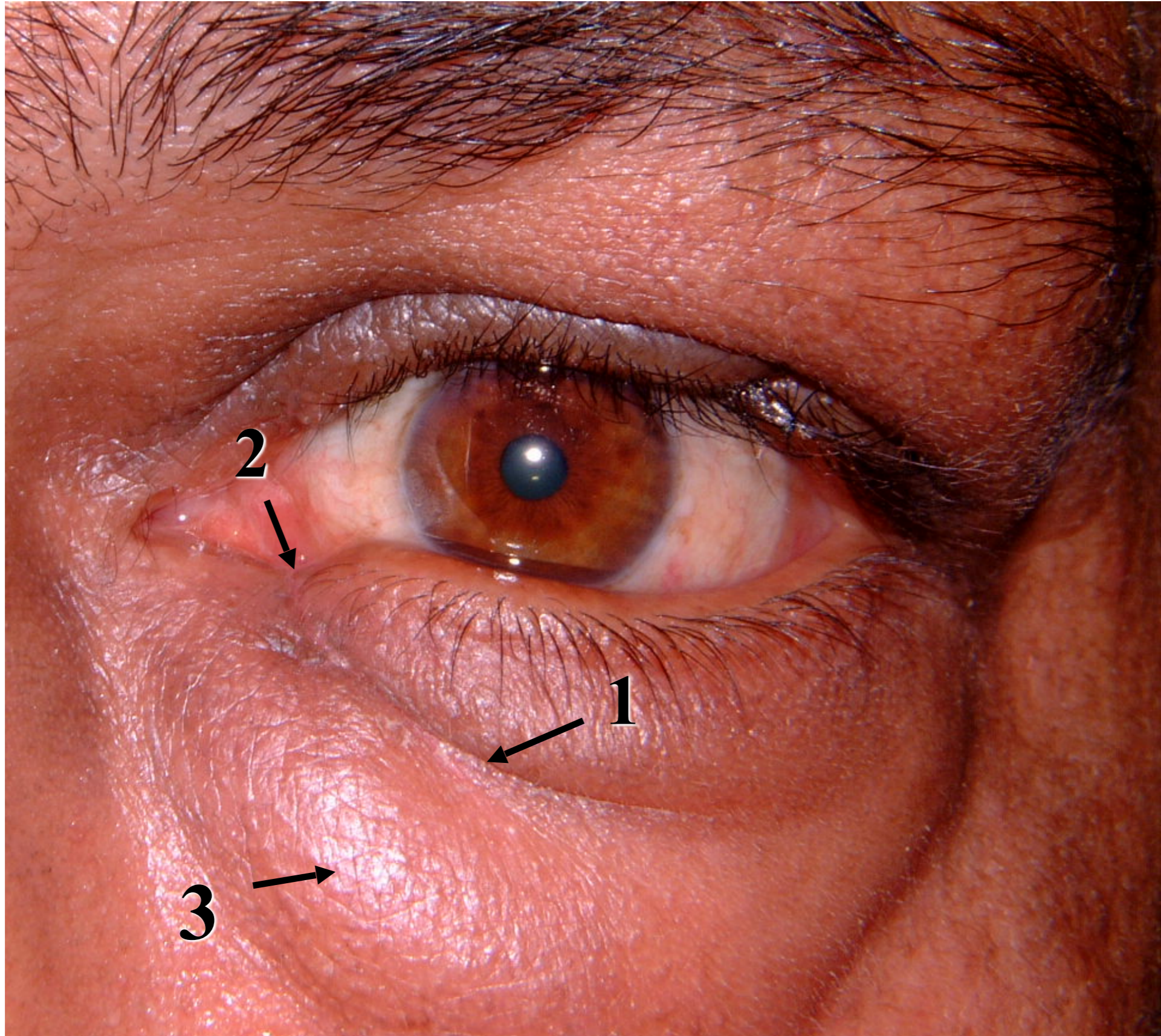


Mal-repair

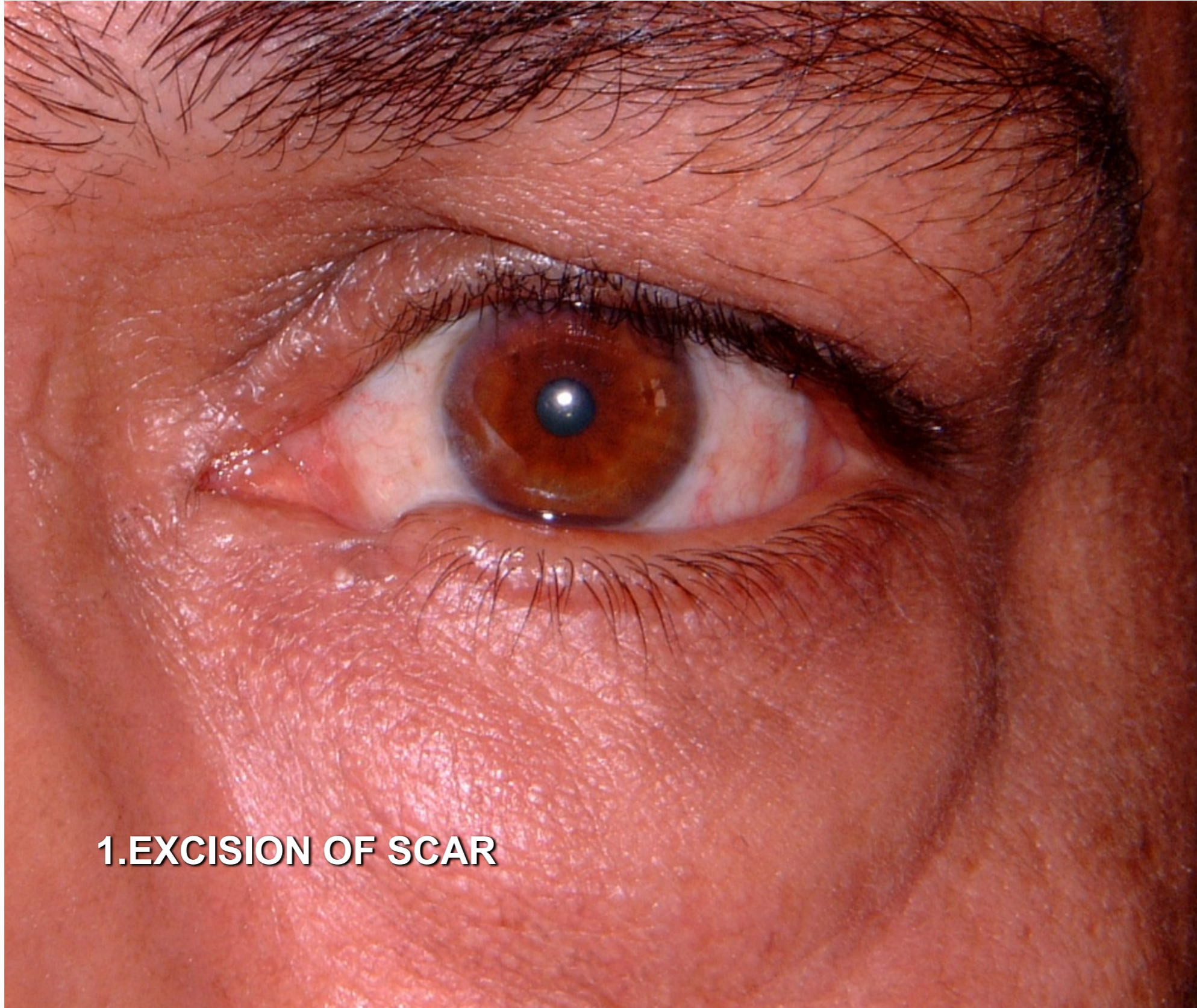
a. Non Apposition



Multi-stepped Approach

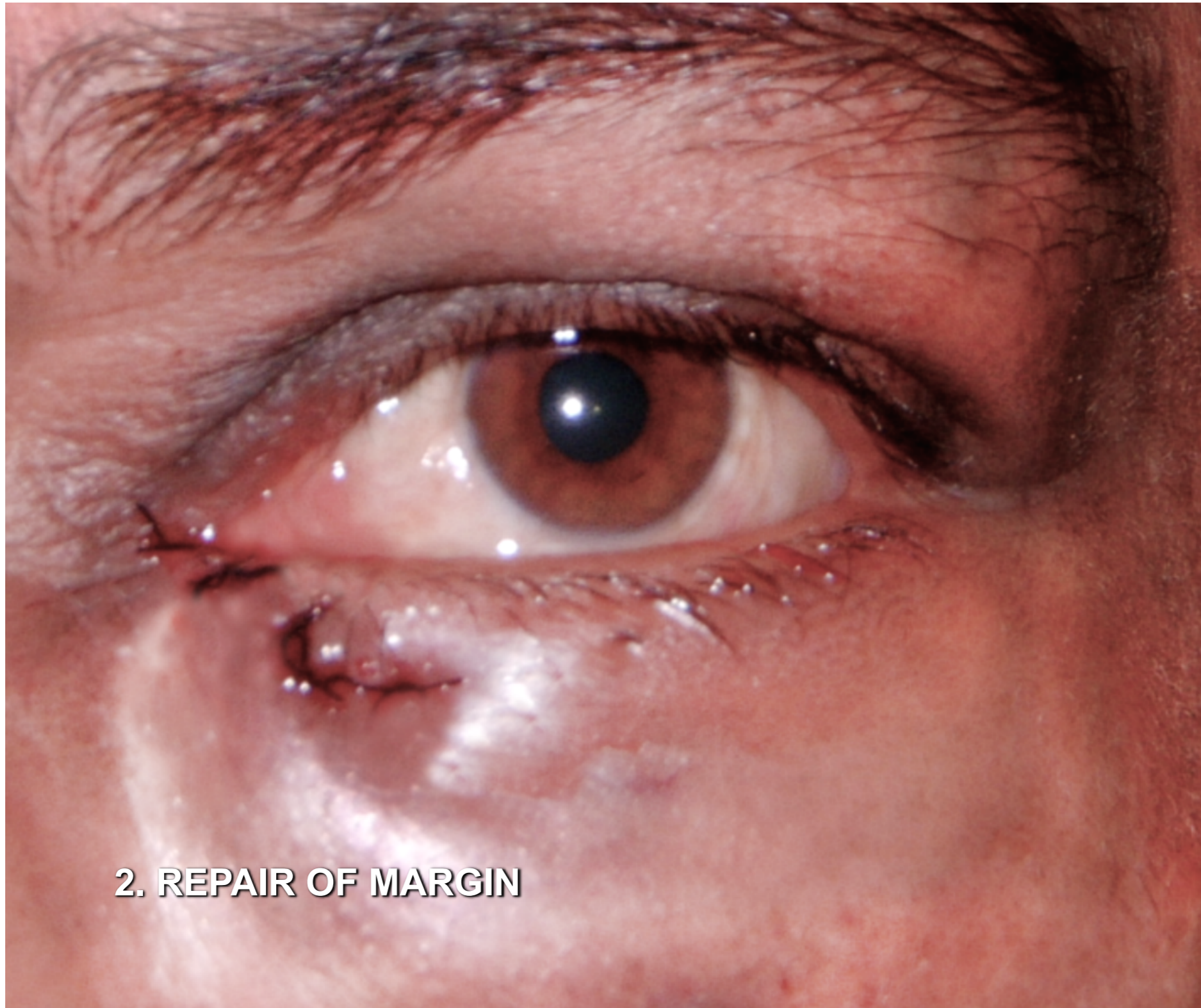

Sheriff Elwan, MD

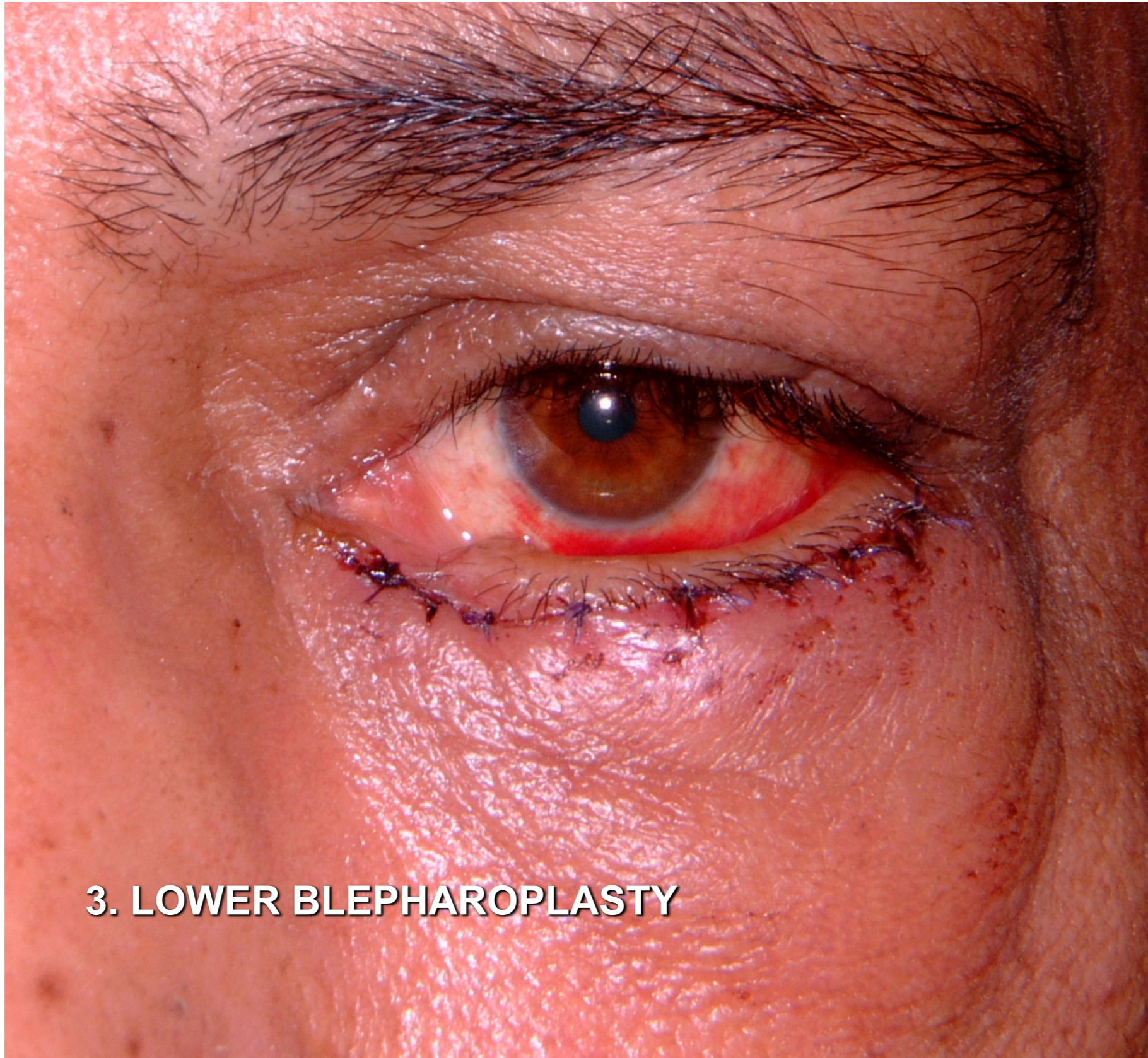

1.EXCISION OF SCAR

Sheriff Elwan, MD

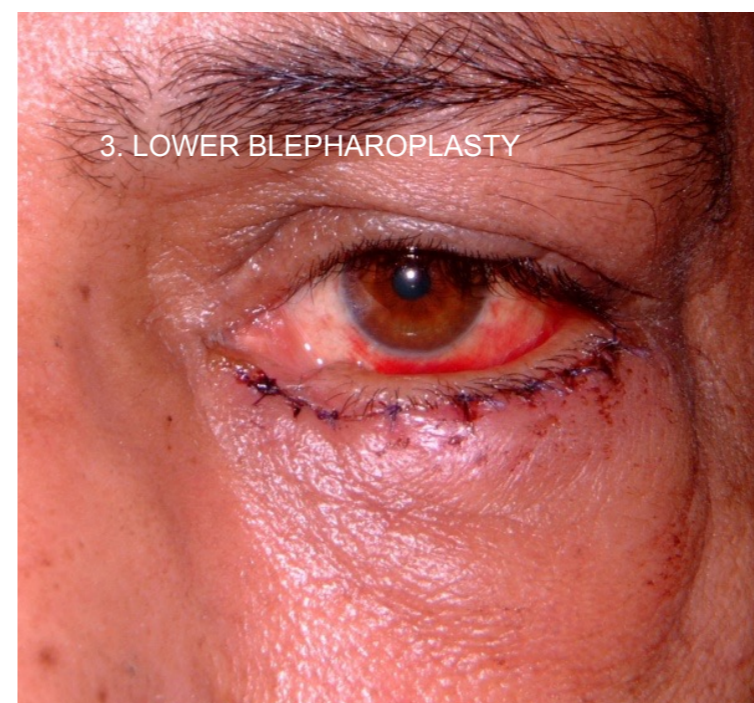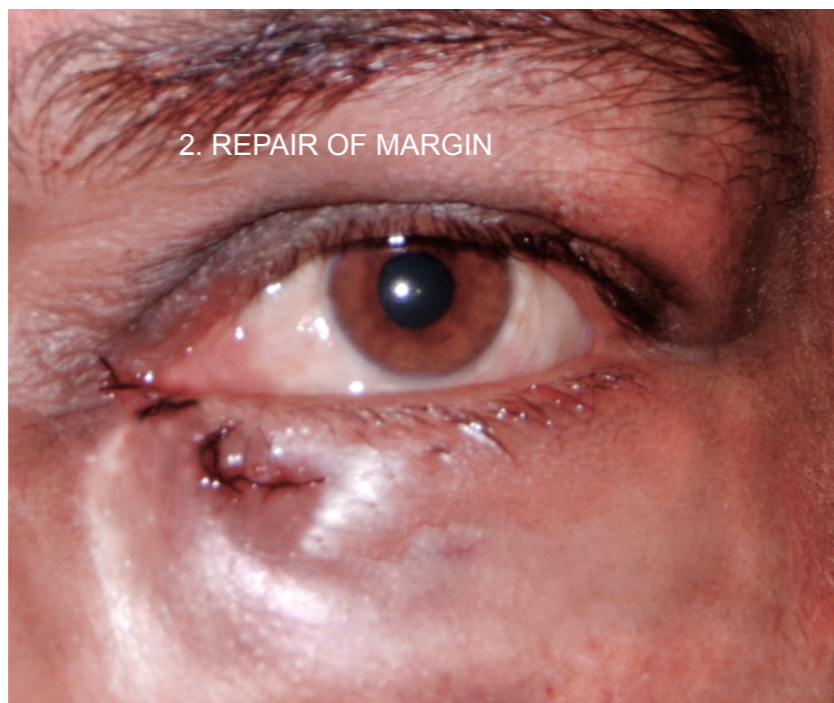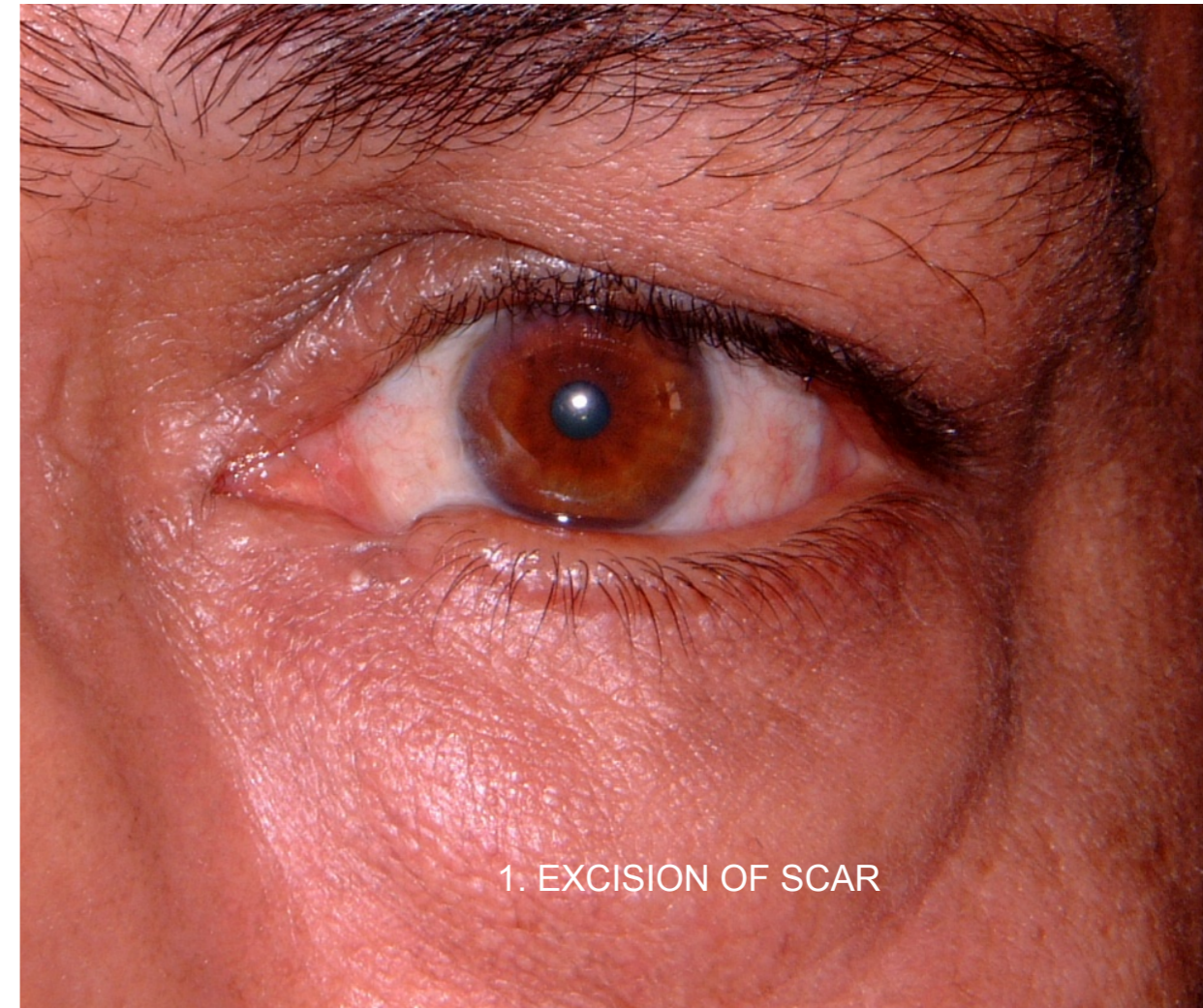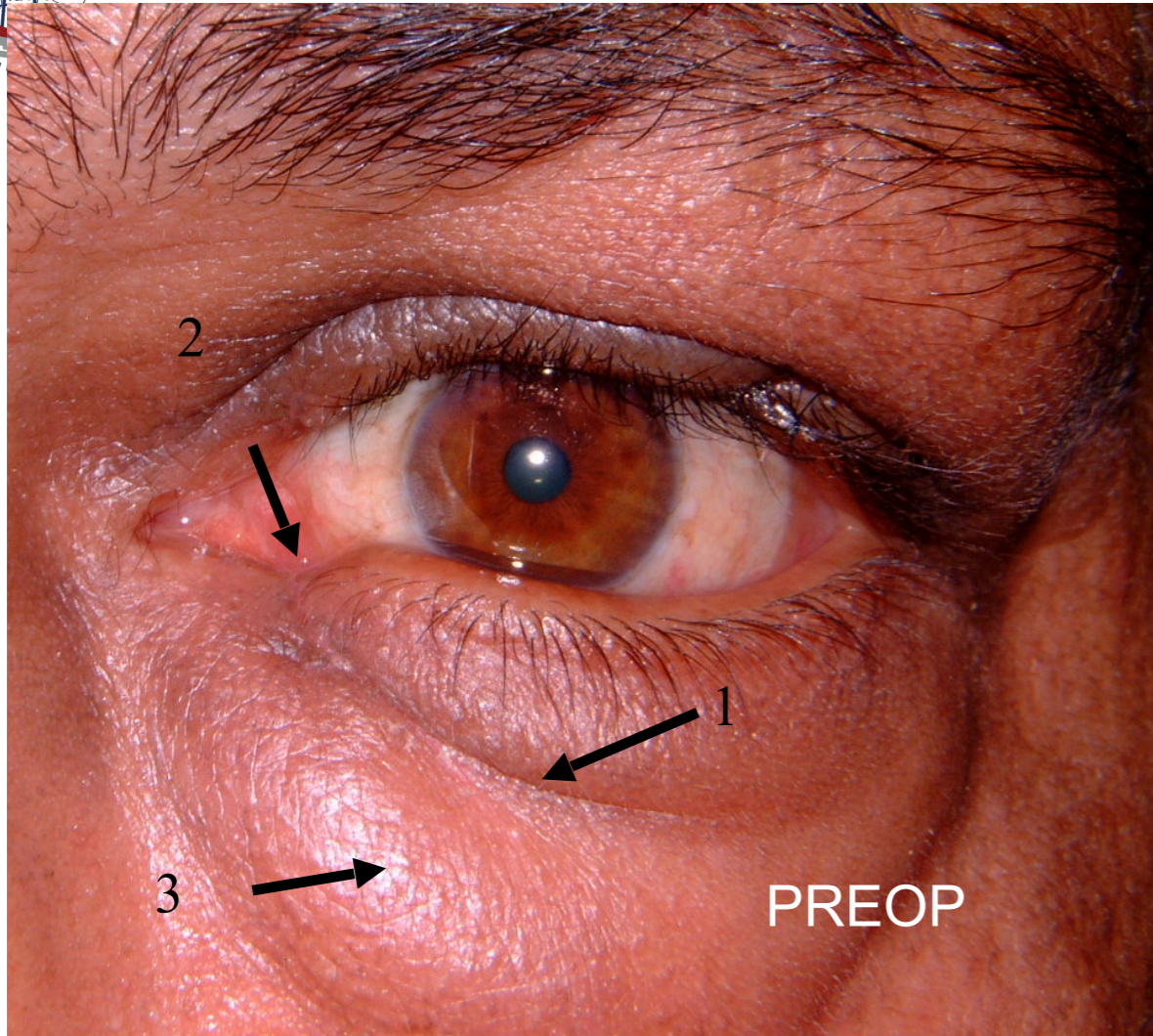


Sheriff Elwan, MD



3. LOWER BLEPHAROPLASTY

Sheriff Elwan, MD

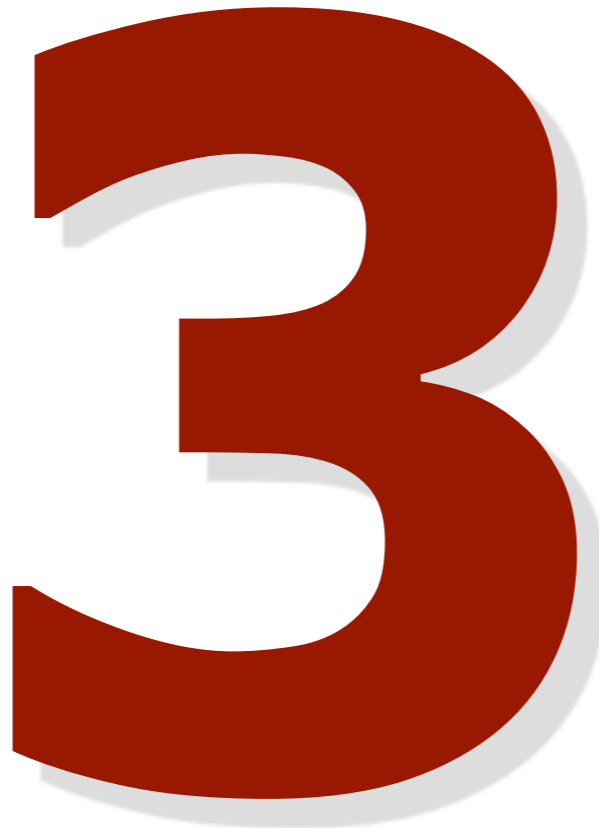

Sheriff Elwan, MD

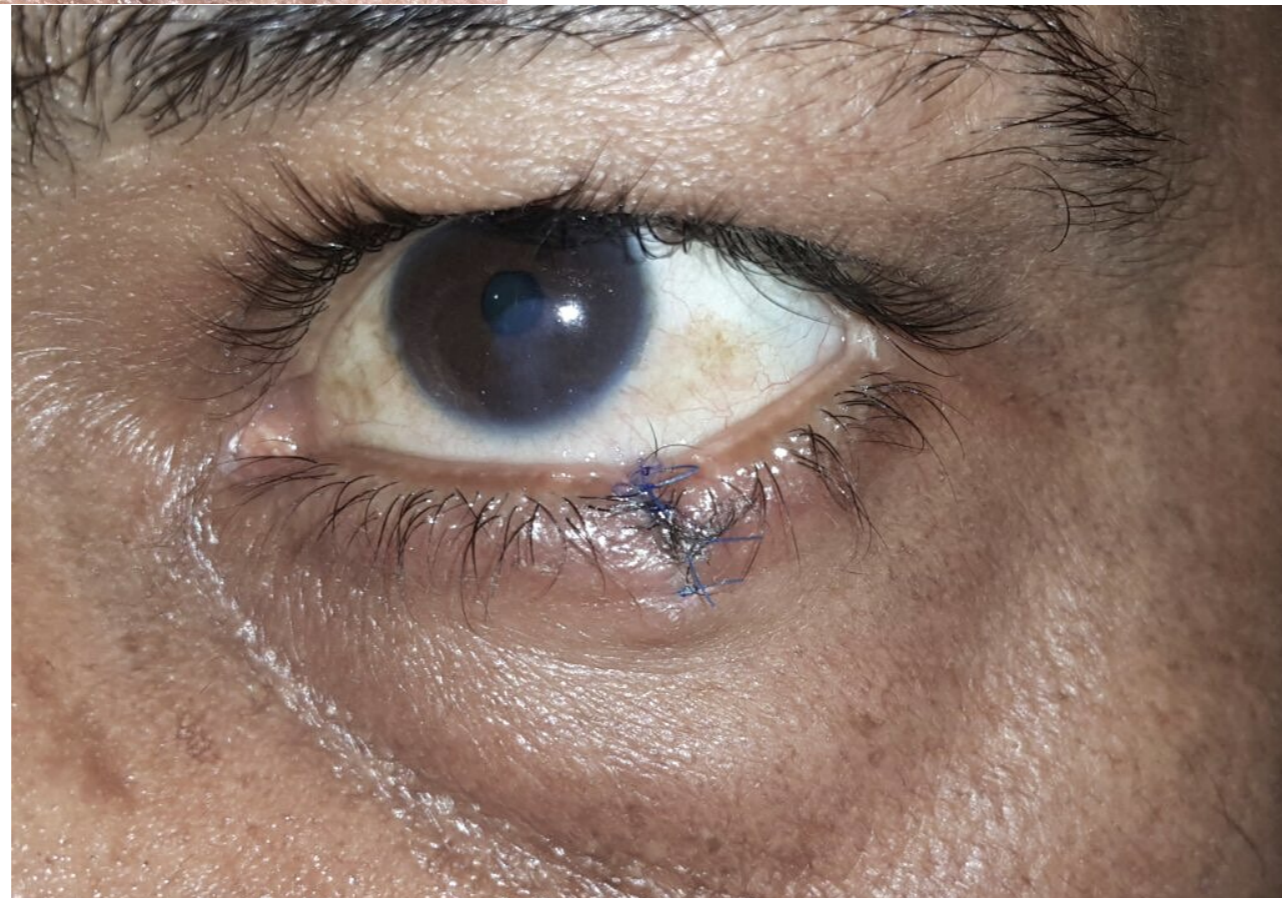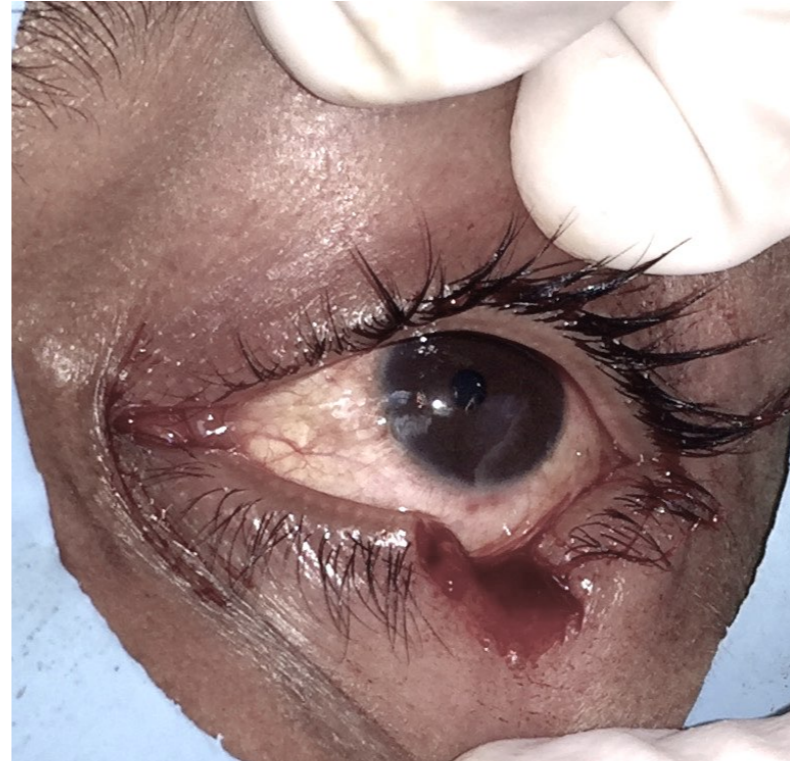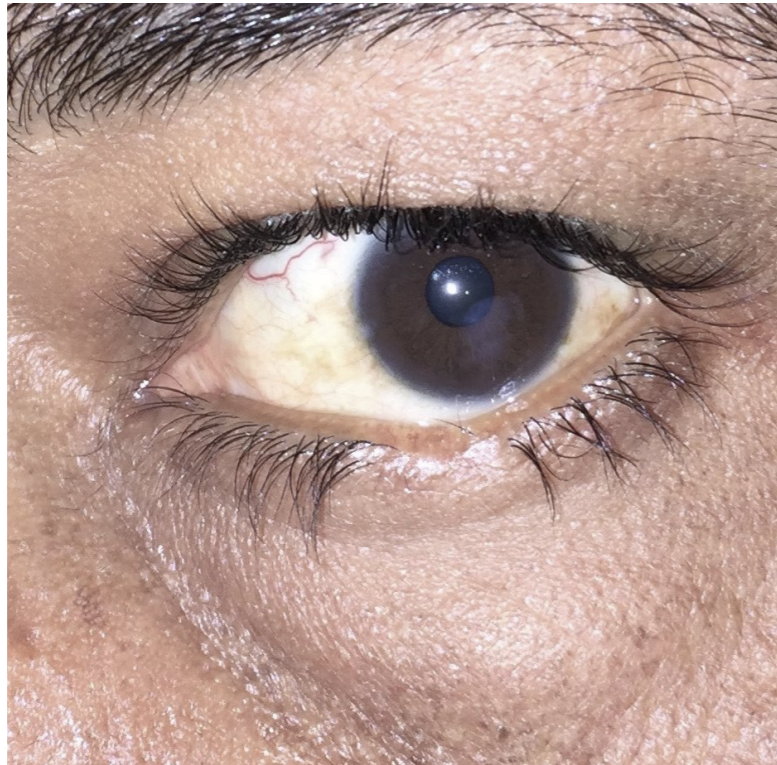


Mal-repair

b. Non-anatomical Apposition



Madarosis

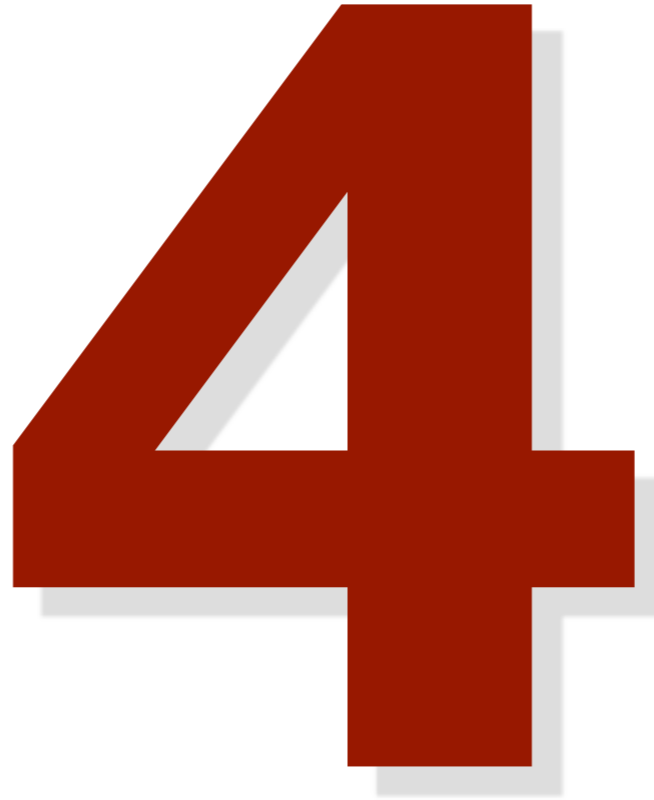

Sheriff Elwan, MD



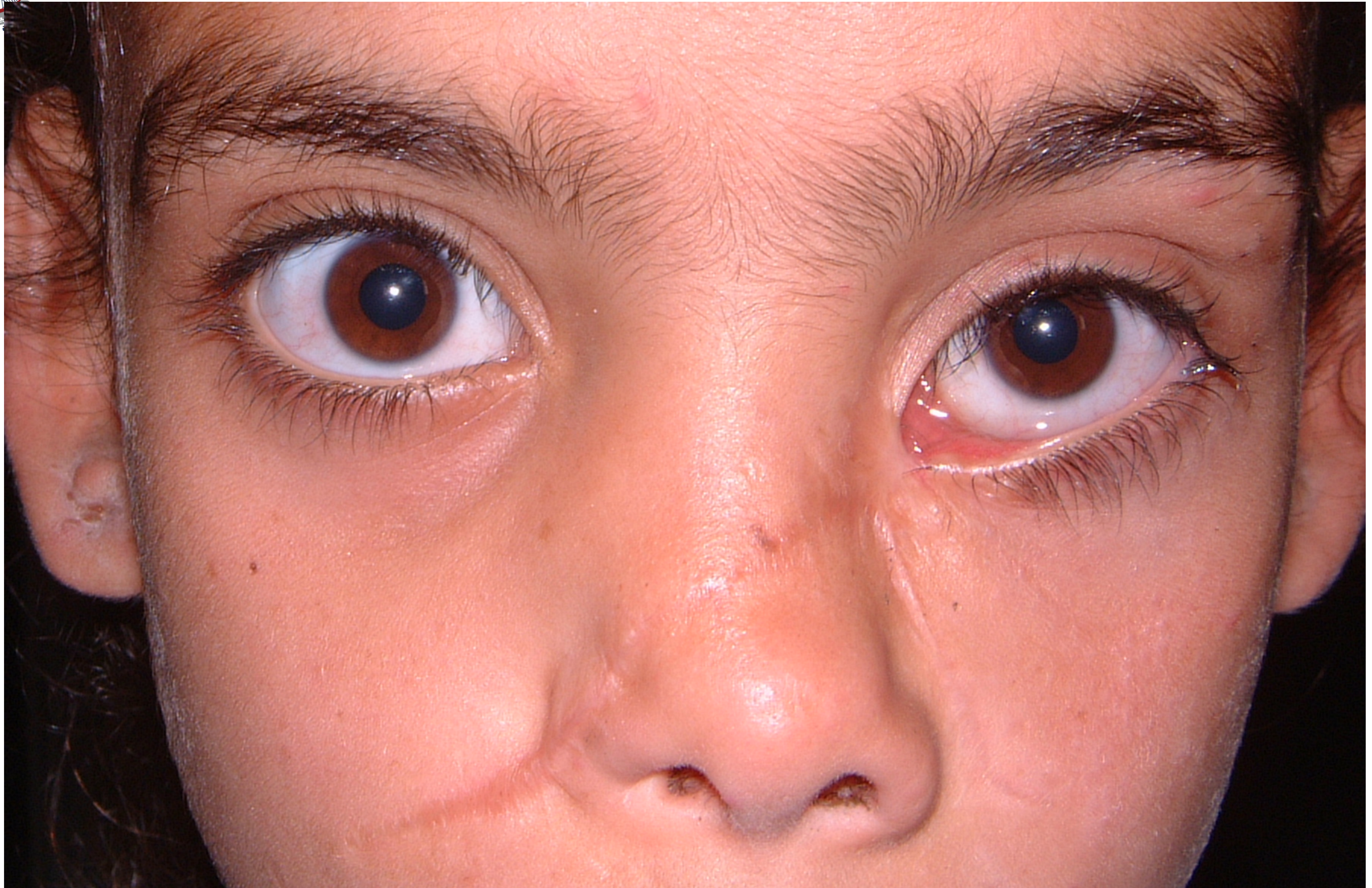Mal-repair

b. Non-anatomical Apposition



Combined V-Y & Z plasties

Sheriff Elwan, MD



Sheriff Elwan, MD



Z-Plasty¹

Indication:

Lengthening wounds.

Redirection of scars.

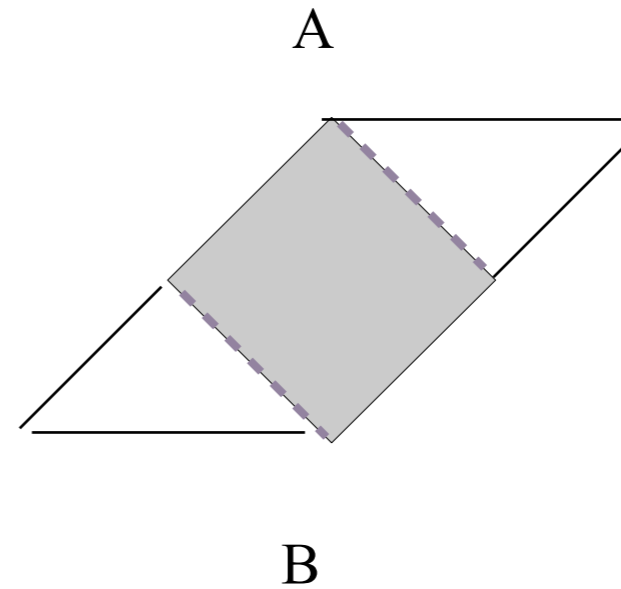
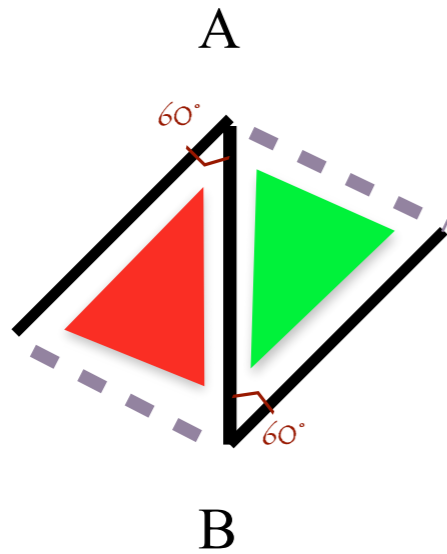
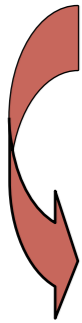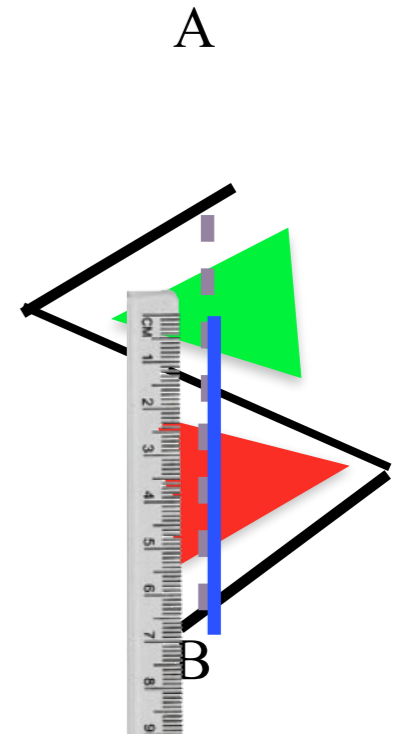
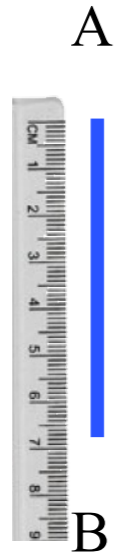
Composition:

Narrower angle: Risk of flap necrosis

Broader angle: Difficult transposition

Sheriff Elwan, MD

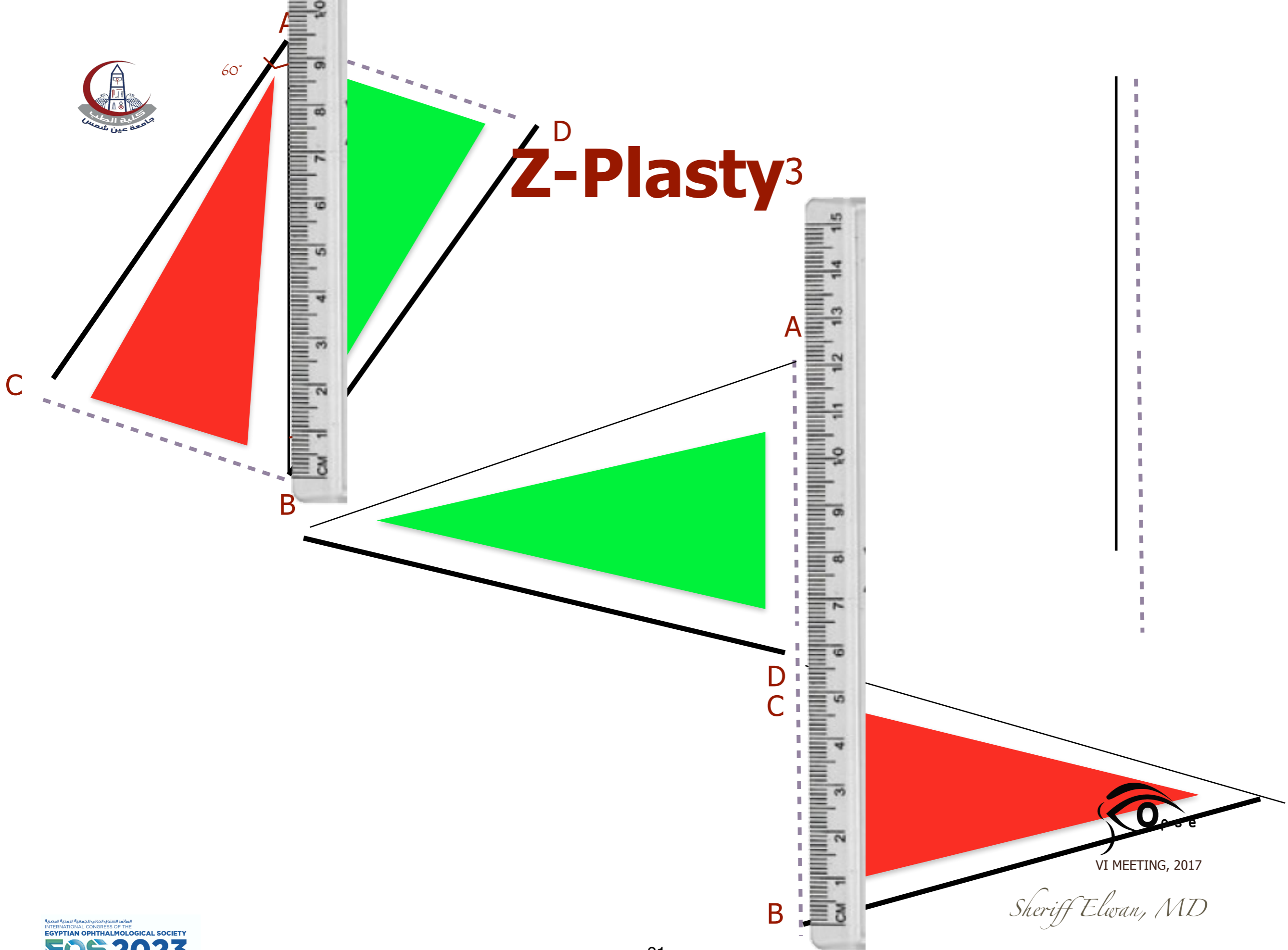
Z-Plasty²



Sheriff Elwan, MD

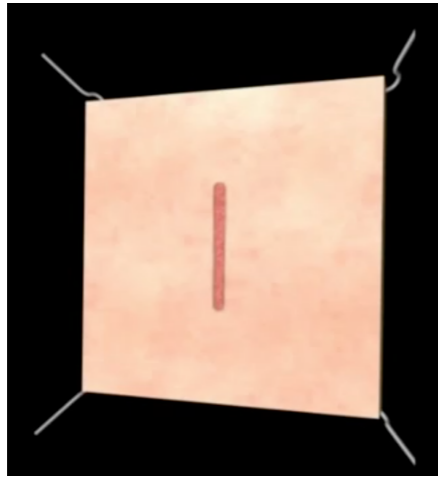


Z-Plasty³

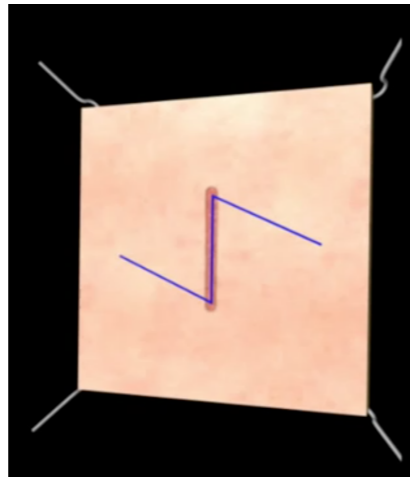


Sheriff Elwan, MD

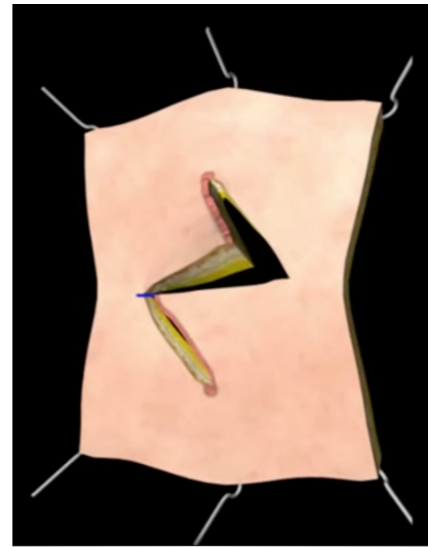
Z-Plasty⁴



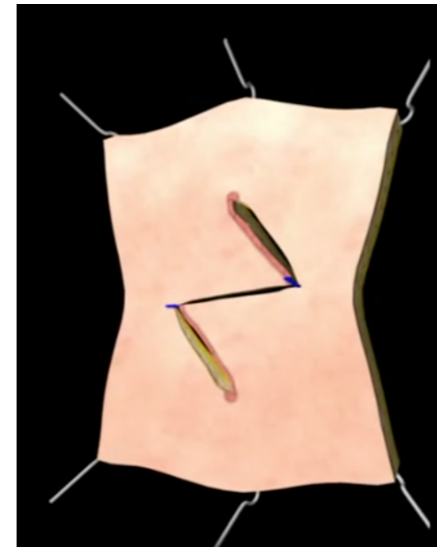
Scar



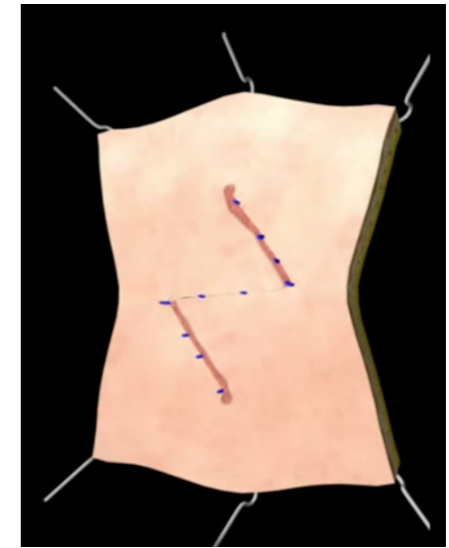
Incision



Transposition




Suturing

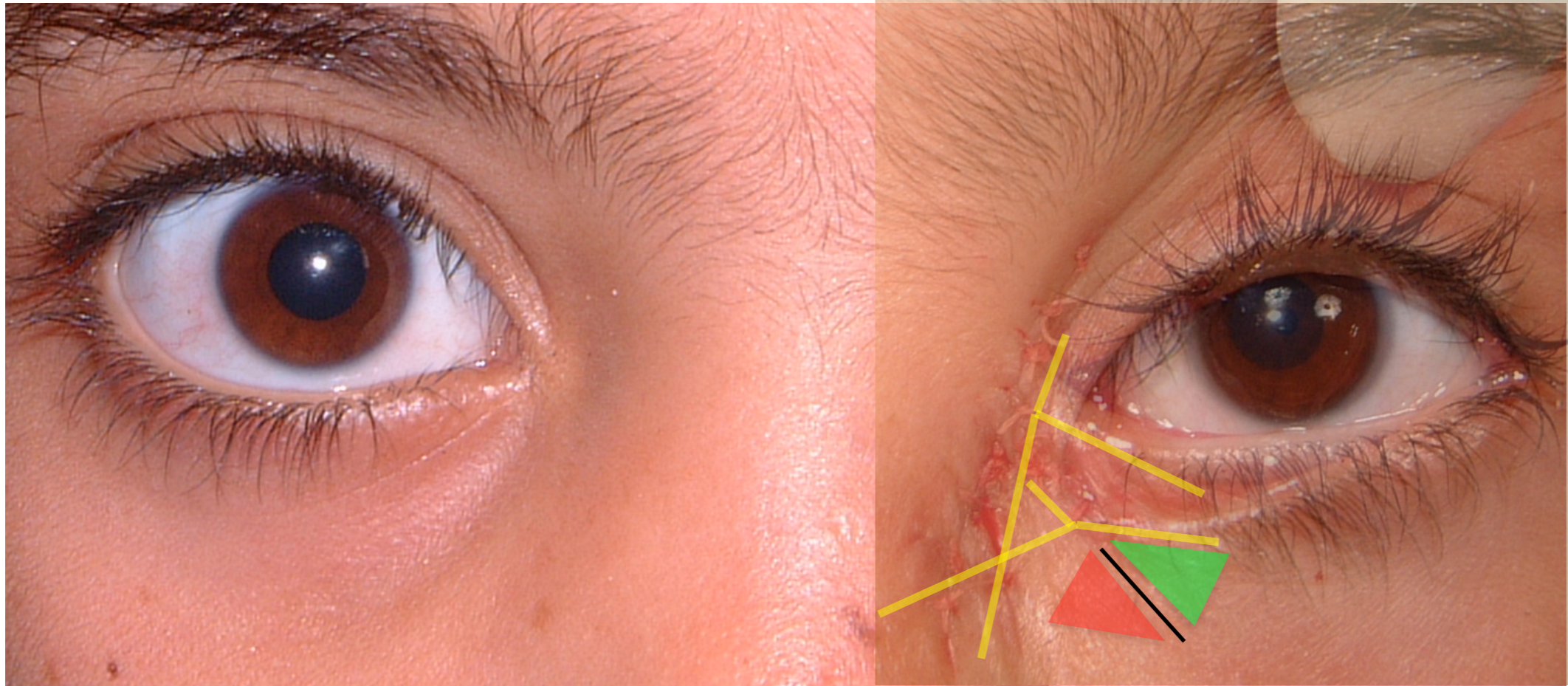


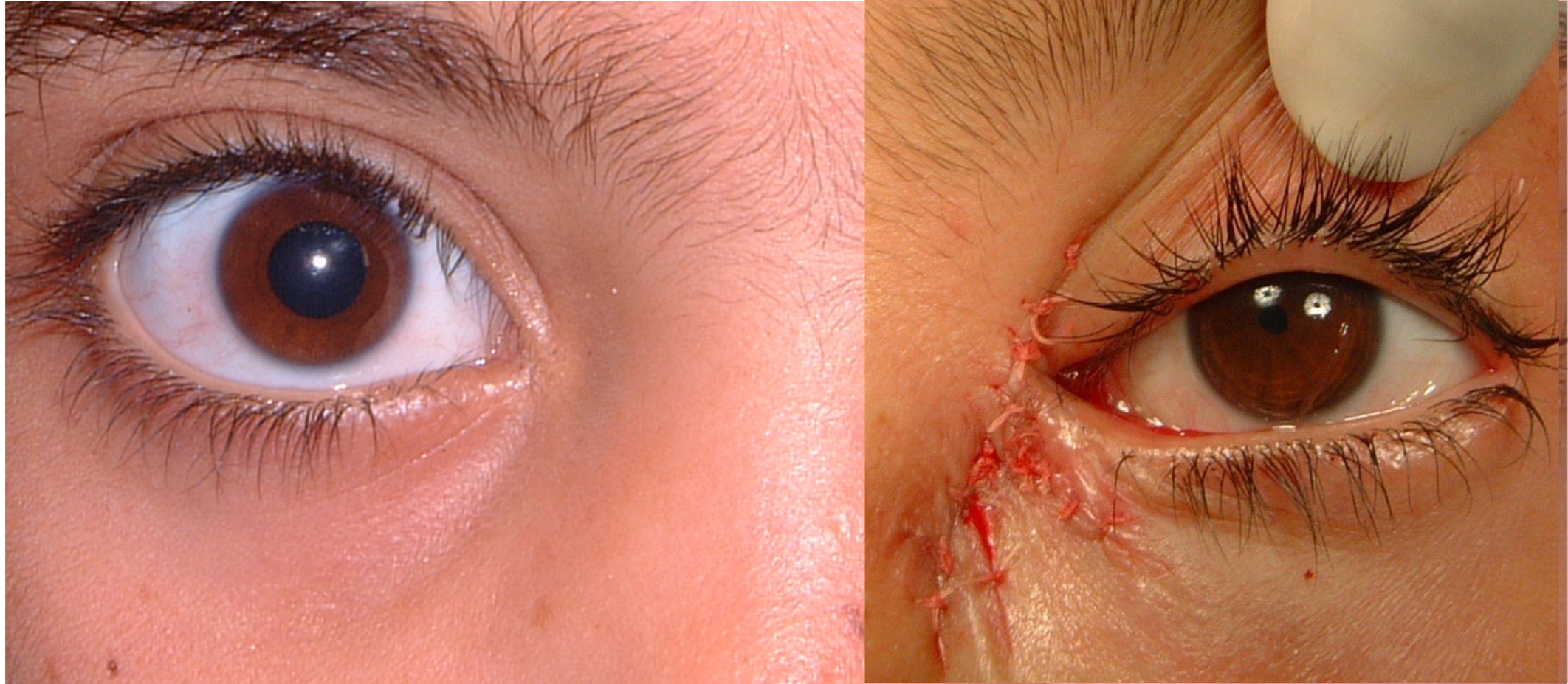


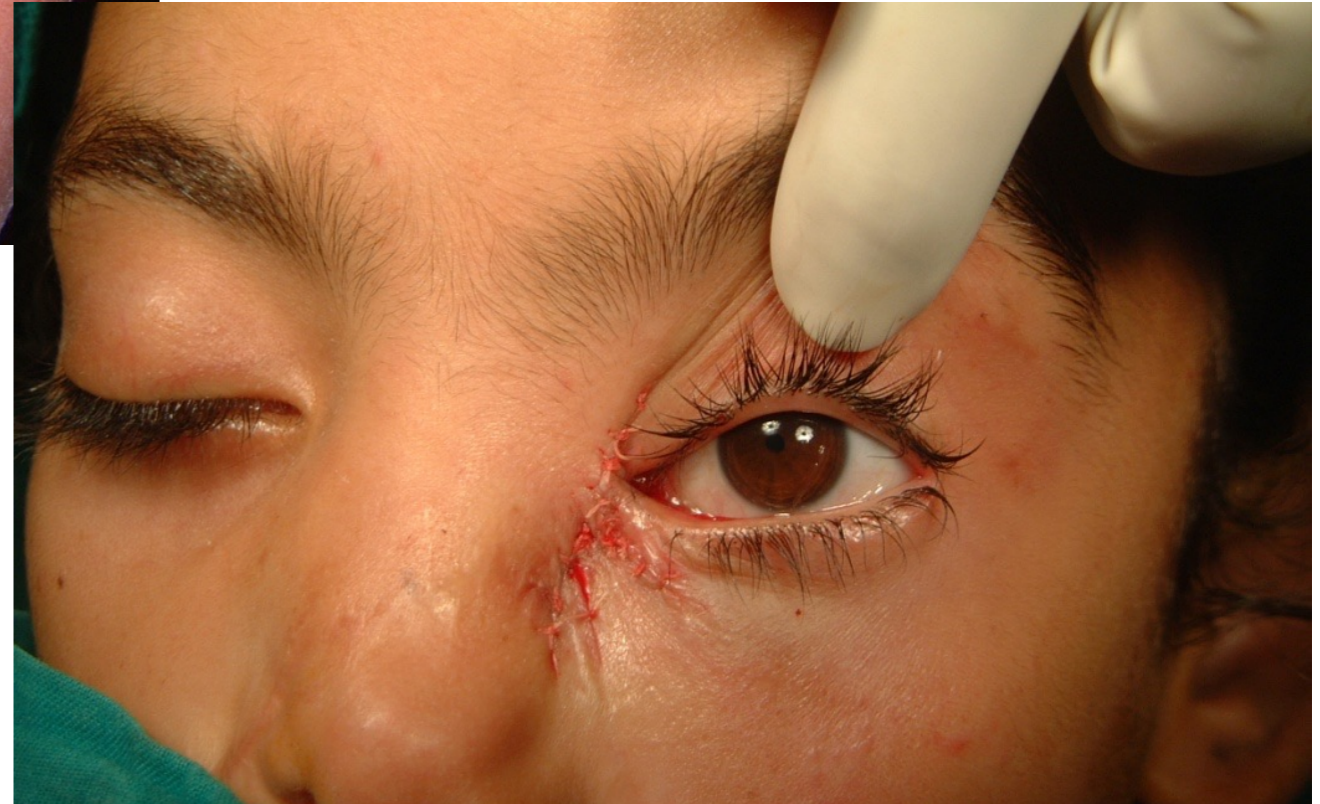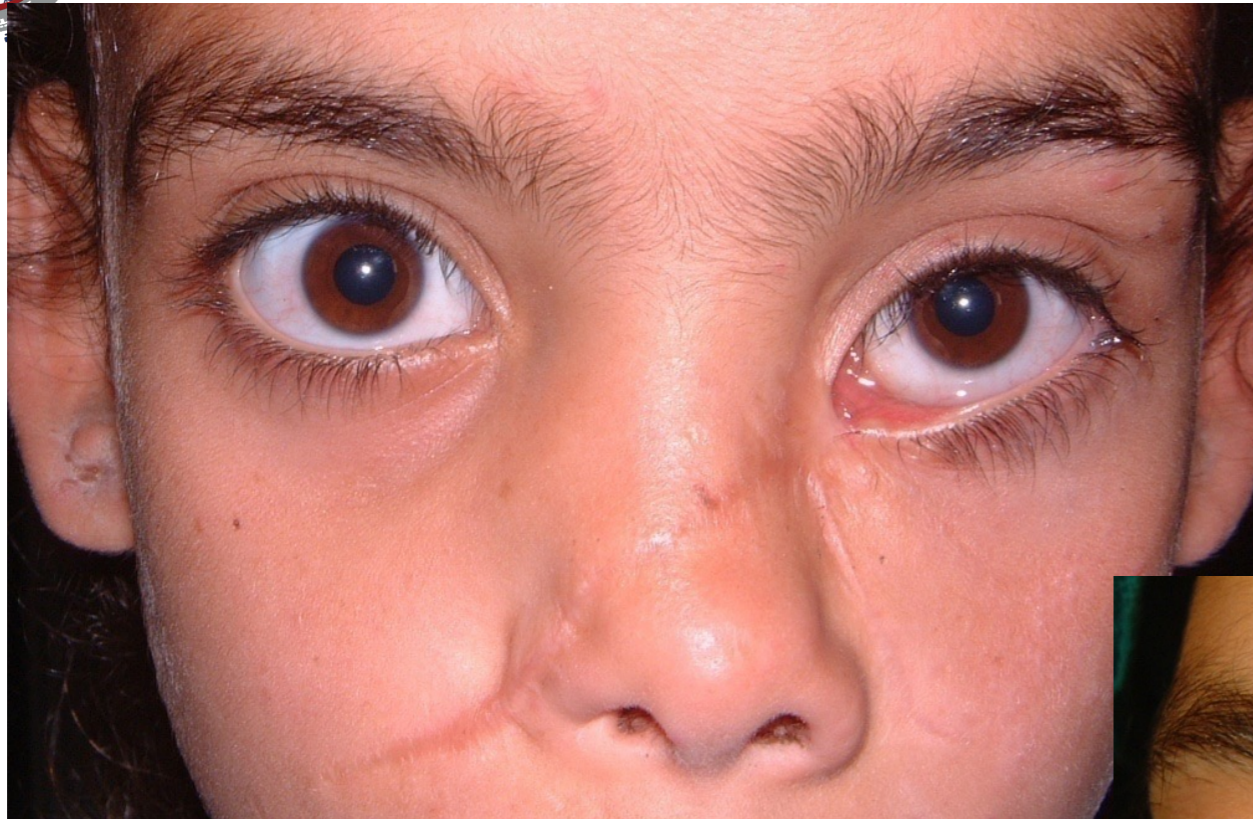Z-Plasty⁵



Sheriff Elwan, MD



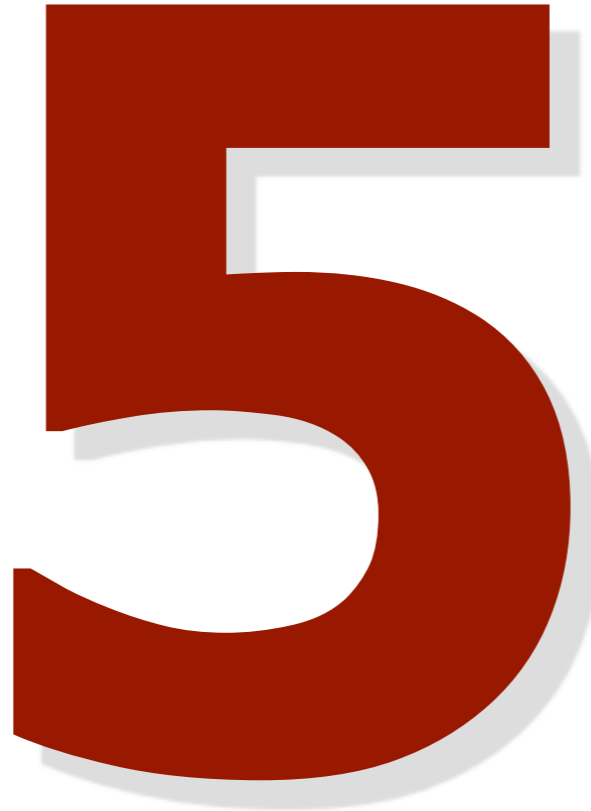





Mal-repair

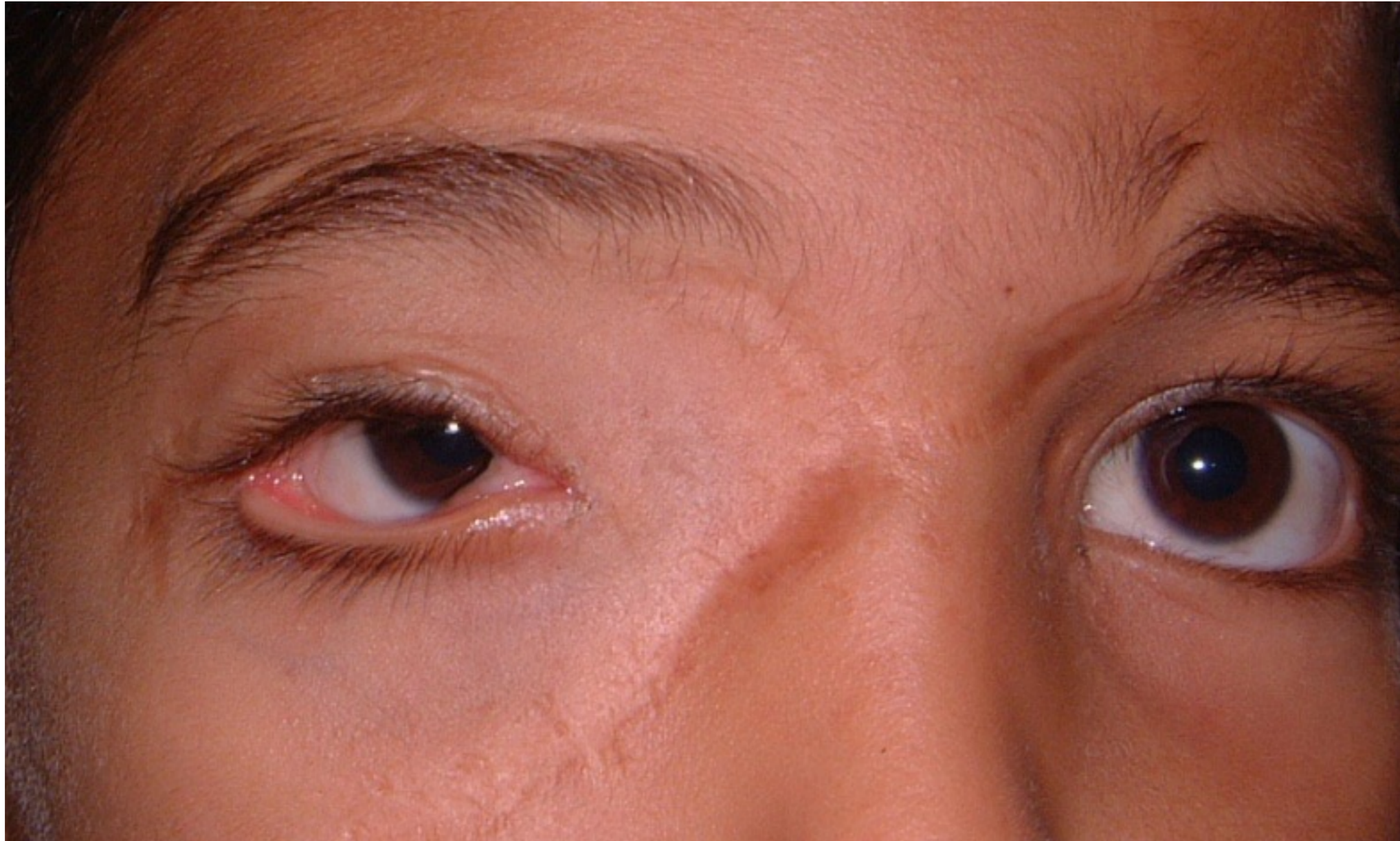
c. Bad Technique



Epicanthus

V-Y-plasty

Sheriff Elwan, MD



Sheriff Elwan, MD



V-Y Plasty

Indication:


Lengthening some anatomic structures..
Covering defects.

Composition:

V->Y : Recession


Y->V : Advancement

Sheriff Elwan, MD

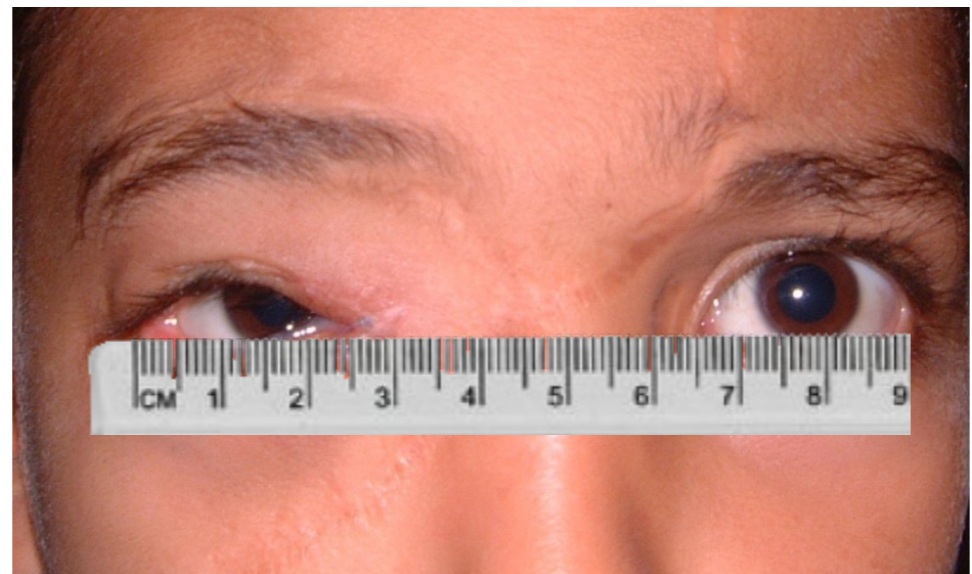
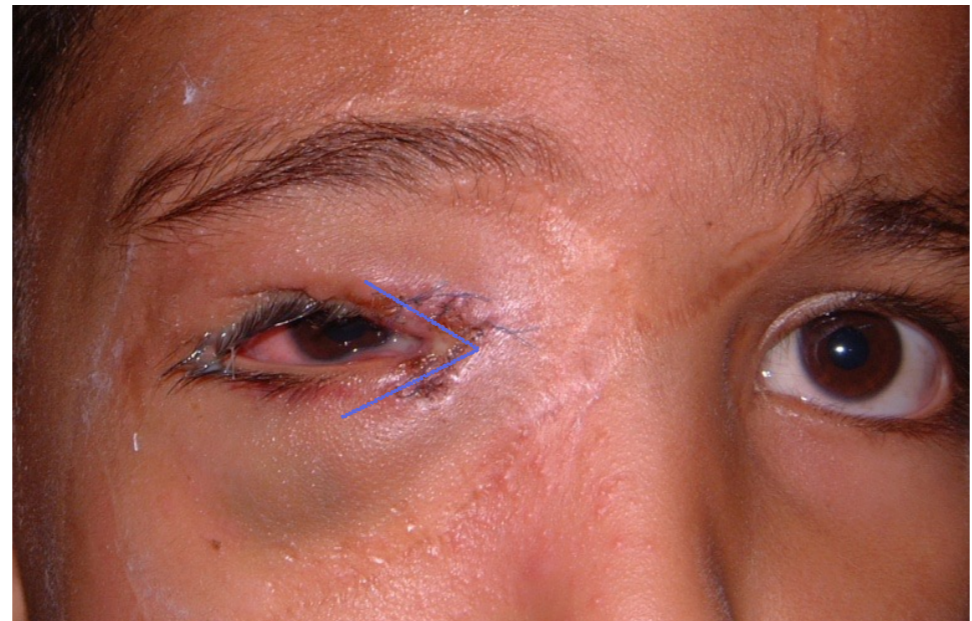
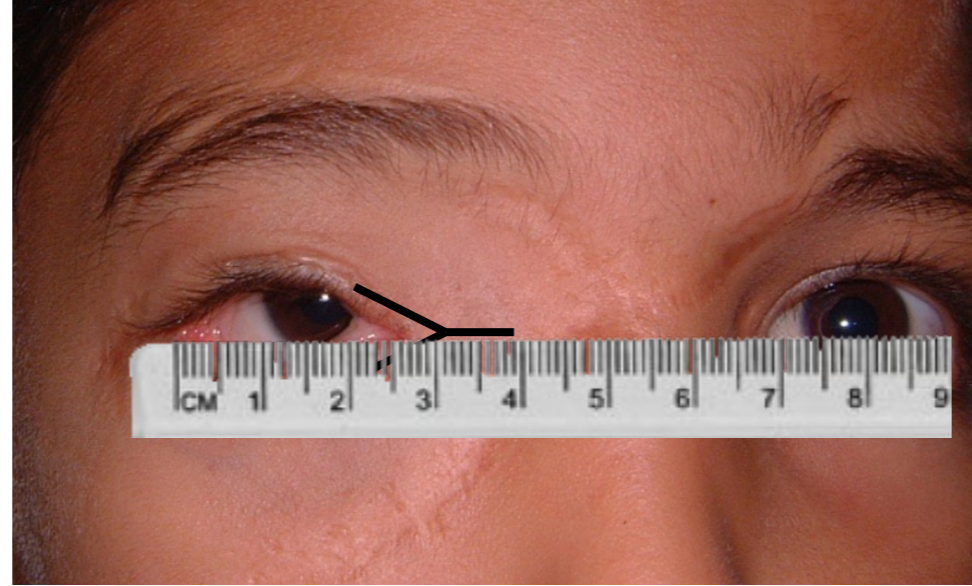


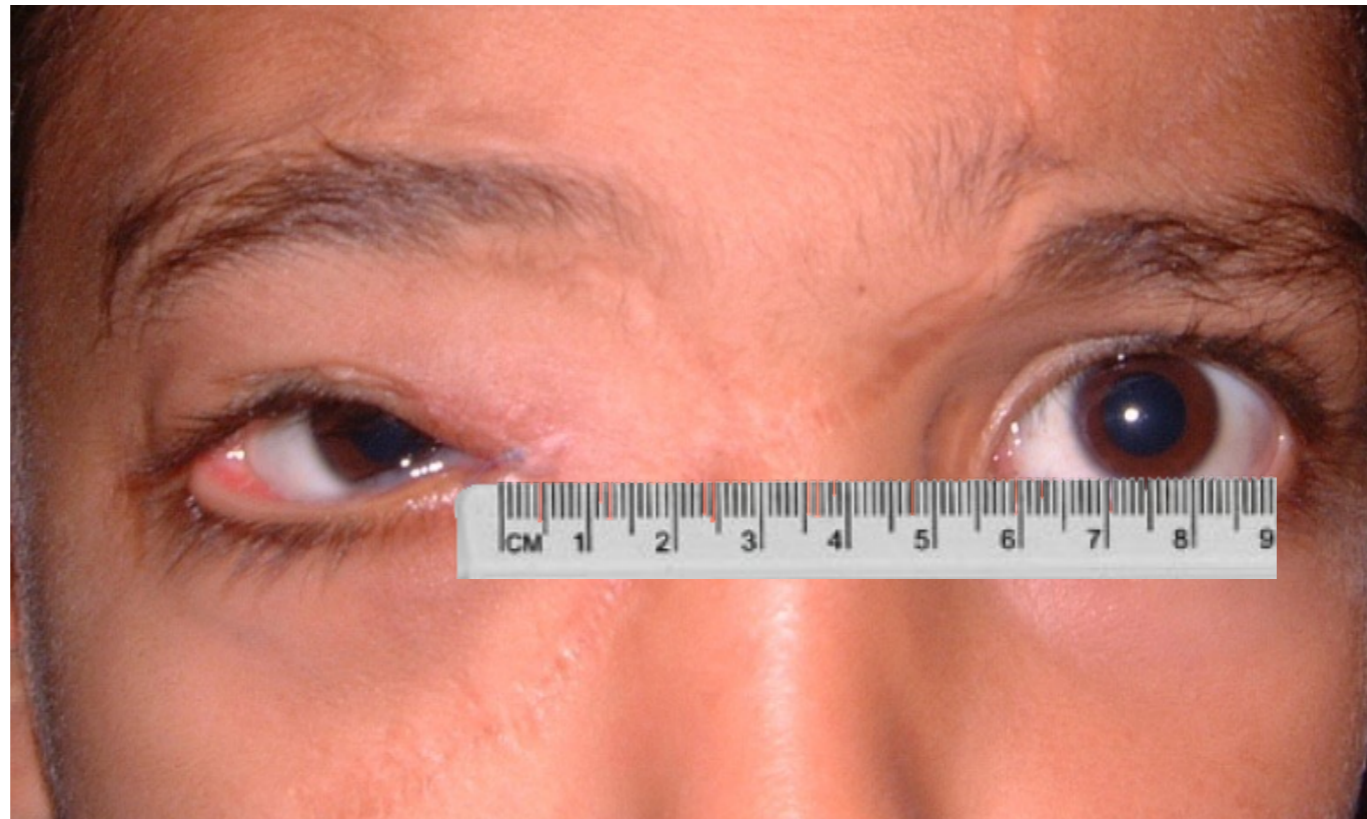
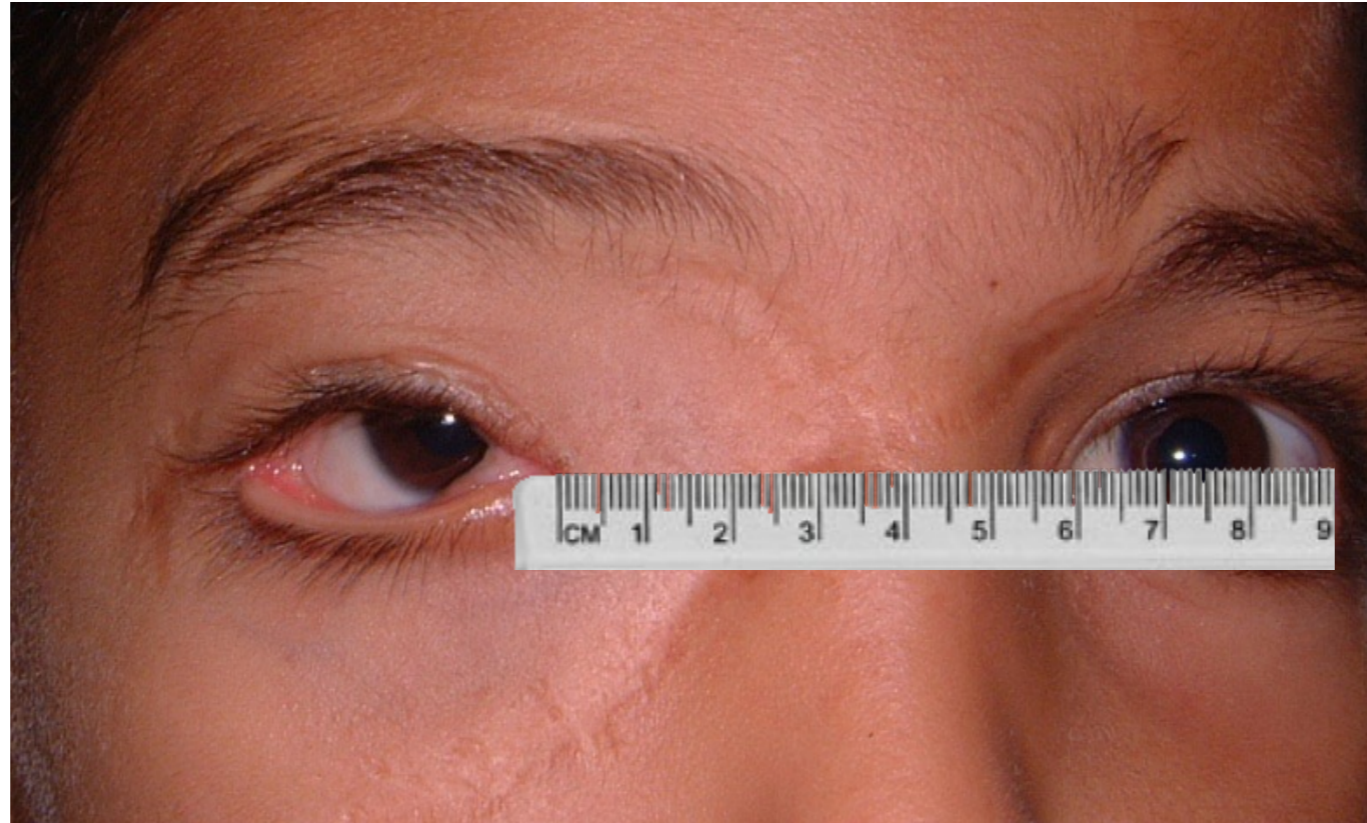
Y-V Plasty

Sheriff Elwan, MD



Y-V Plasty



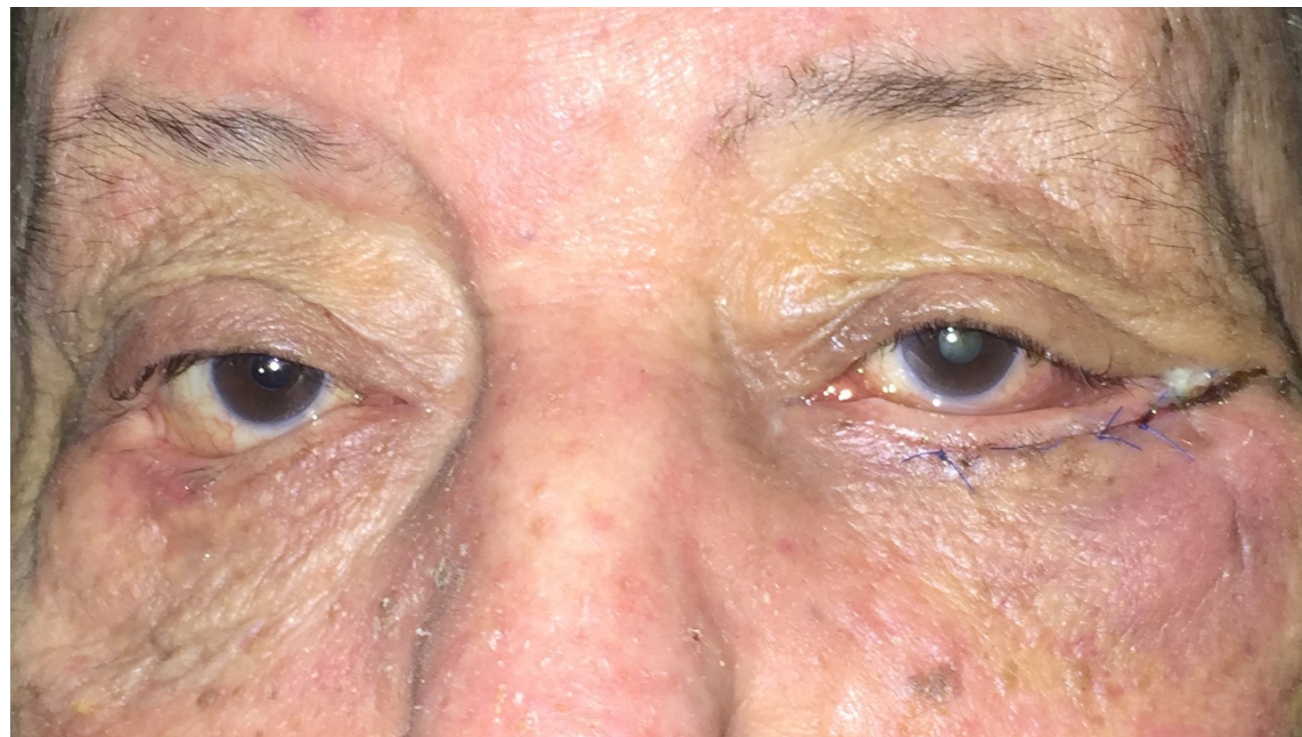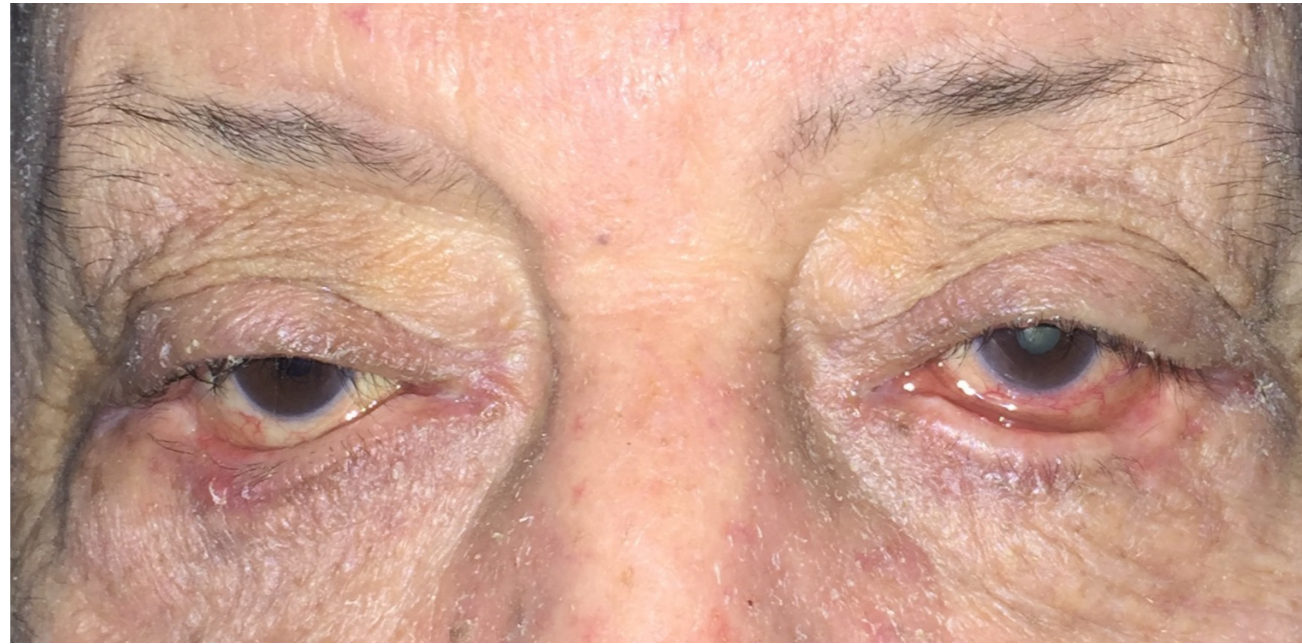




6

Ectropion Following Lower Blepharoplasty

Sheriff Elwan, MD



(1) Lateral Tarsal Sling

(2) Mid-face Lift

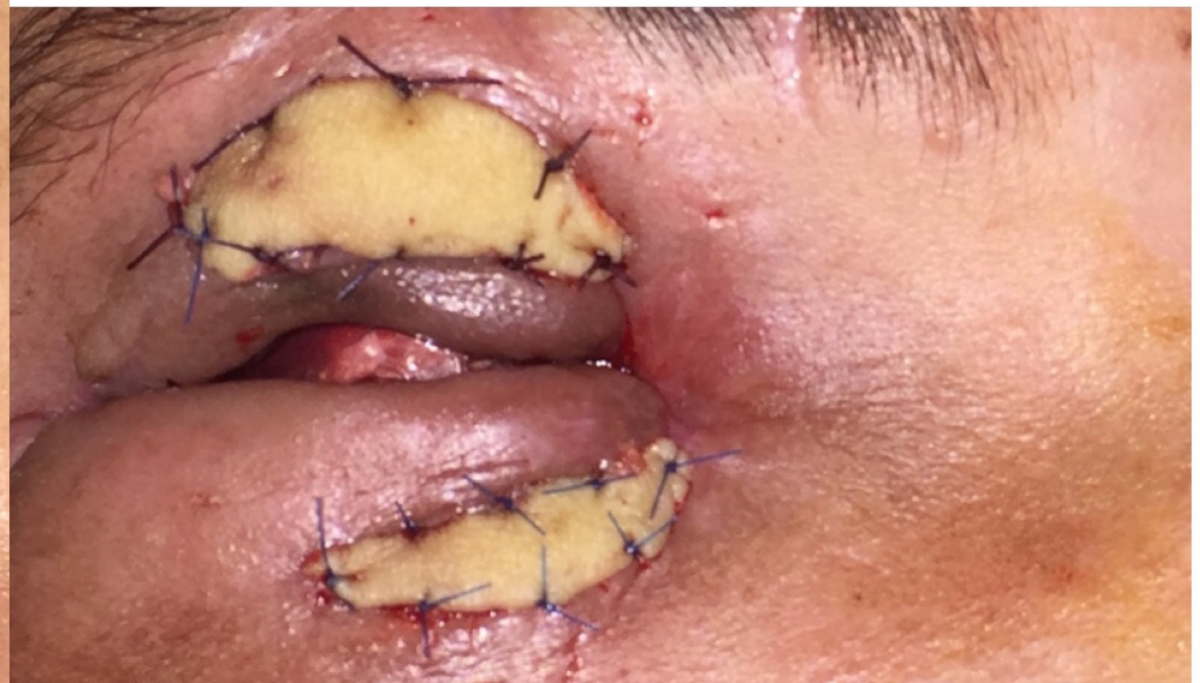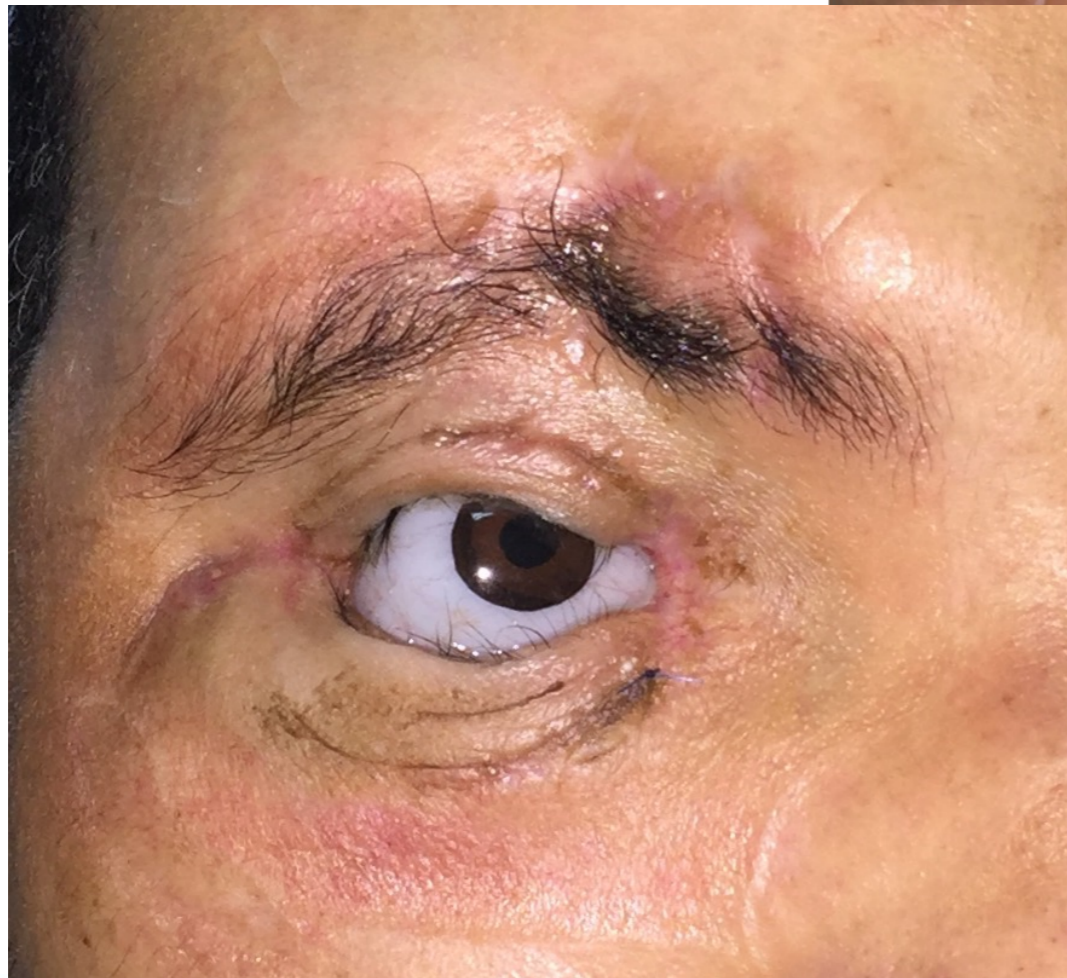
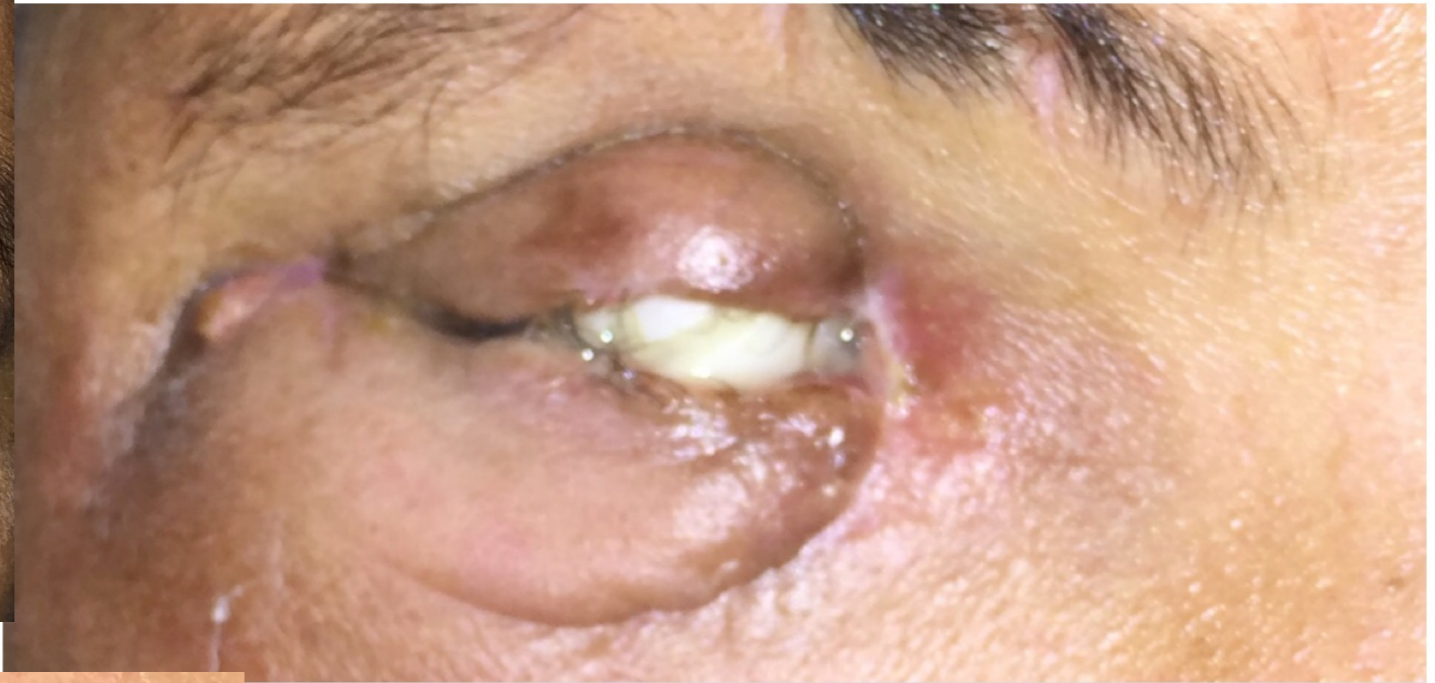
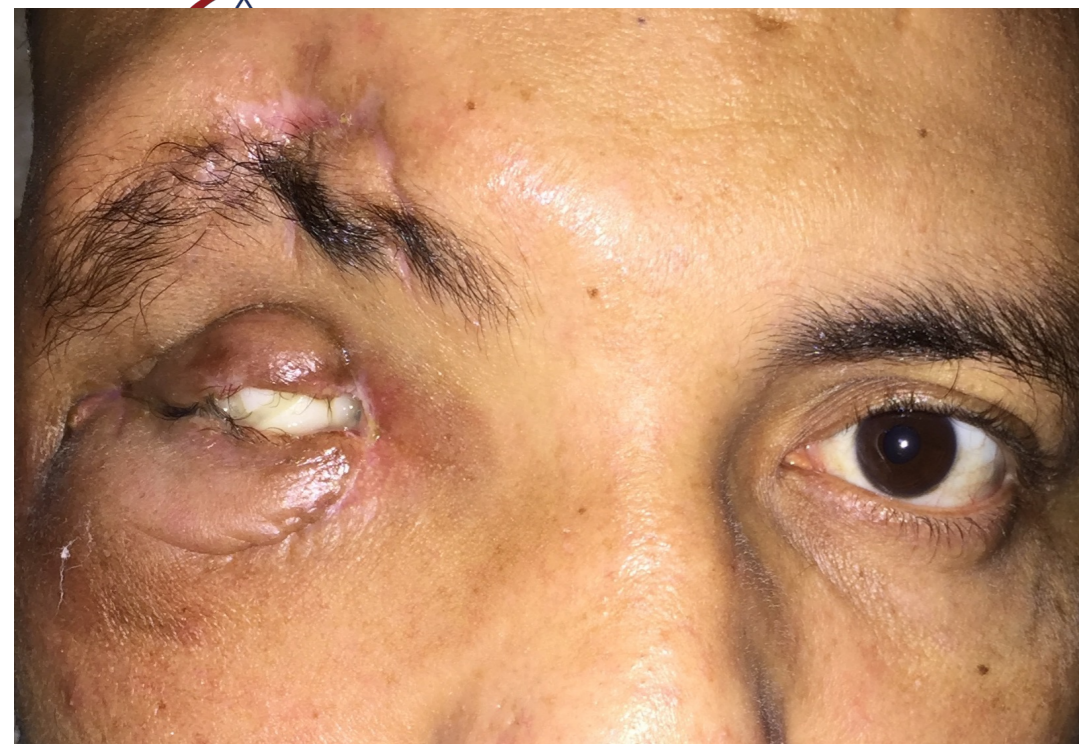Sheriff Elwan, MD



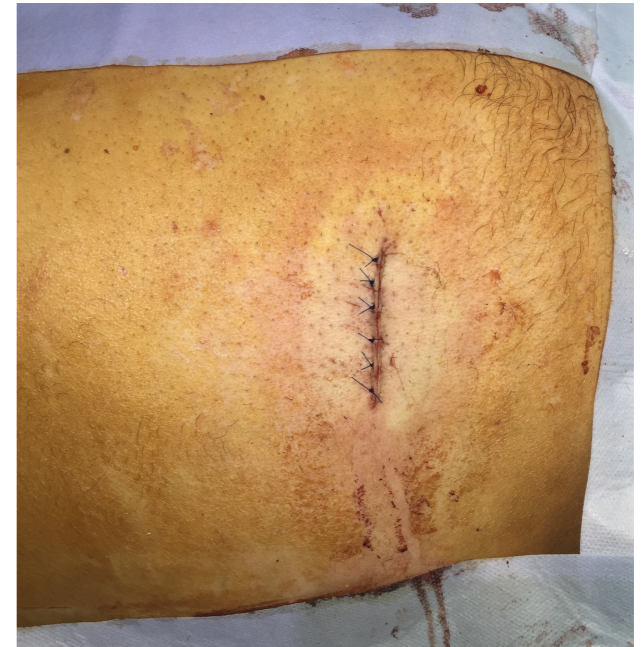
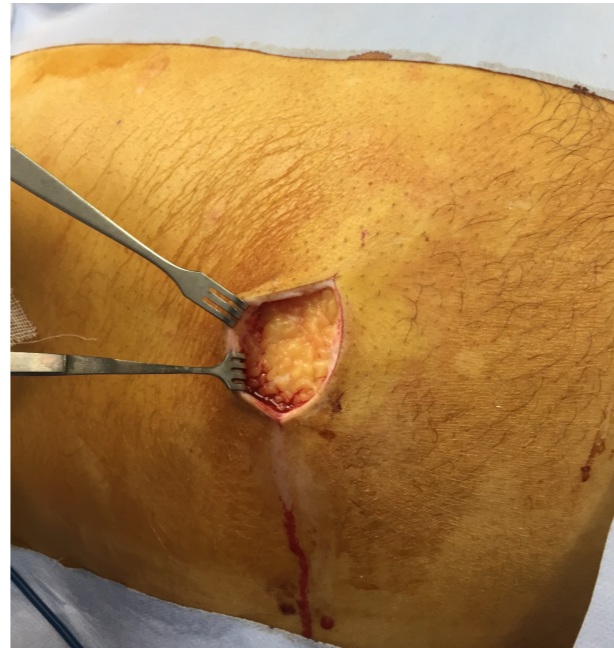
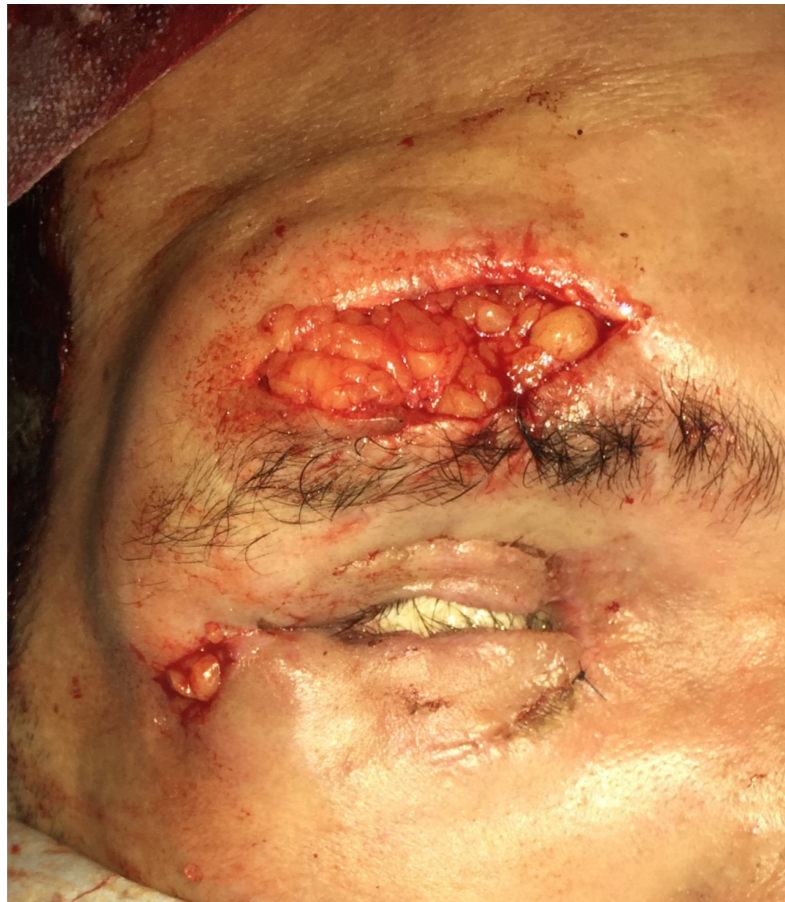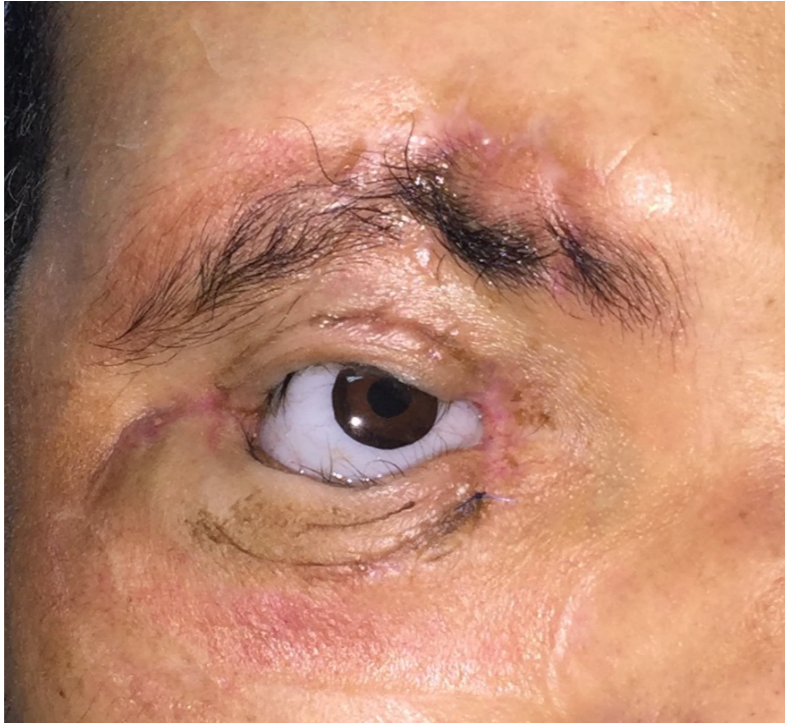
8

Inexperienced Primary Repair

Sheriff Elwan, MD



Sheriff Elwan, MD





THANK YOU

Sheriff Elwan, MD