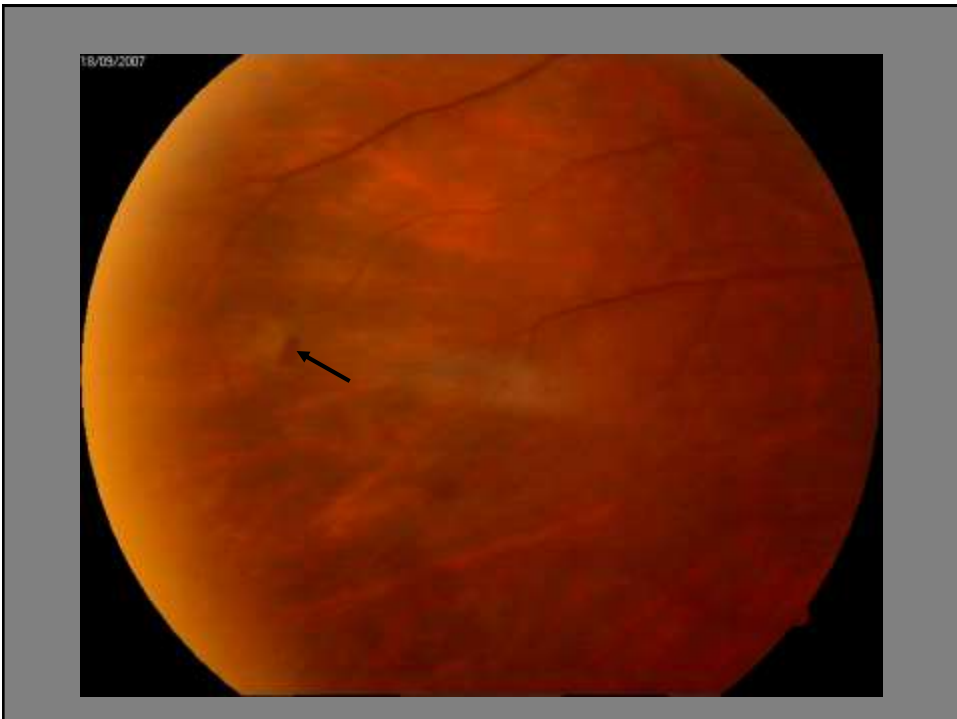
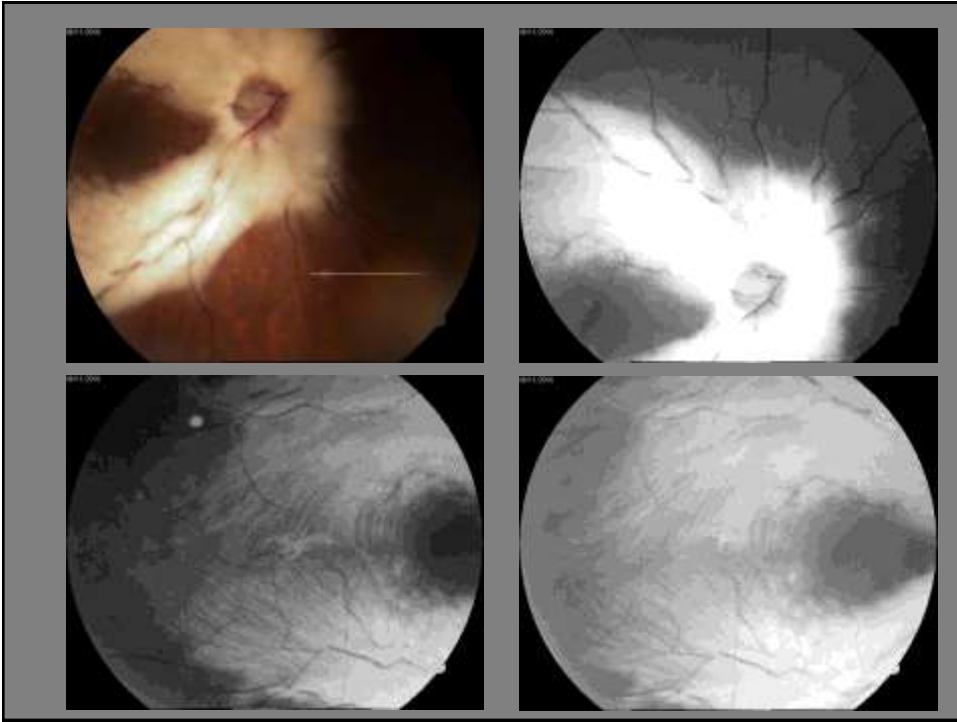


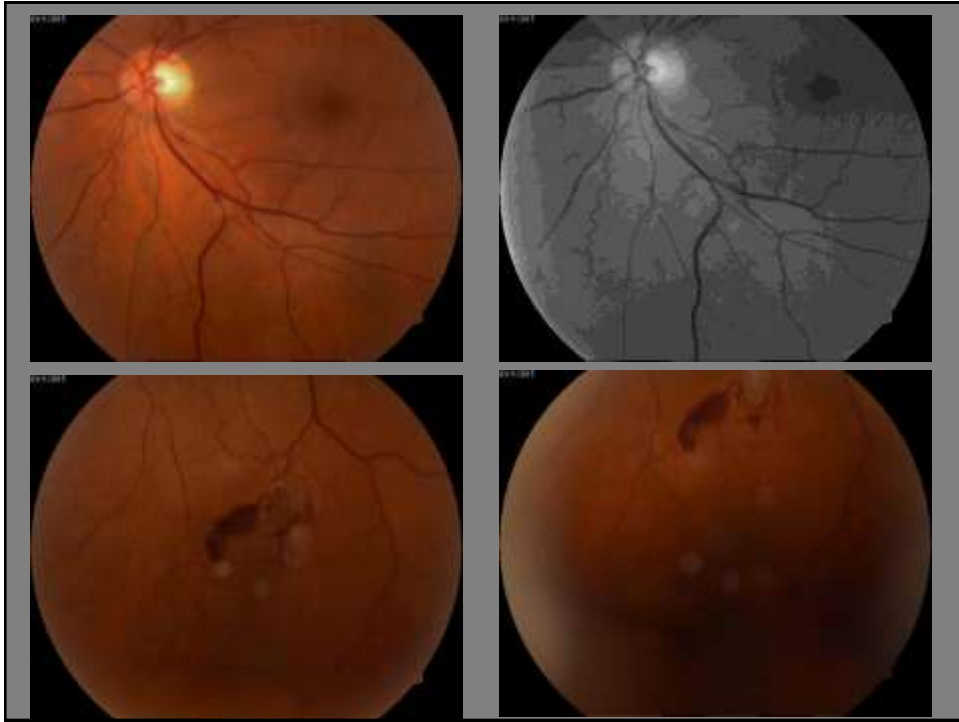
Common Mistakes That Can Affect The Diagnosis of FFA

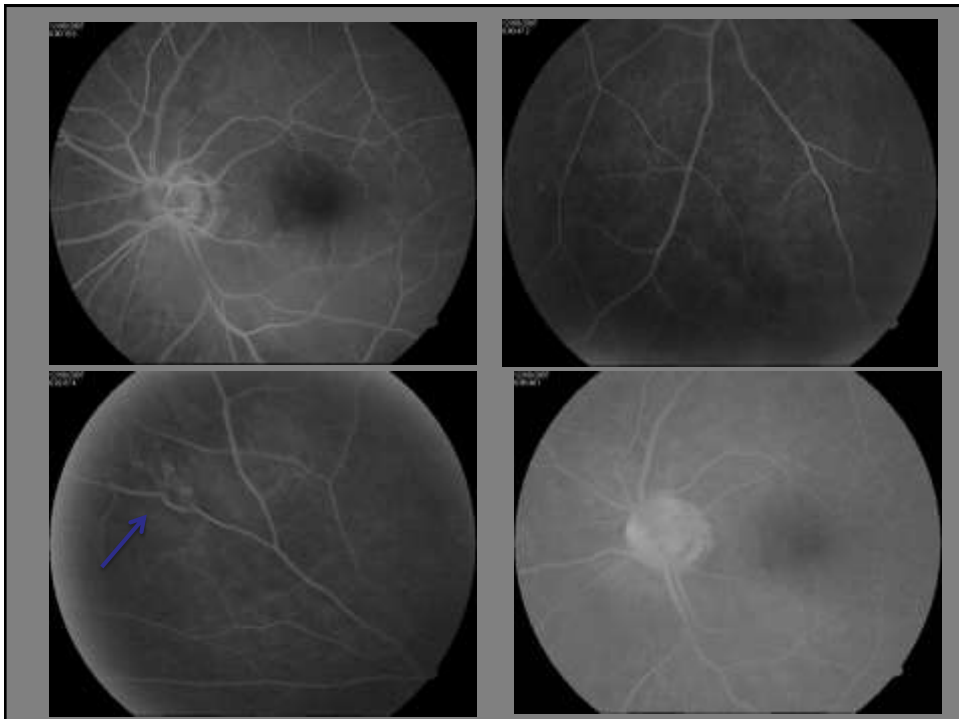
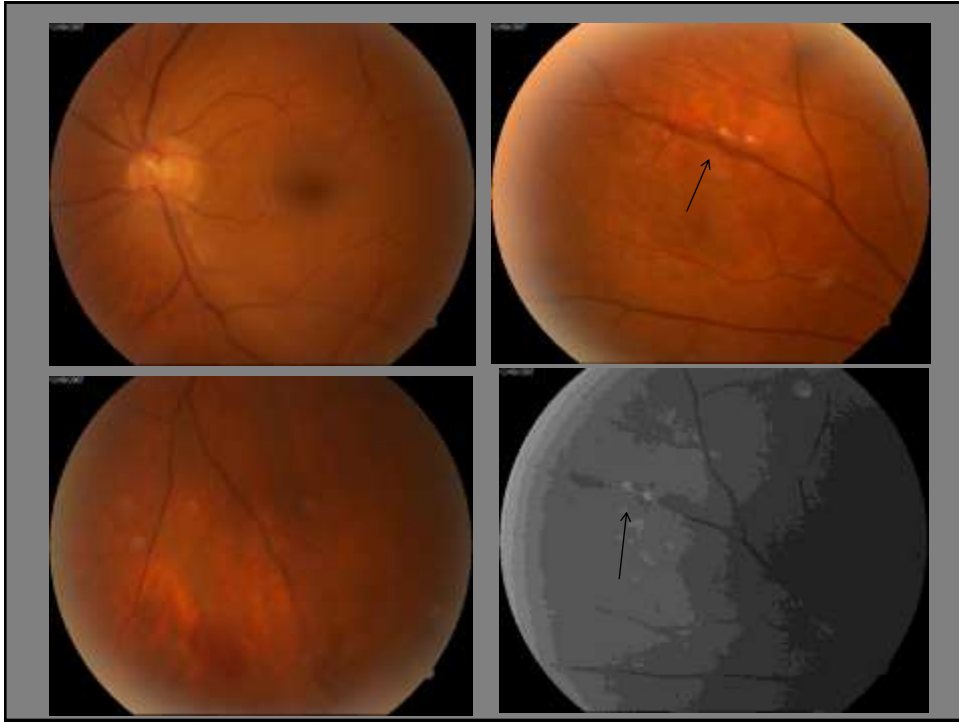
By

Hanem Kishk

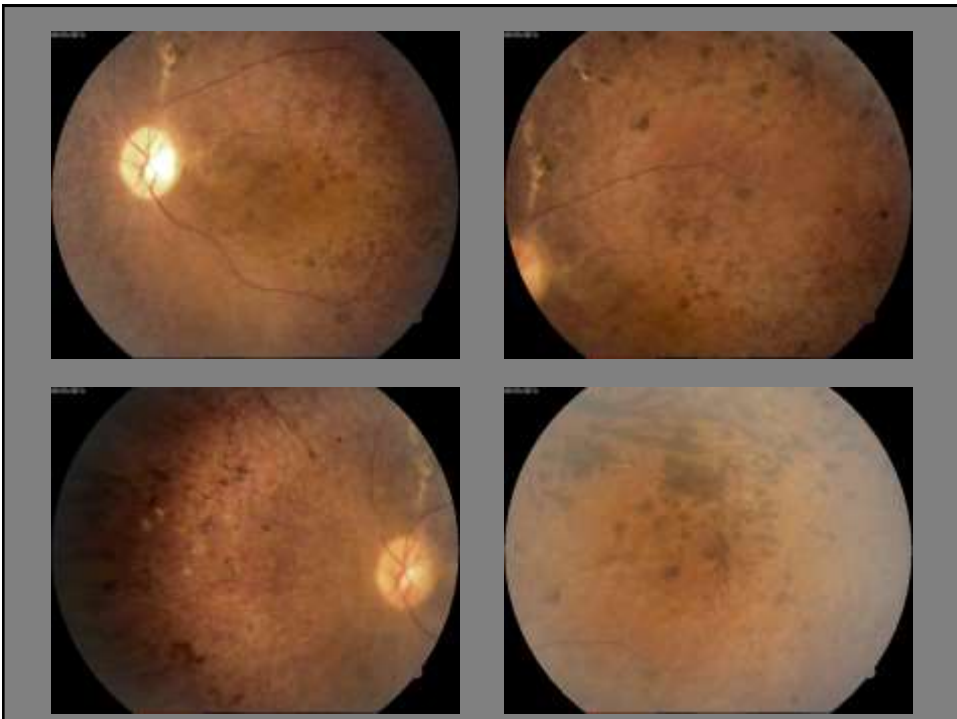
Never inject fluorescein when your
are concluding that it is not
indicated

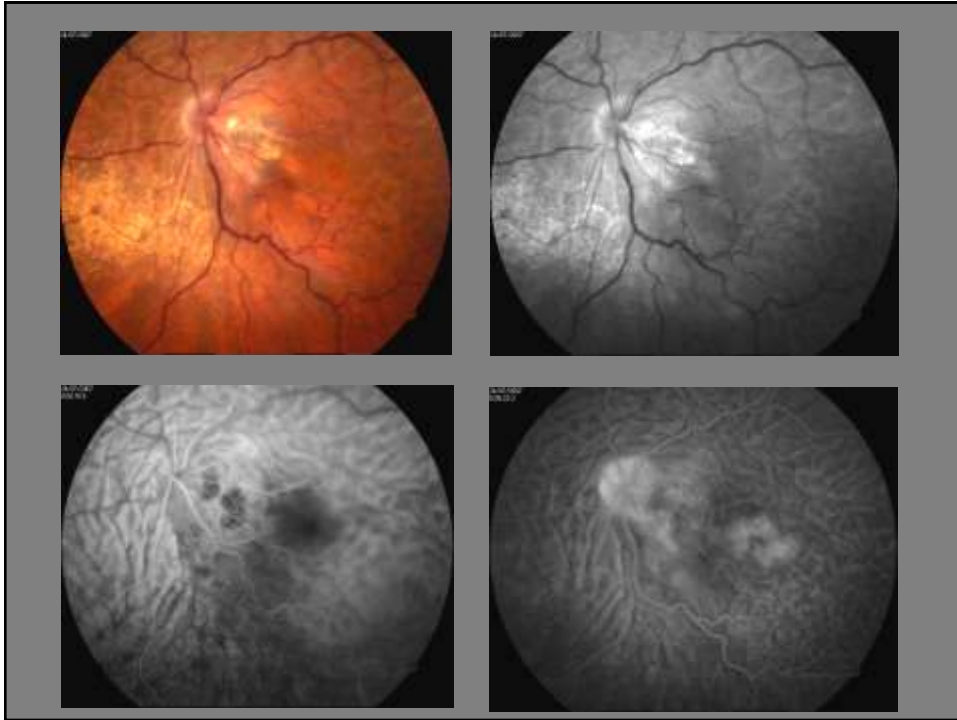




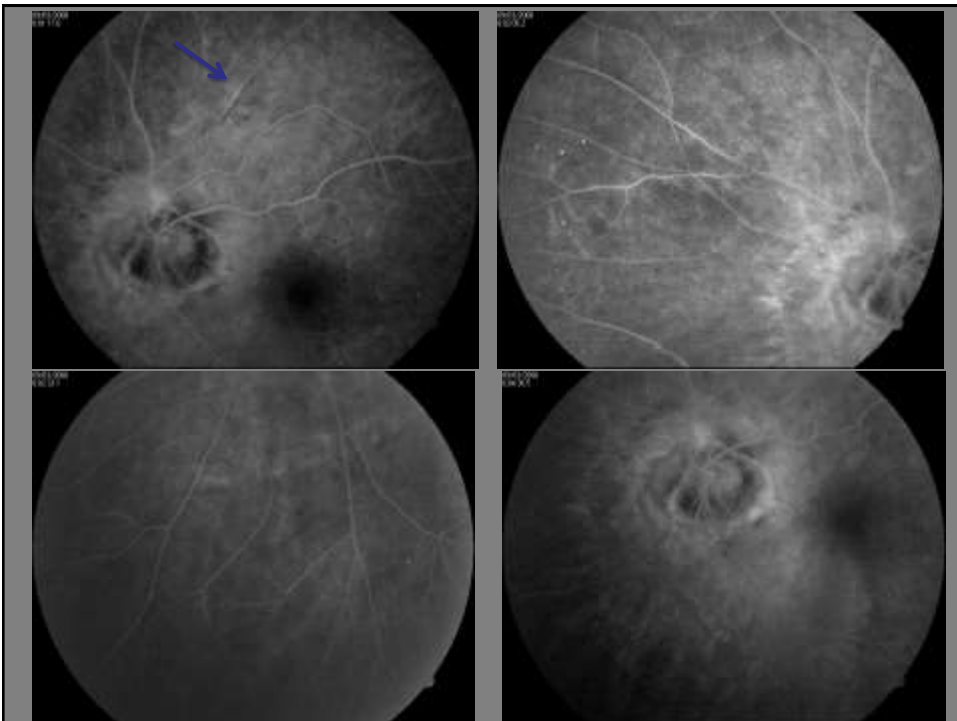
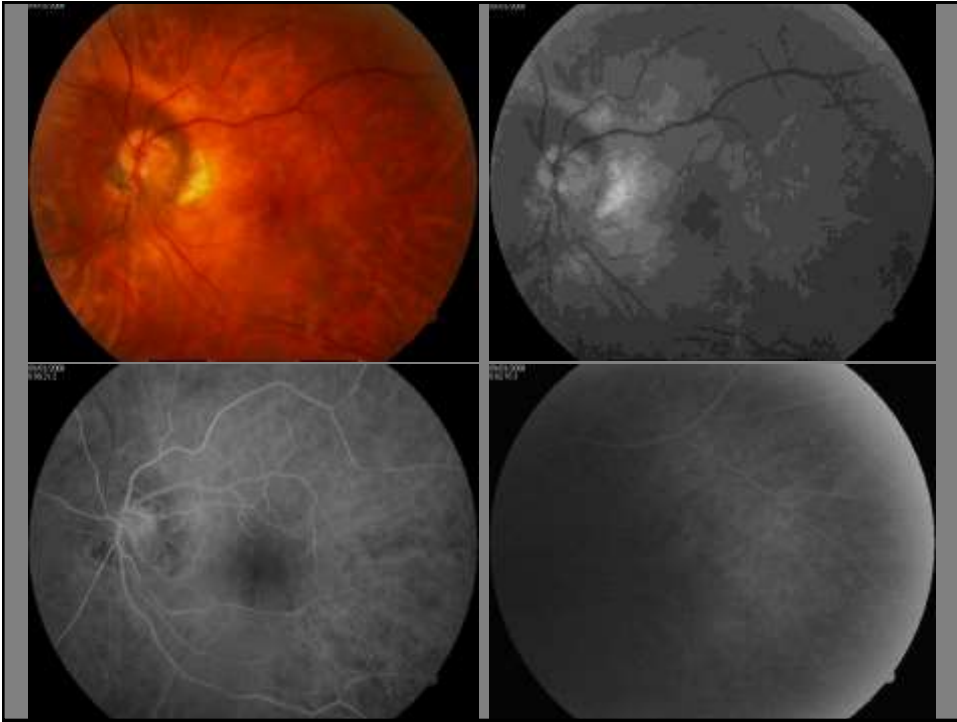


Never Be Misled by The
Provisional Diagnosis Given by The
referring Physician



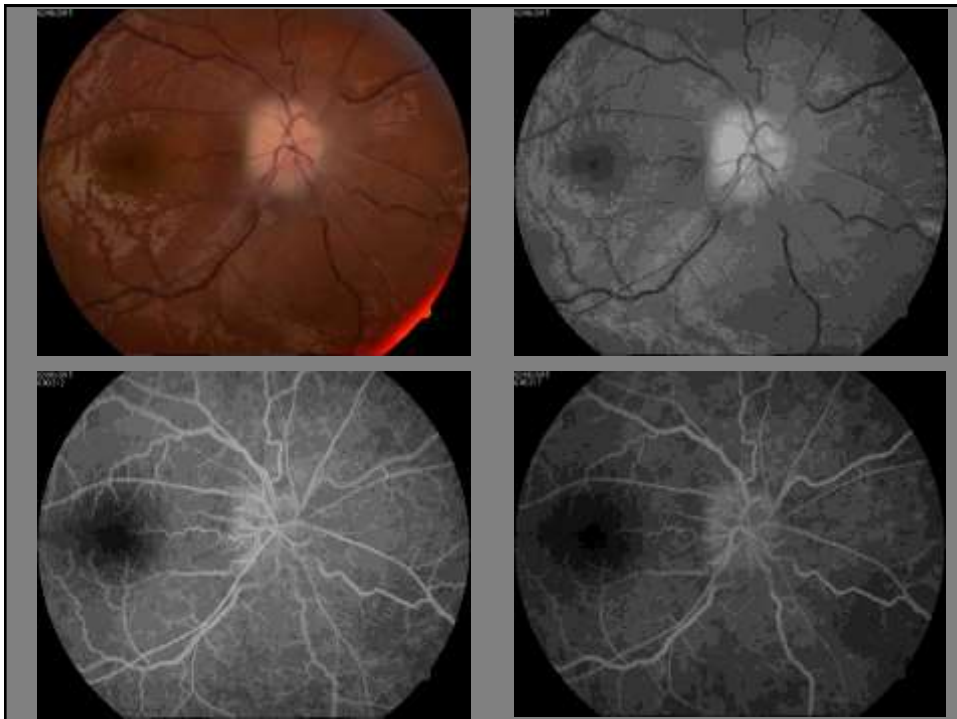

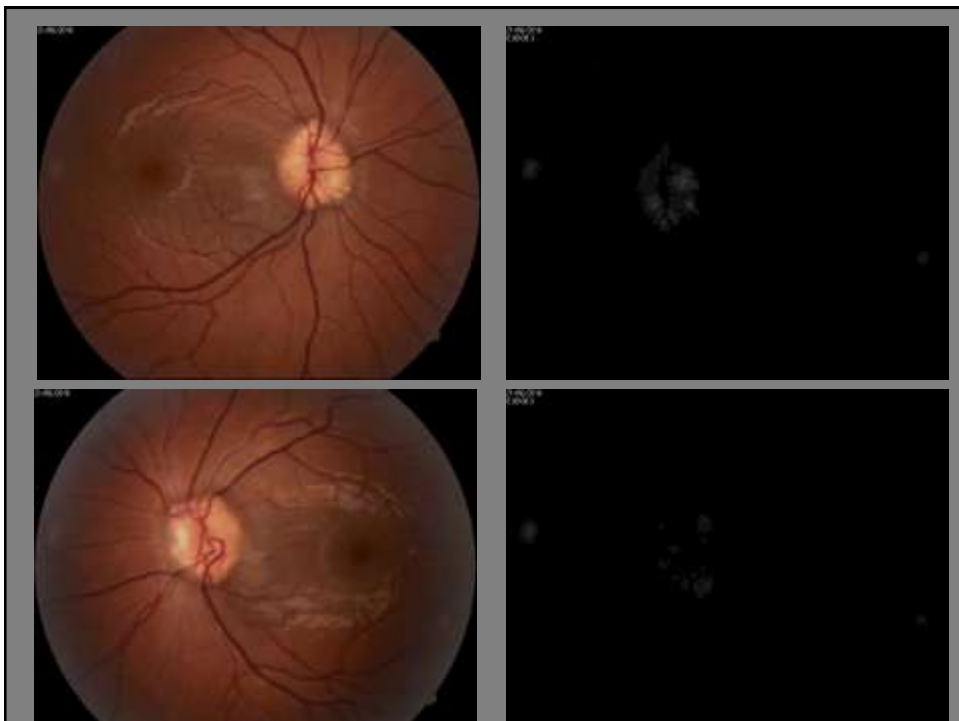
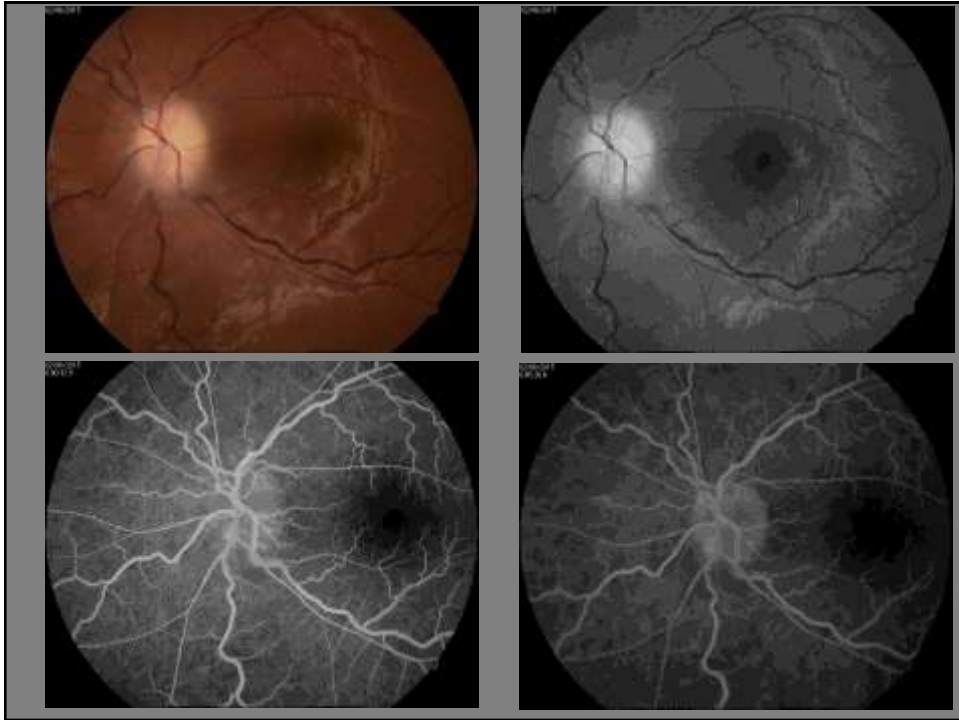
**Never Give a Diagnosis Based on
Your Anticipation during Fundus
Examination Before The injection**

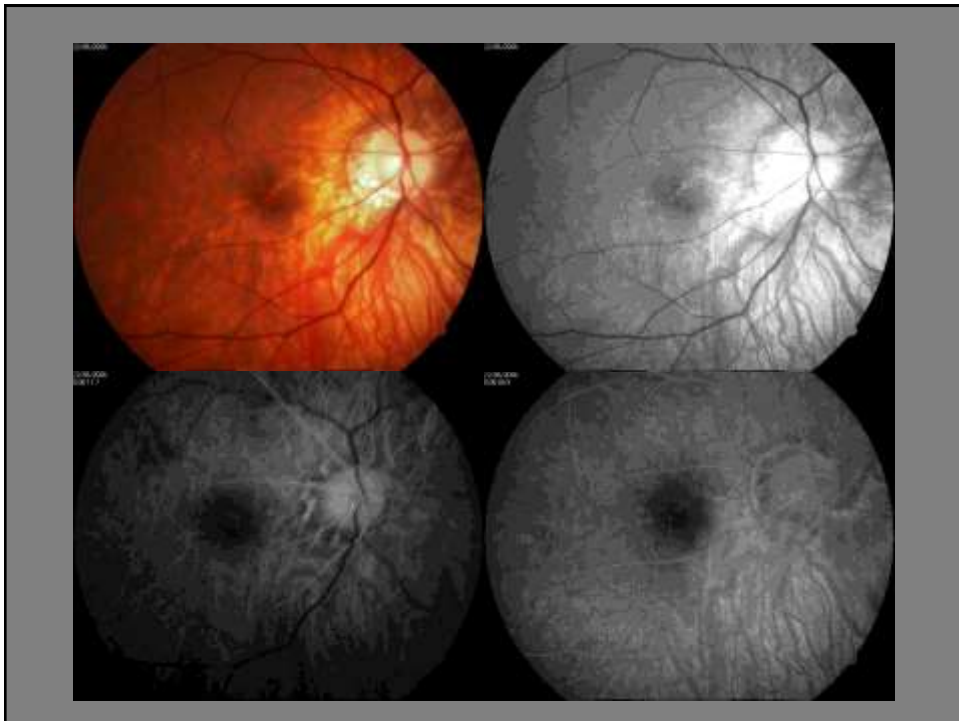
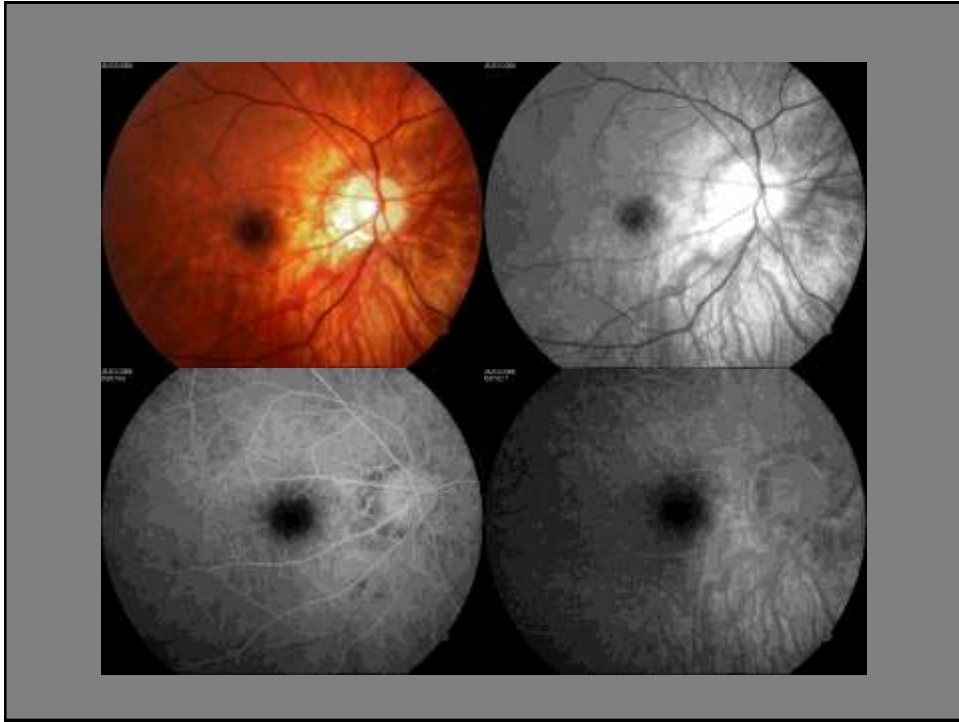




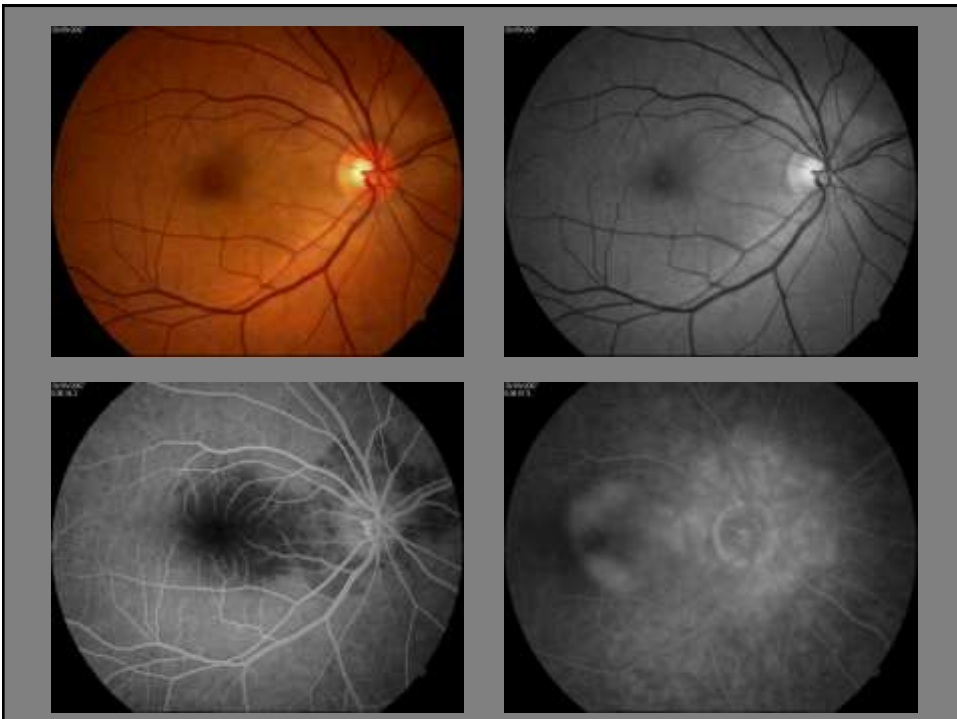
Movie_0001.wmv

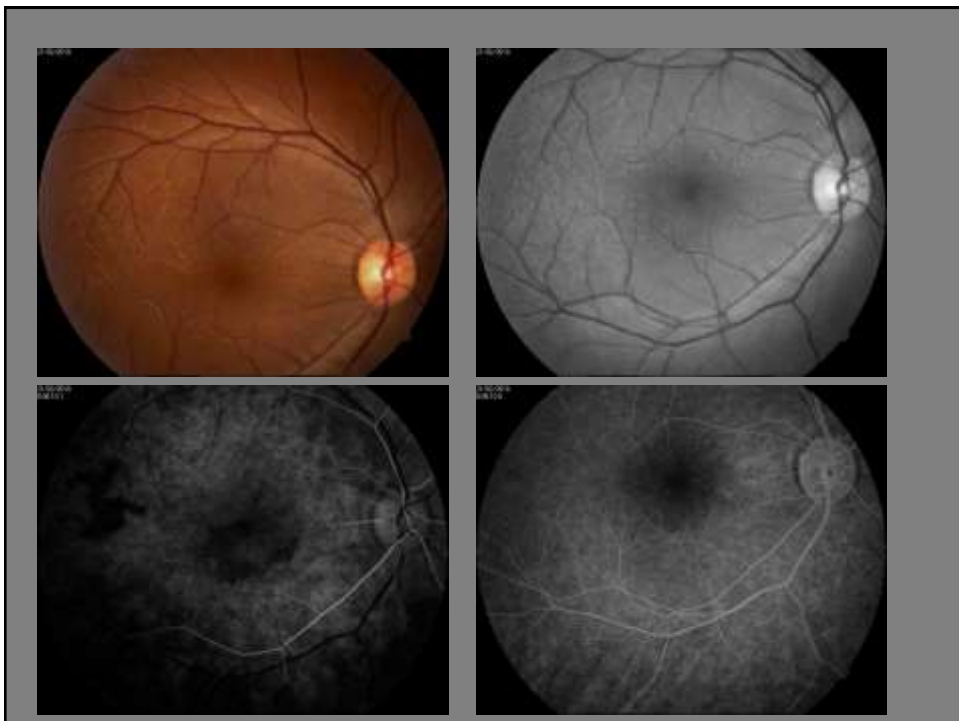
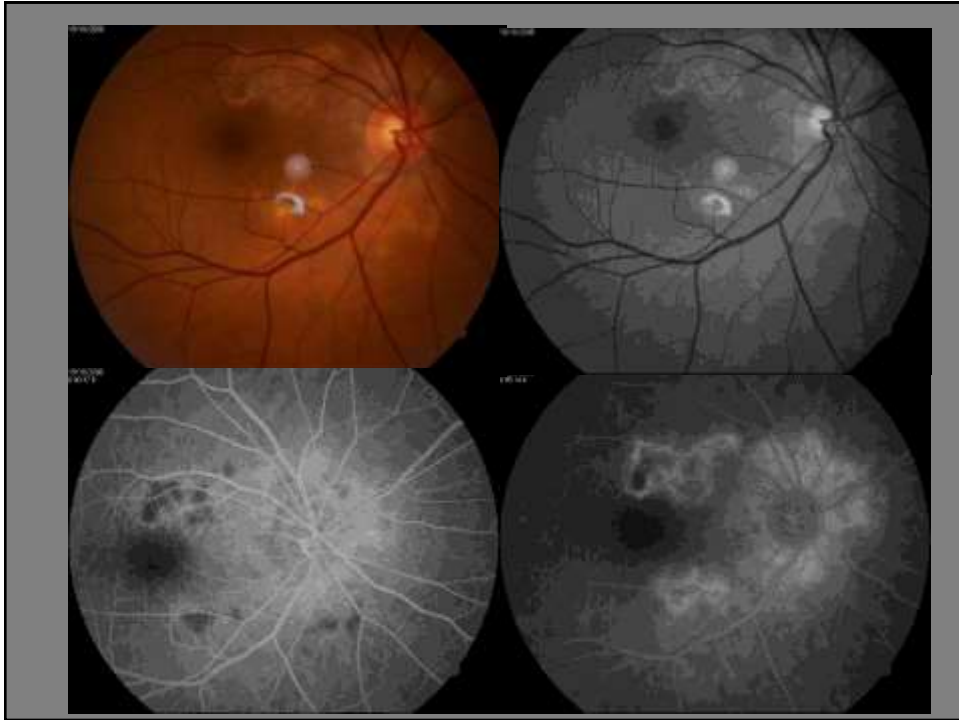

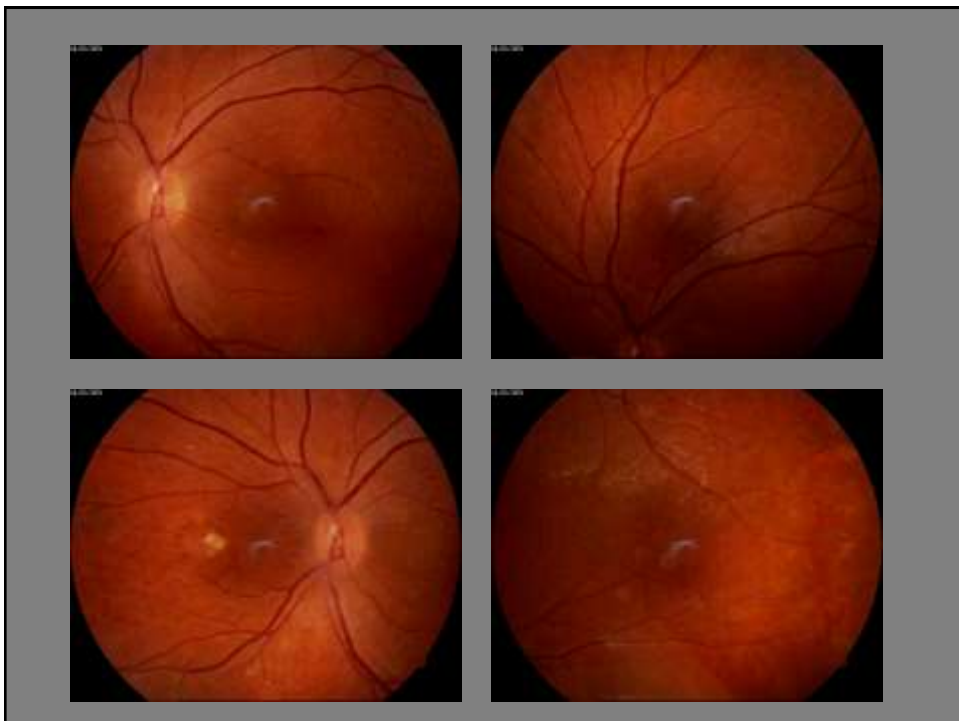
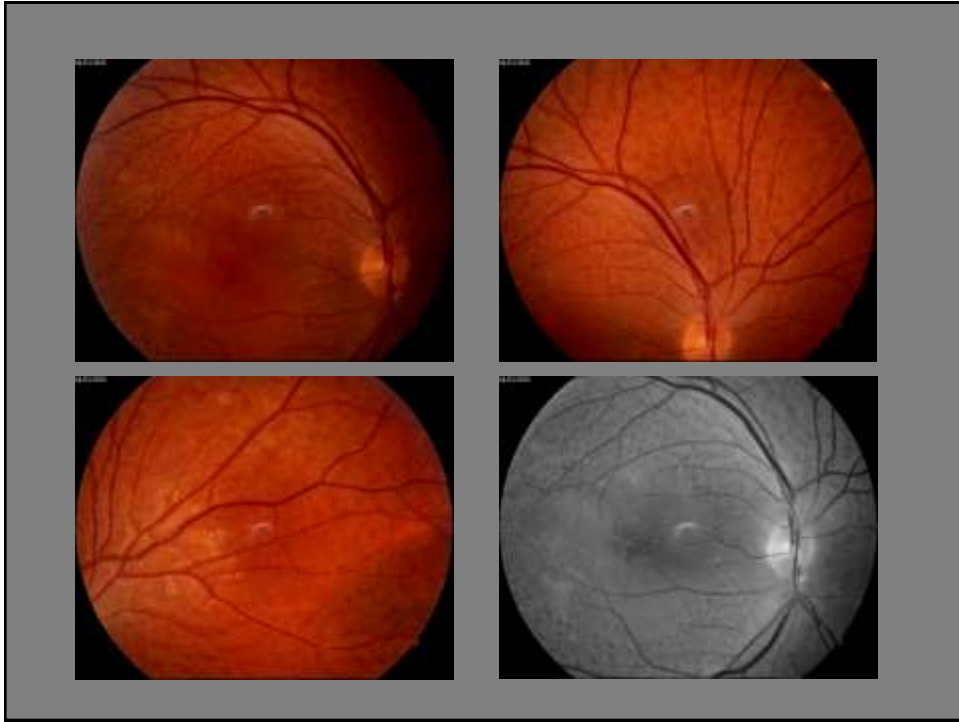


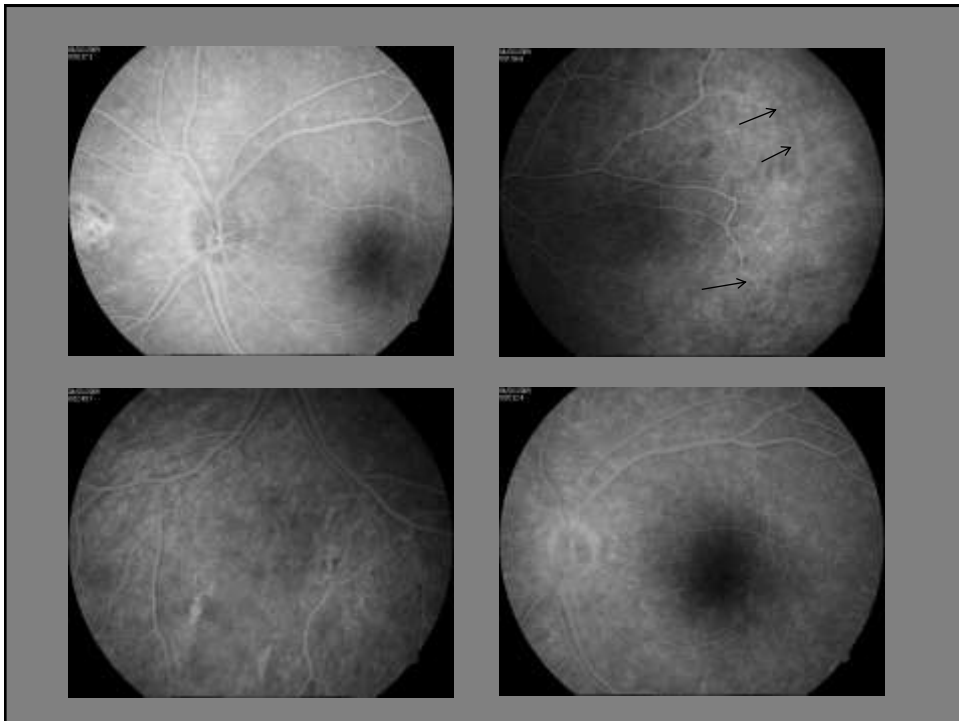
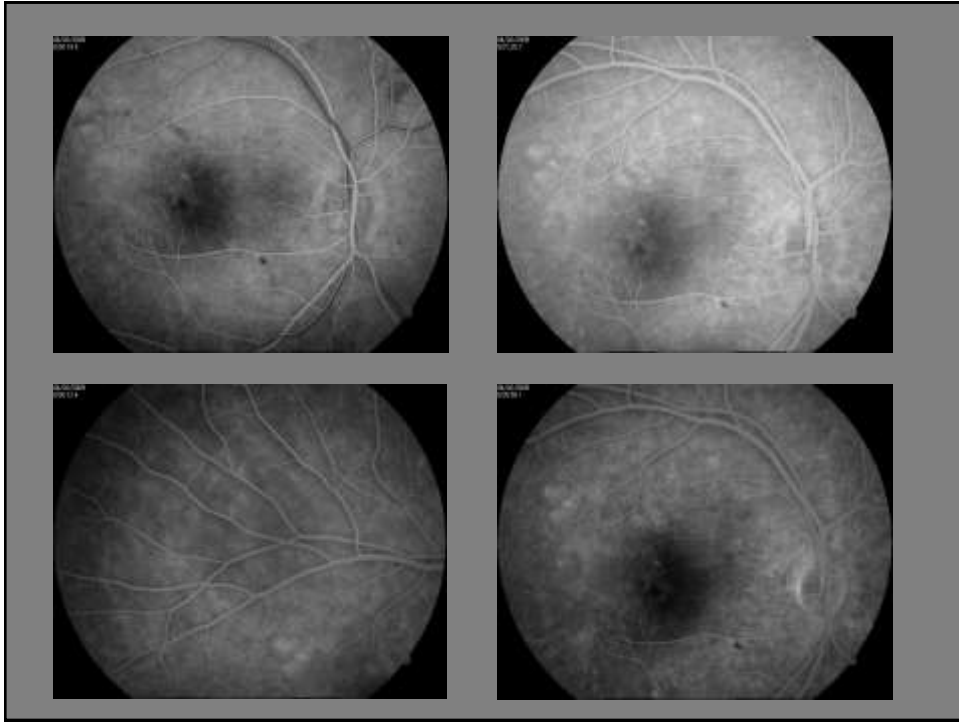


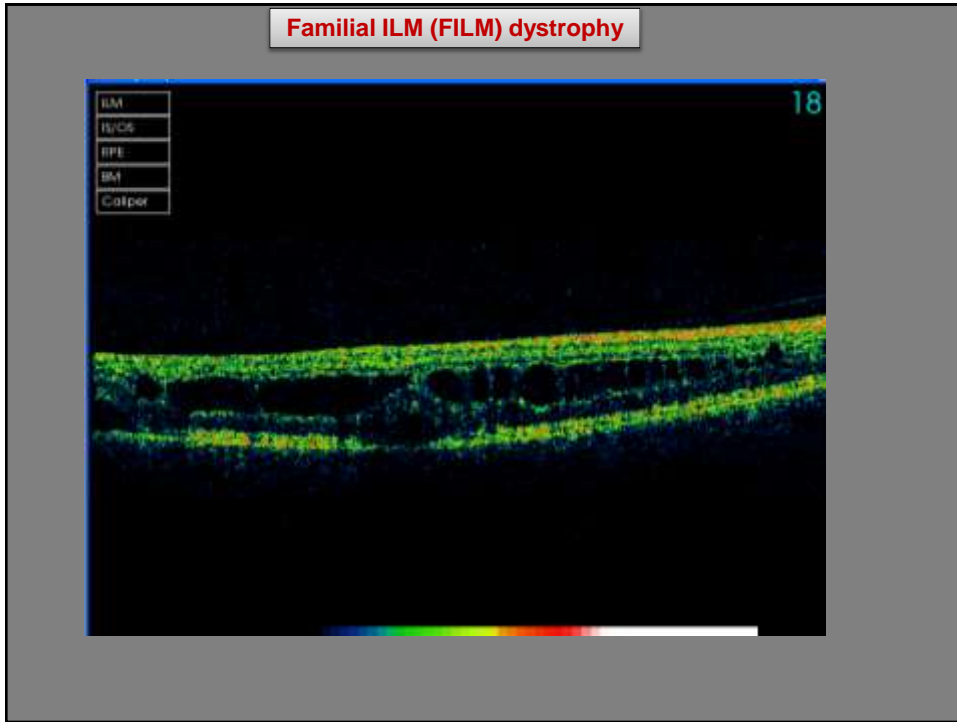
Always Respect The Patient's Complaint



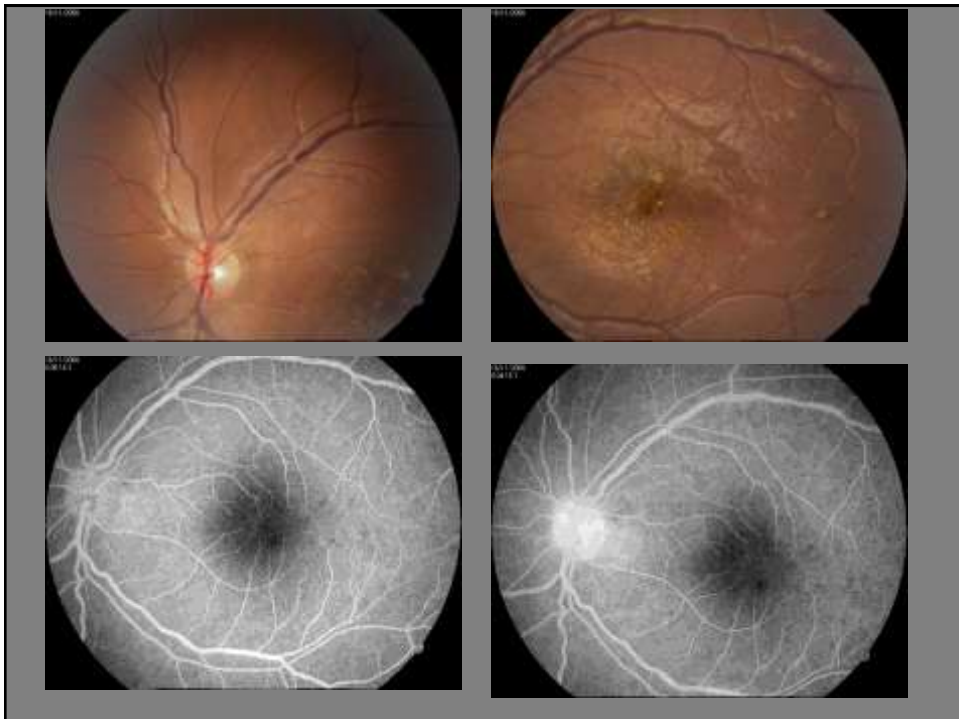
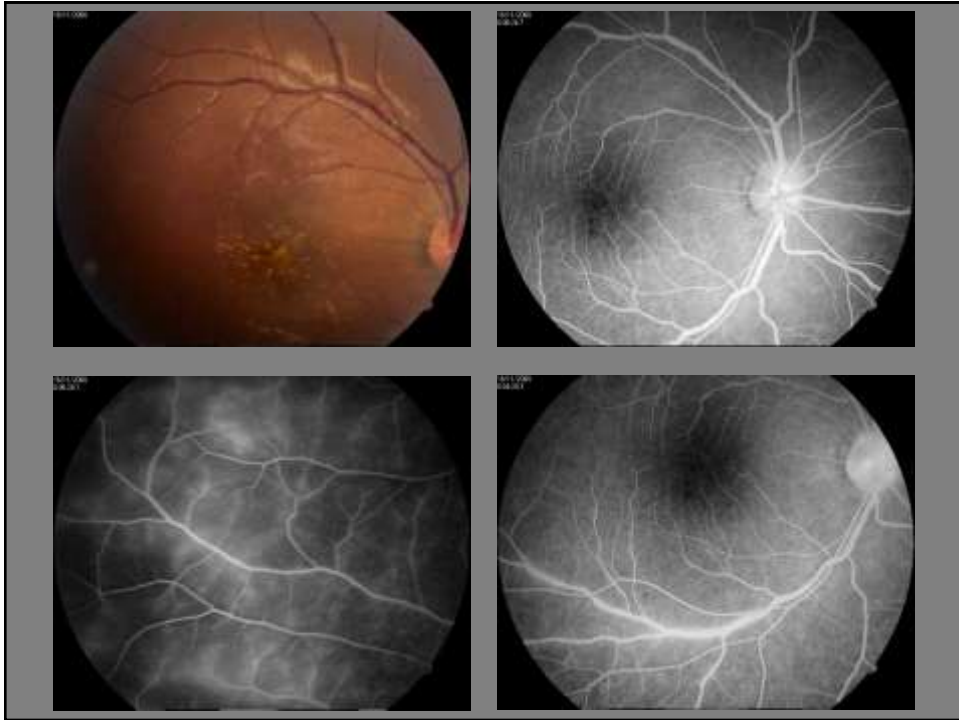


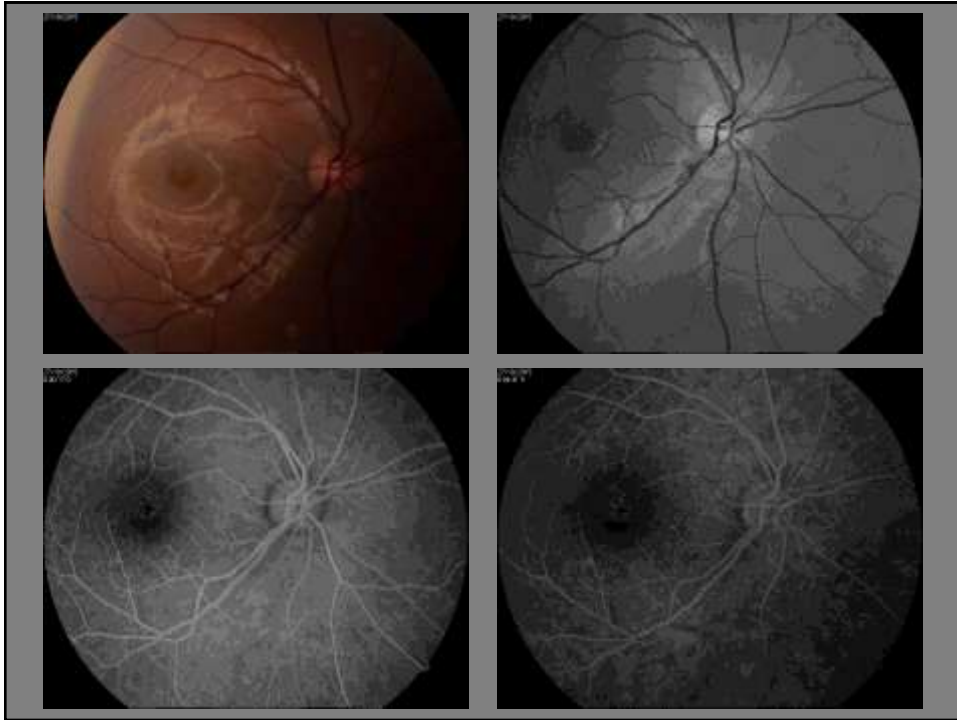




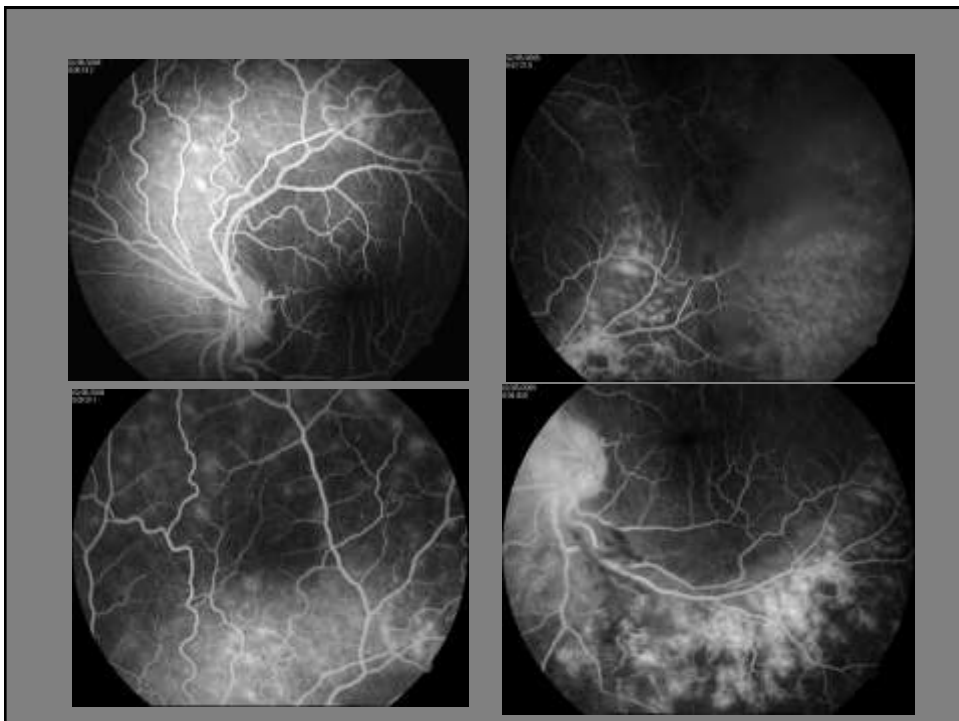
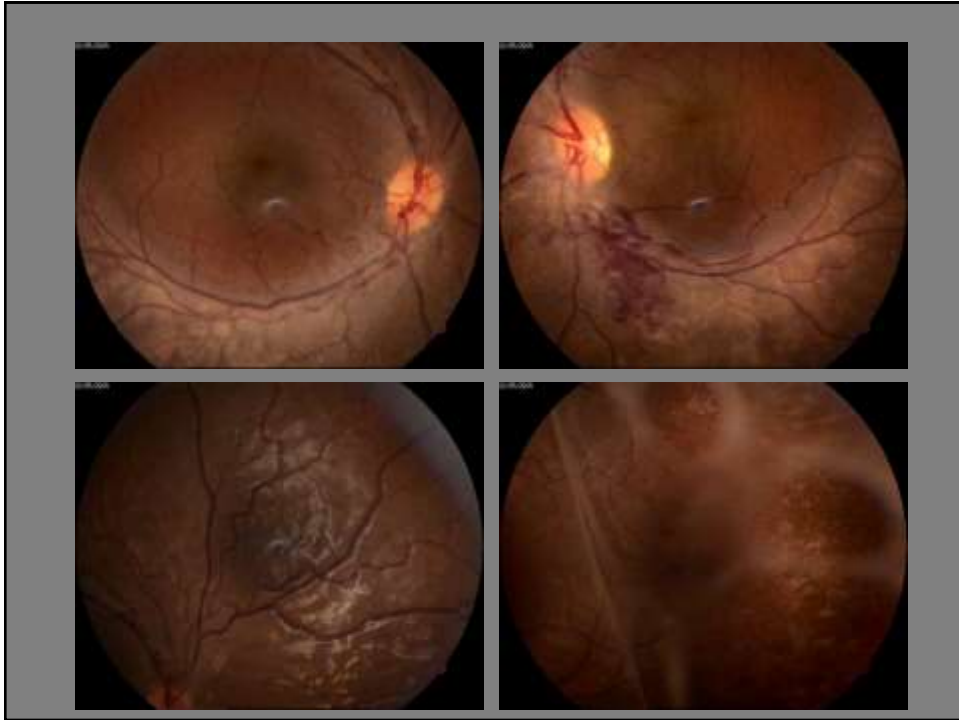


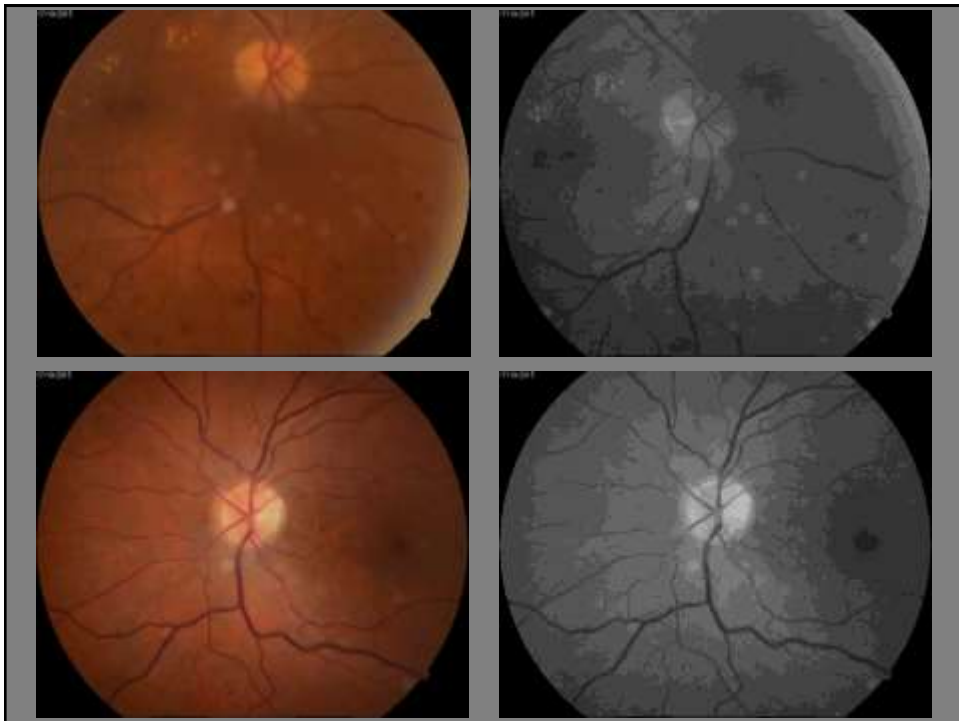
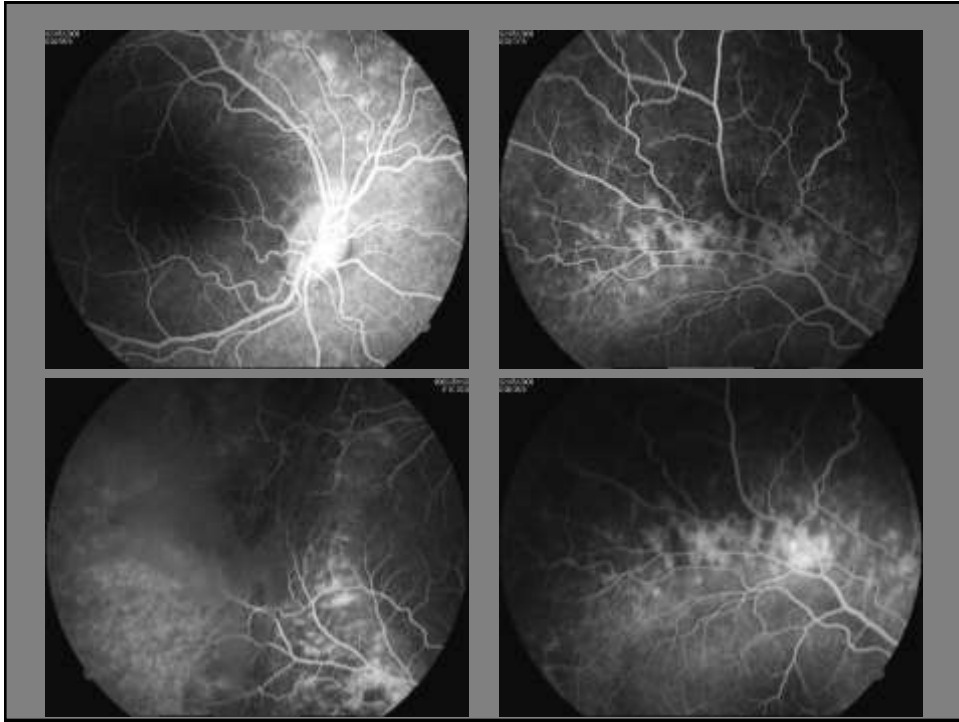
Careful History Taking

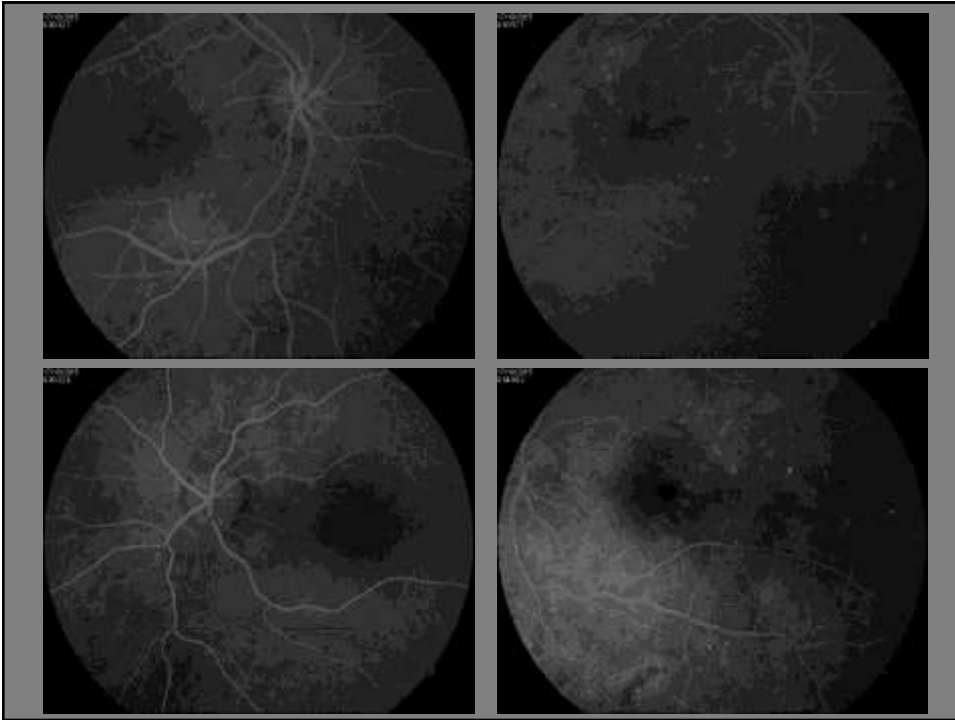




Never examine one eye only (there is no unilateral FFA)







We should understand the origin of abnormal fluorescence to reach the diagnosis

