

Diabetic vitrectomy

How to minimize iatrogenic breaks

By

Amin Nawar .Msc

Assistant lecturer of Ophthalmology
Vitreoretinal Unit -Tanta University

Difficulties in diabetic vitrectomy

- Vascular
- Friable

Risk factors for iatrogenic breaks

No previous PRP.

Highly vascular membranes.

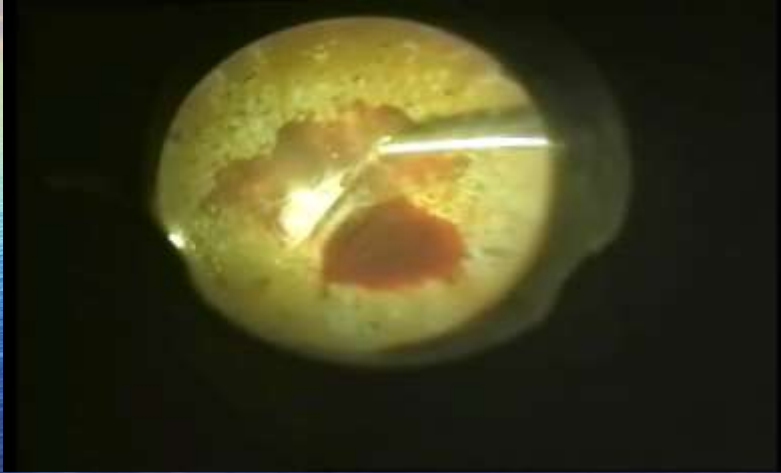Taught thickened posterior hyaloid

Time for iatrogenic breaks

PVD

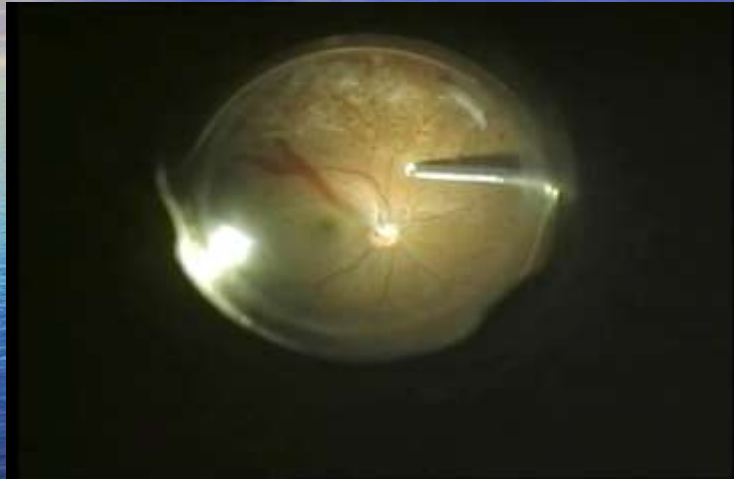
Membrane peeling

Amin nawar VR Surgeon

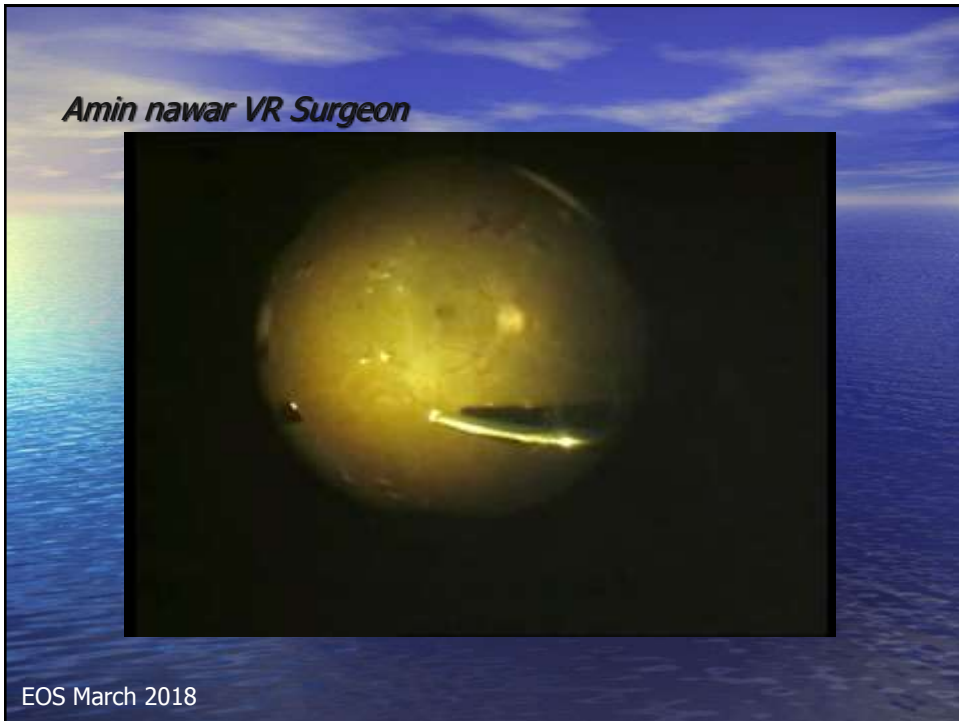

EOS March 2018

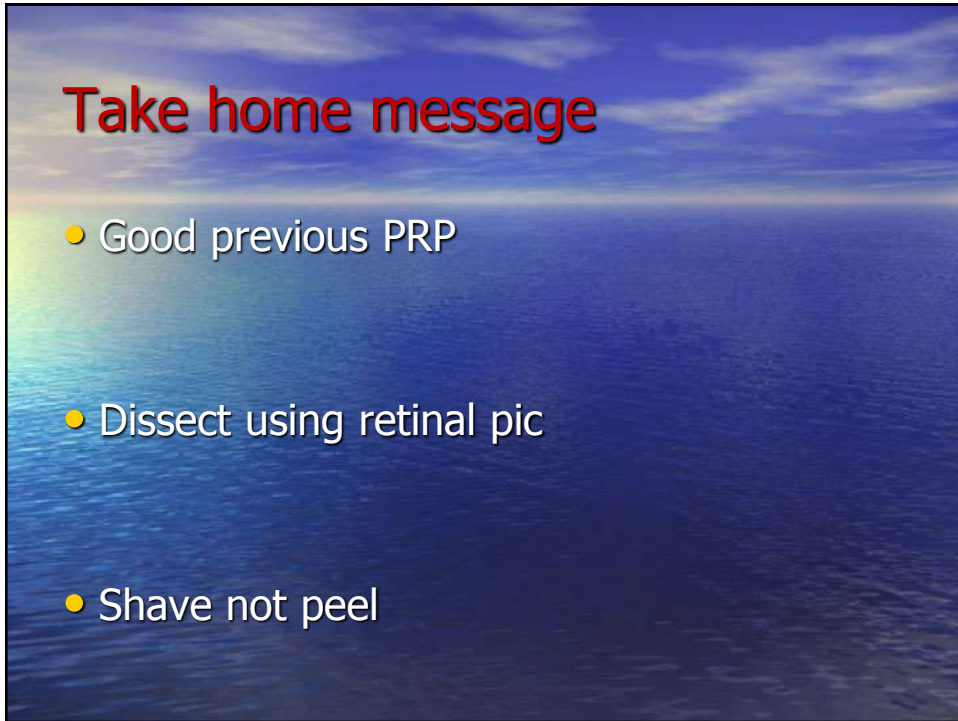
Amin nawar VR Surgeon



EOS March 2018







Take home message

- Good previous PRP
- Dissect using retinal pic
- Shave not peel

