

# LATE POSTOPERATIVE CAPSULAR BLOCK, PECULIAR FORMS

---

KHALED MANSOUR

PROFESSOR EMERITUS OF OPHTHALMOLOGY

CAIRO UNIVERSITY

## CAPSULAR BLOCK

---

Small CCC

Contents of capsule pushed forward:

Nucleus & epinucleus

IOL

## CAPSULAR BLOCK SYNDROME (CBS)

---

“Capsulorhexis-related”

Intraoperative

Early postoperative

Late postoperative

(Miyake et al, 1998)

## LATE POSTOP CAPSULAR BLOCK


---

1. Small CCC
2. Complete optic overlap
3. Distended retro-IOL space
4. Myopic shift



LATE POSTOP CAPSULAR BLOCK,  
TYPICAL FORM

---

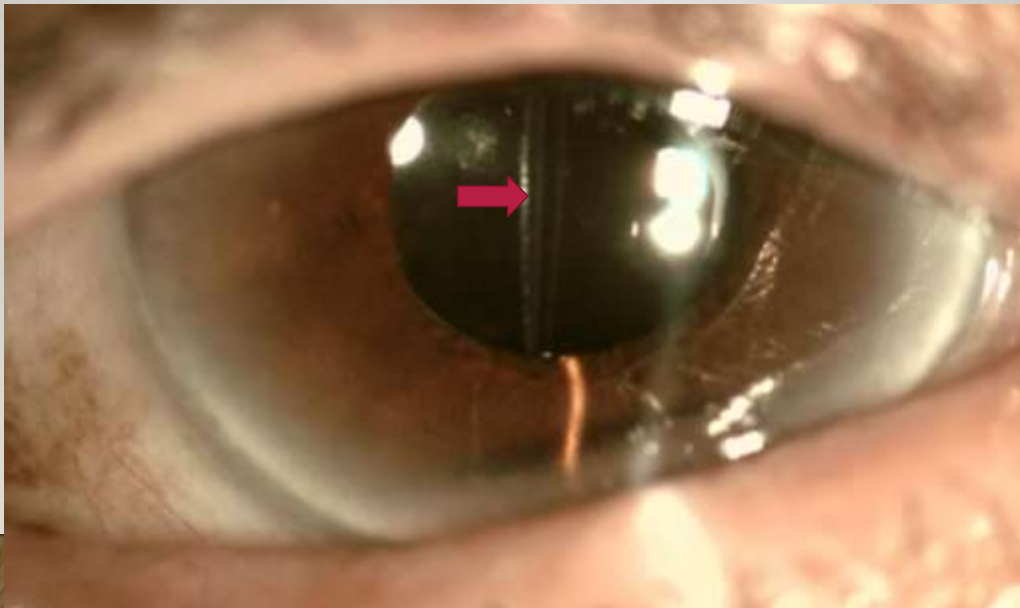


“DISTENDED RETRO-IOL SPACE”


---



DISTENDED RETRO IOL SPACE




## DISTENDED RETRO IOL SPACE



## CASE REPORT

---



Three years after uneventful phaco, acrysof 3-piece, ITB.

Marked loss of vision

Normal AS, milky fluid behind IOL, posterior capsule not seen, fundus details not seen.

Ultrasound normal



## DIAGNOSIS

---

Capsule distended with a milky fluid:

***“Capsular block with  
liquefied after-cataract”***



## “MILKY FLUID” BEHIND THE OPTIC

---

“Liquefied after-cataract”

(“*Lacteocrumenasia*”)

Accumulation of collagen & extracellular matrix produced by metaplastic residual LECs  
(Eifrig, 1997; Miyake et al, 1998).

## LATE CBS WITH LIQUEFIED AFTER-CATARACT

---

Differential diagnosis: infection

Propionibacterium acnes

Fusarium

Rare

## MANAGEMENT

---

Nd:YAG anterior capsulotomy

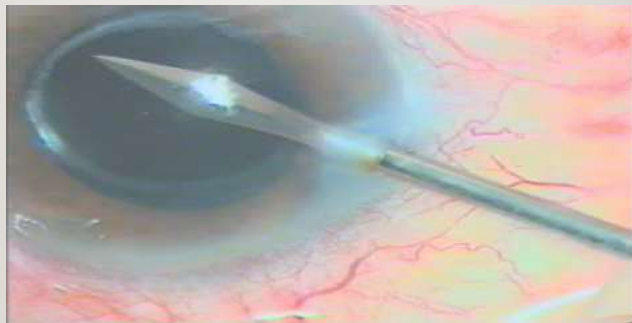
Aspiration

Nd:YAG posterior capsulotomy

## CAPSULAR IRRIGATION

---

Dissection between ant caps & optic

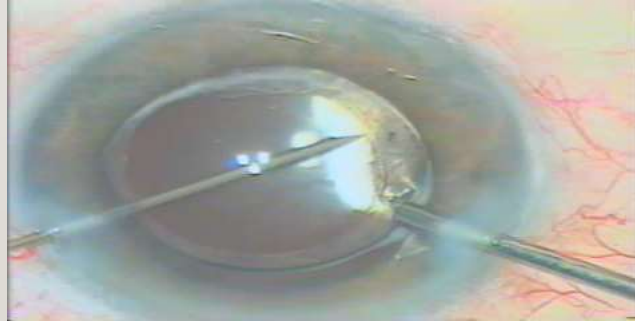



## CAPSULAR IRRIGATION

---

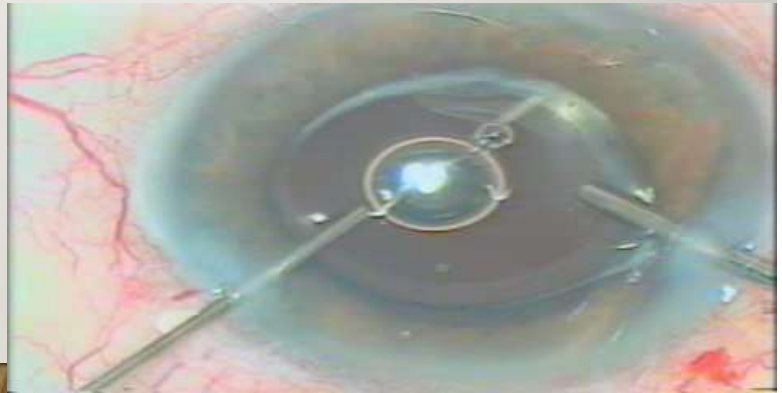Dissection between ant caps & optic



## CAPSULAR IRRIGATION

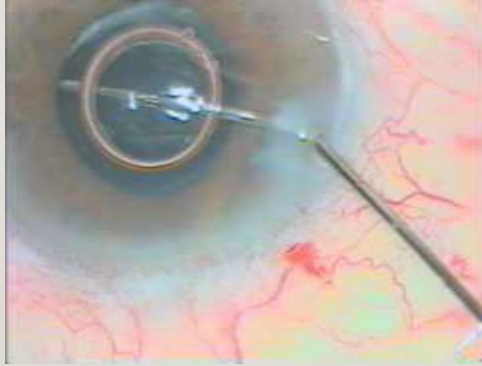
---

Dissection between  
ant caps & optic



## CAPSULAR IRRIGATION

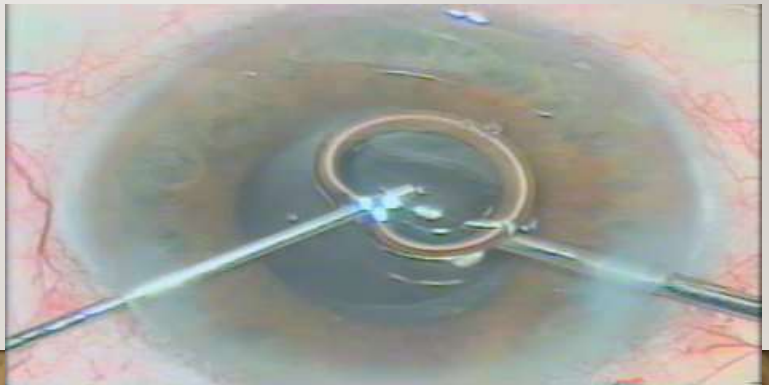---



## CAPSULAR IRRIGATION

---

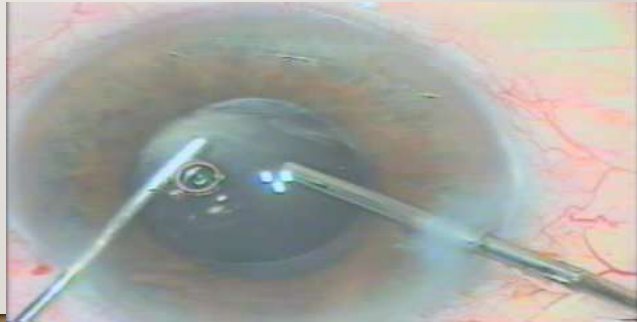Aspiration of milky fluid



## CAPSULAR IRRIGATION

---

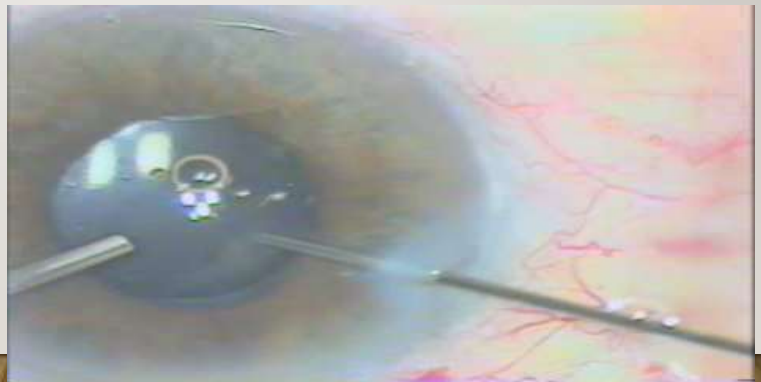Aspiration of milky fluid



## CAPSULAR IRRIGATION


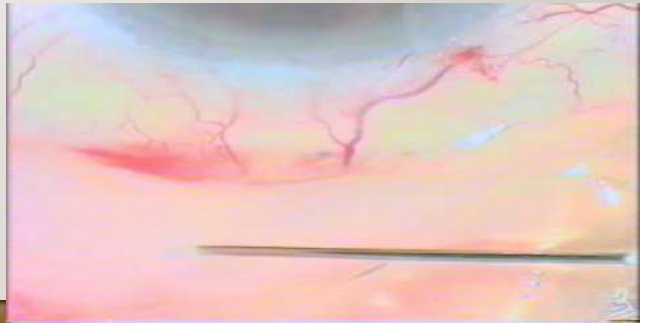
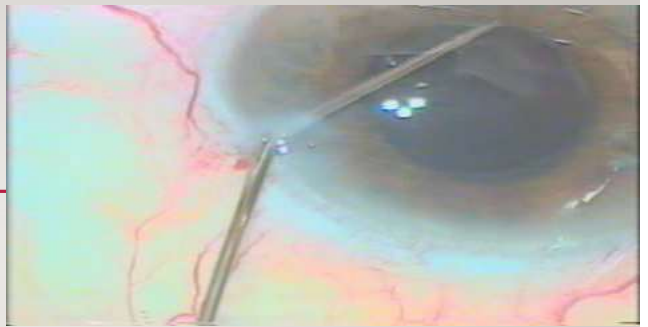
---

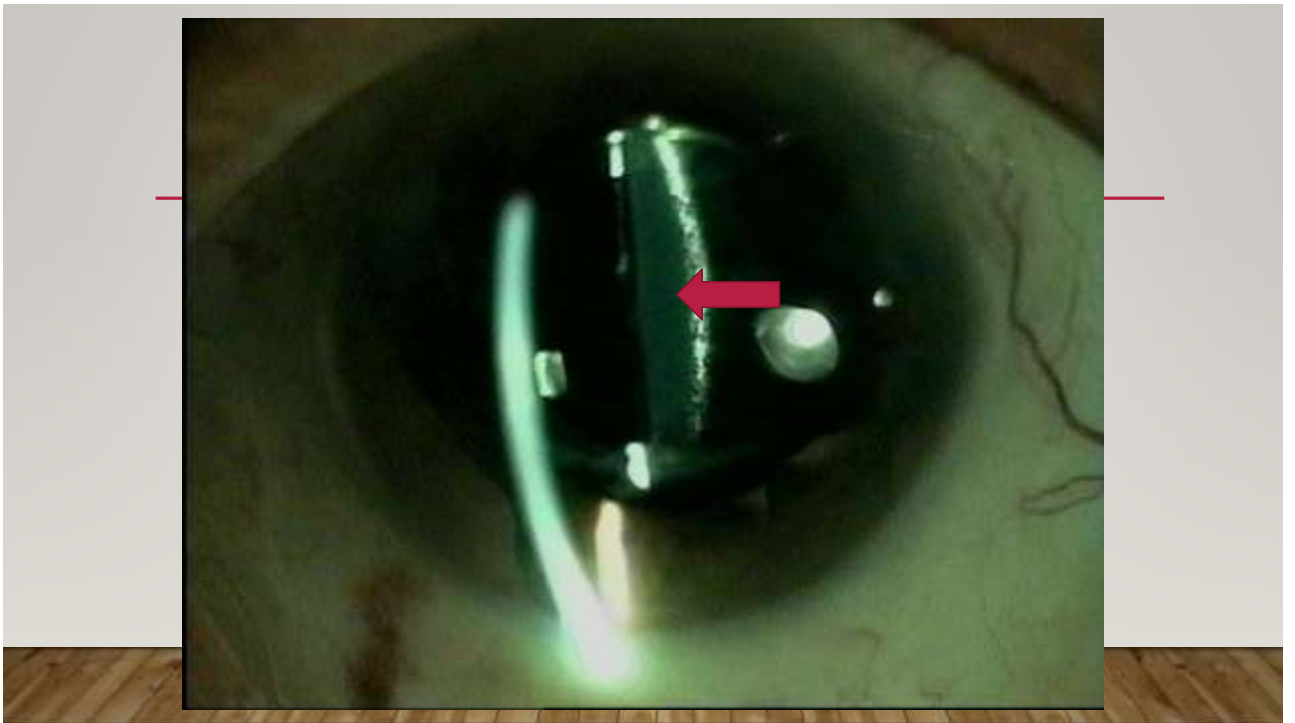
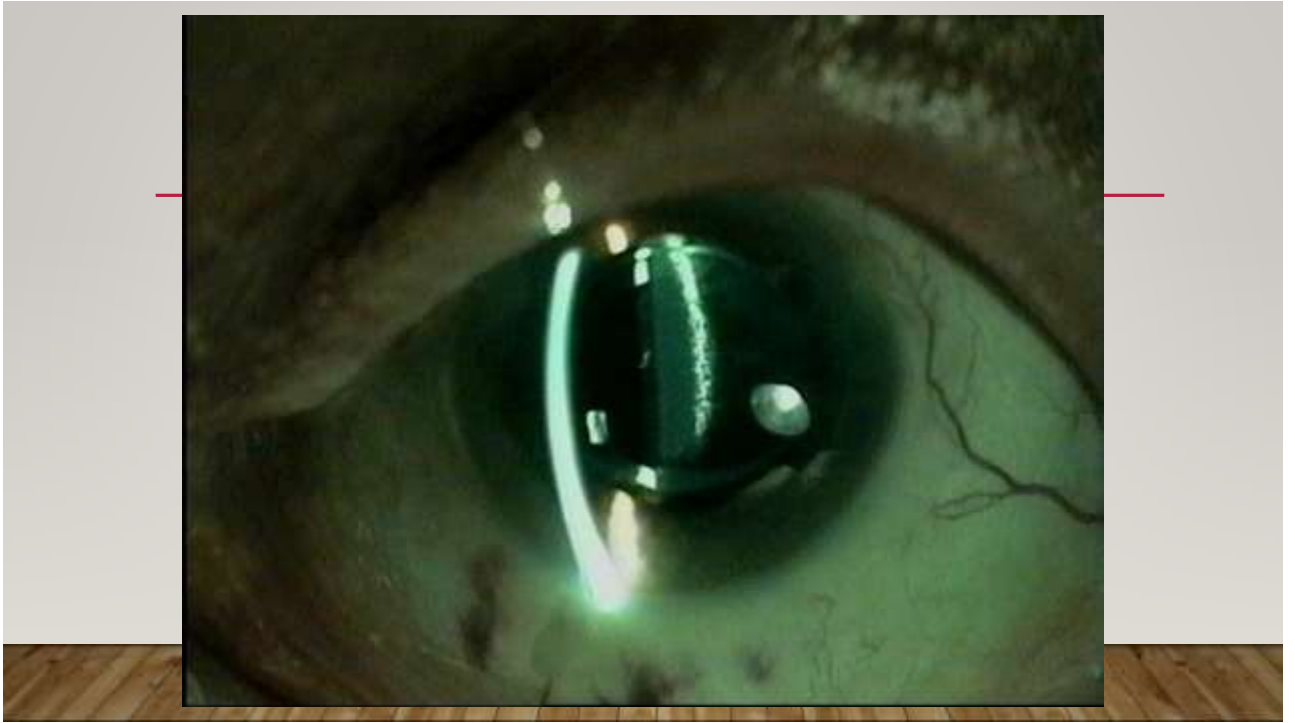
Aspiration of milky fluid



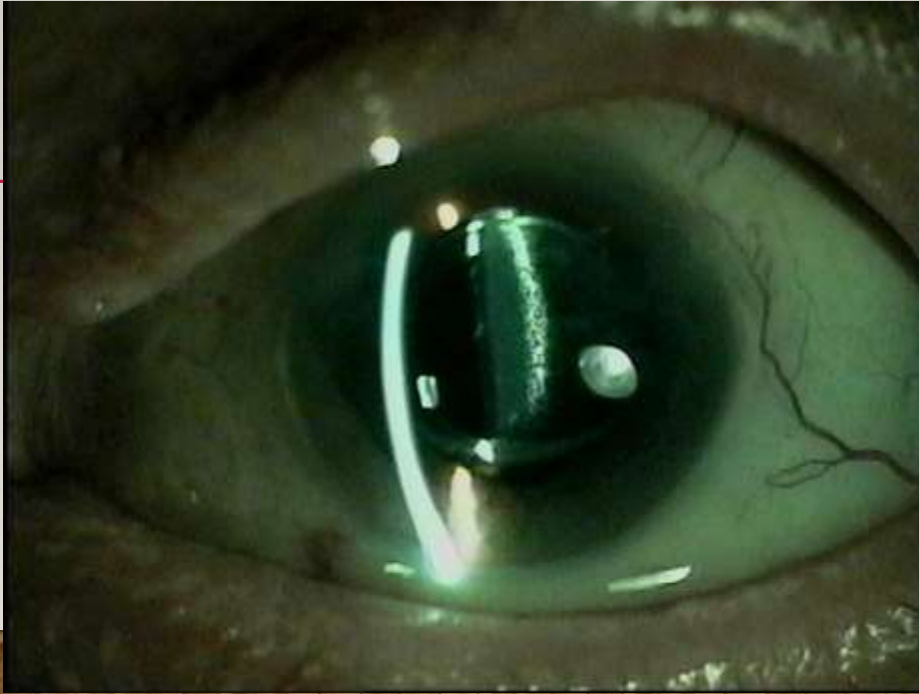
## VANCOMYCIN

- 1 mg in 0.1 ml









## LATE POSTOP CAPSULAR BLOCK

---

Small CCC

Complete optic overlap

Distended retro-IOL space (+/- milky fluid)

Myopic shift



## LATE CBS WITH LIQUEFIED AFTER-CATARACT

---

**Not infection**

## CAPSULAR BLOCK SYNDROME (CBS)

---

Capsulorhexis-related

Intraoperative

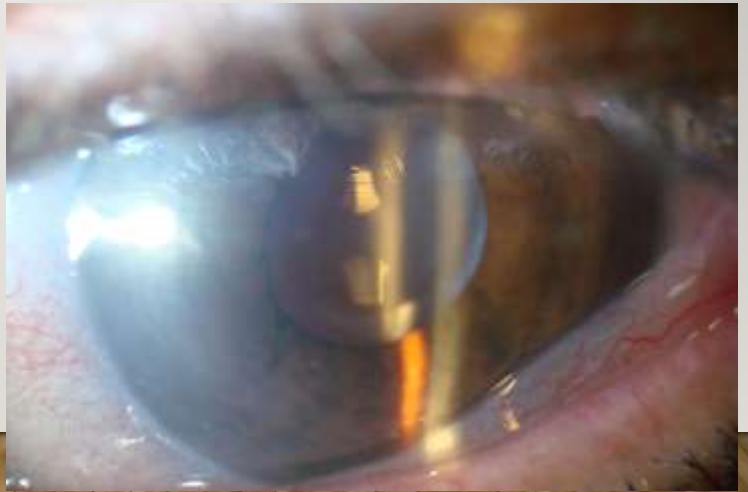
Early postoperative

Late postoperative  
(Miyake et al, 1998)

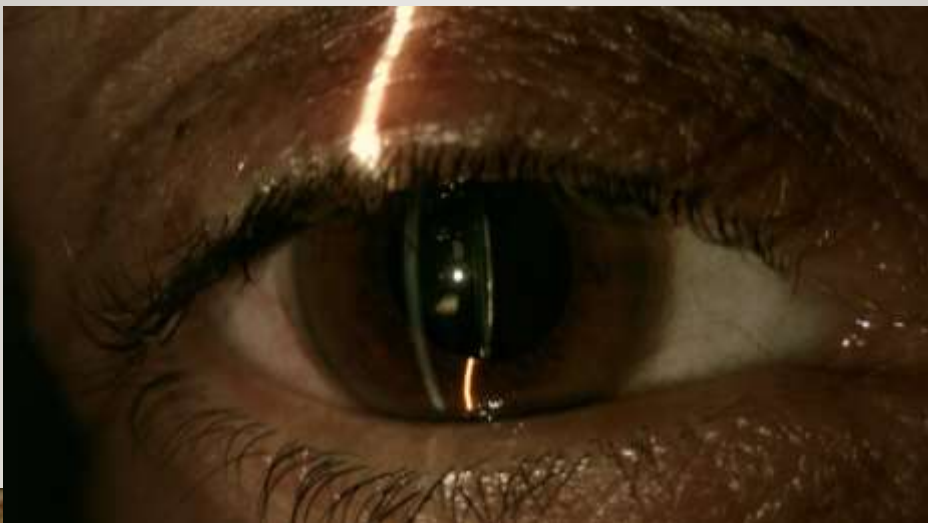“The eye sees what the brain knows”

---

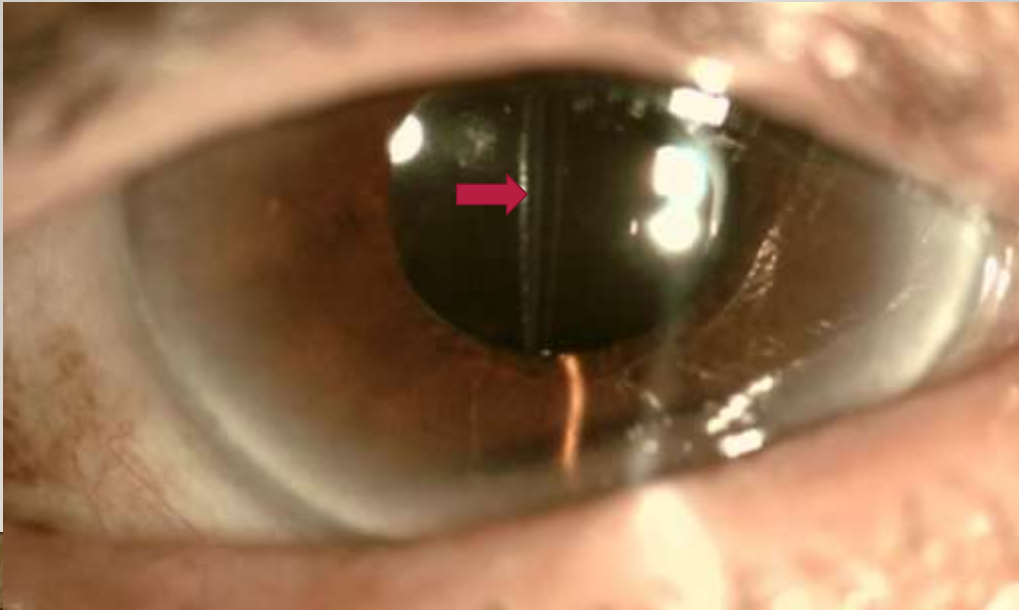
“Late postop CBS”




DISTENDED RETRO-IOL SPACE



DISTENDED RETRO IOL SPACE



DISTENDED RETRO IOL SPACE



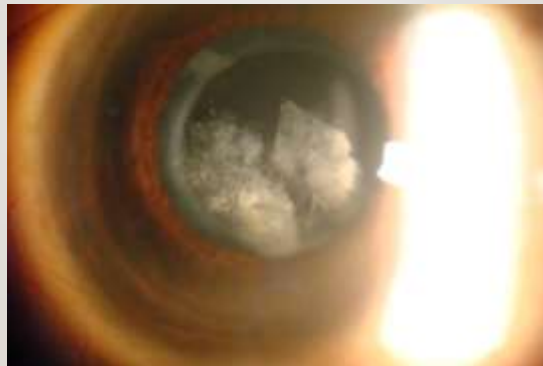
## Late Postop Capsular Block

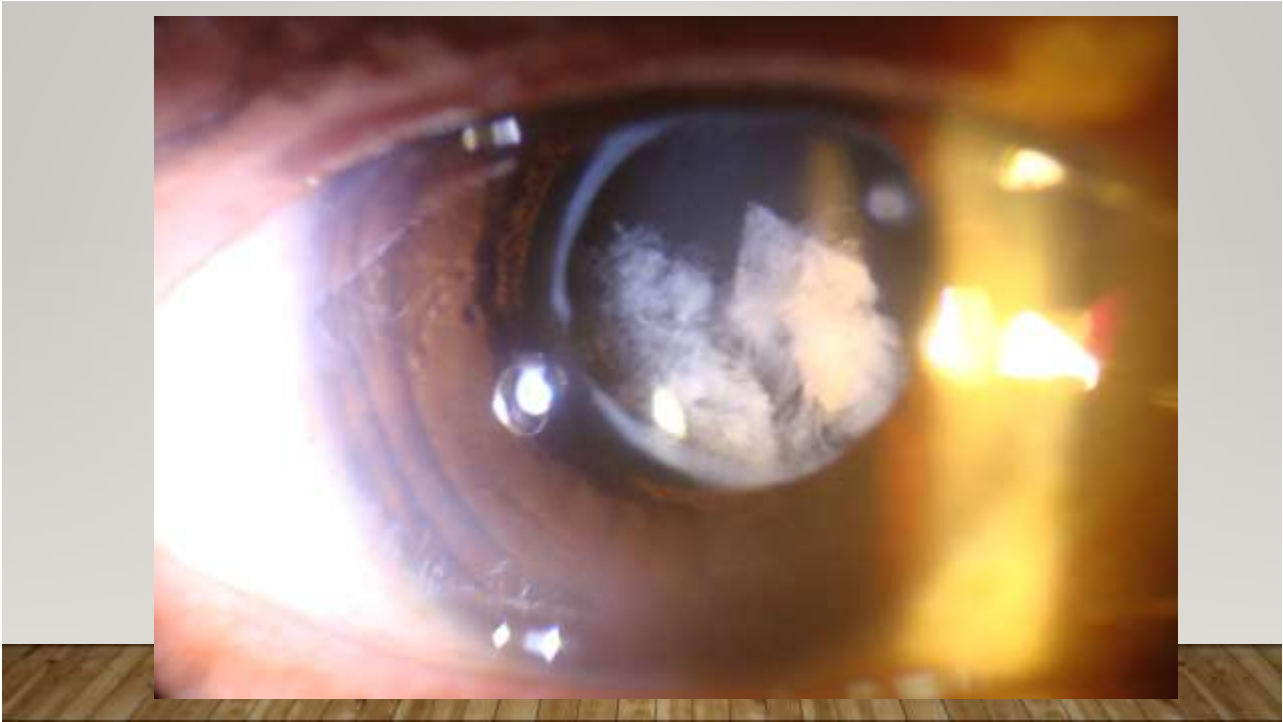
---




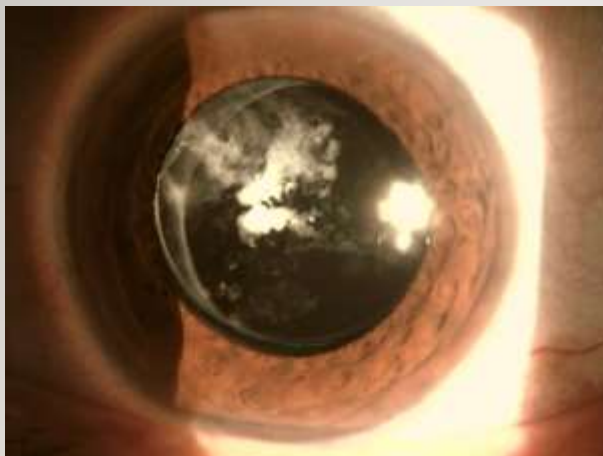
## LATE CAPS BLOCK, "PECULIAR FORMS"

---





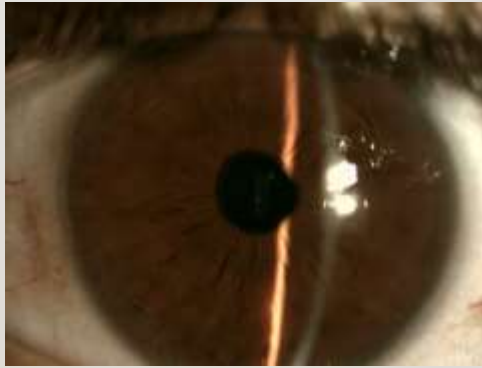
TOO HARD FOR YAG?





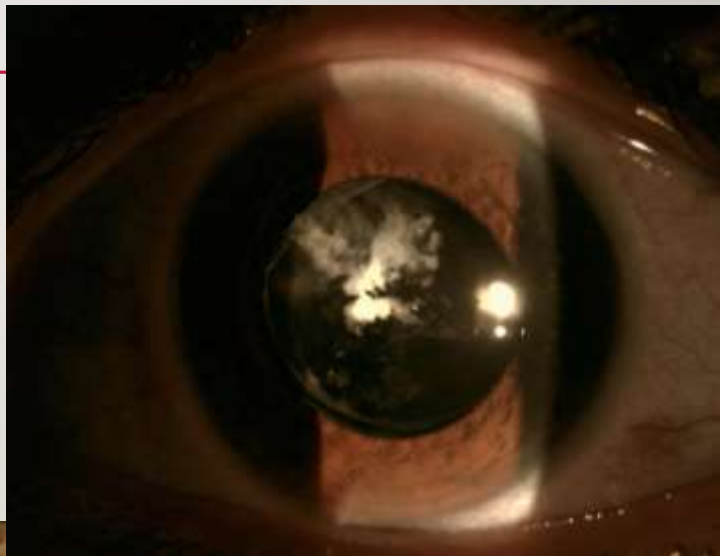
NO, IT'S ONLY FLUID

---



“LOCULATED FLUID”

---





# MERCI!

