

The failed bubble

Ahmed Sherif, MD

Associate Professor

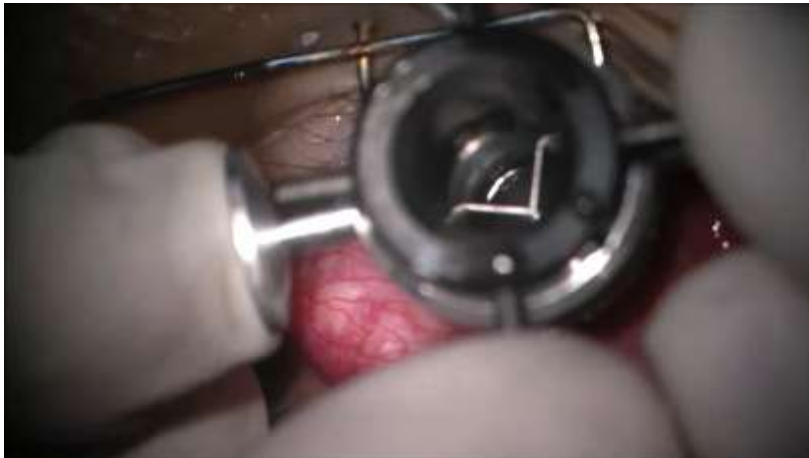Cairo University



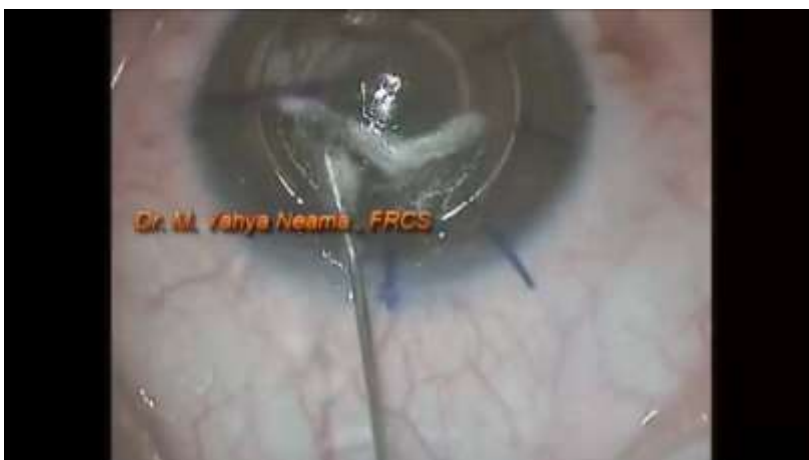Causes

- Too shallow needle placement
- Too deep needle placement
- Incomplete bubble
- Burst bubble
- Posterior corneal scars

Too shallow needle placement

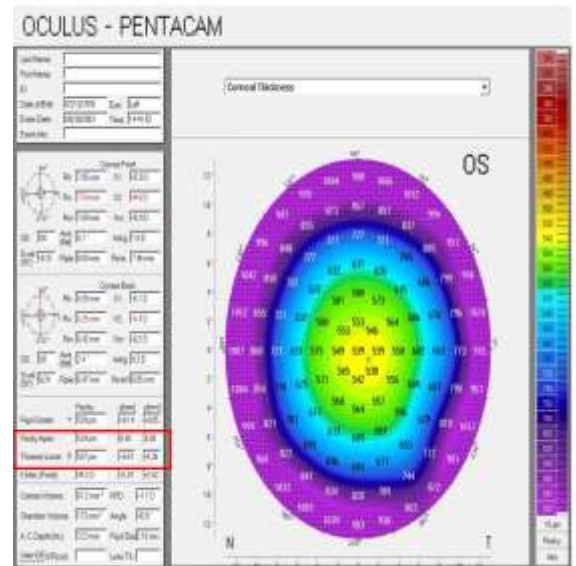


Too deep needle placement

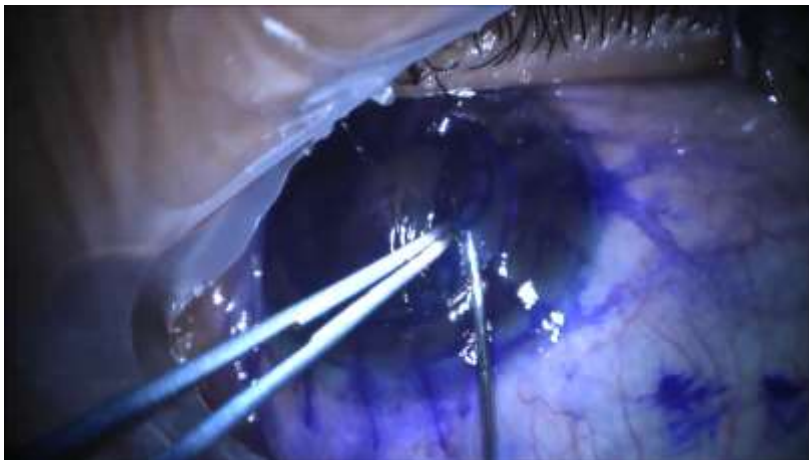

How to avoid?

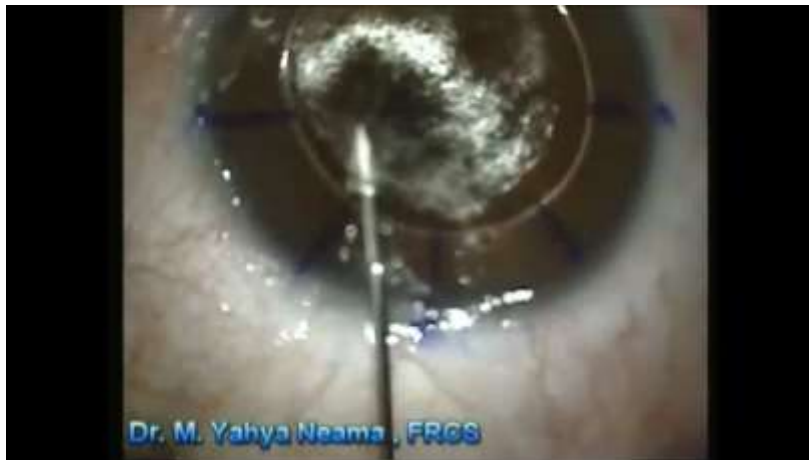- Use suction trephines
- Avoid used trephines
- Know your thickness:
 - use pachymetry map of Pentacam
 - use contact pachymetry
- Trephine 70 %
- Use cannula for injectin



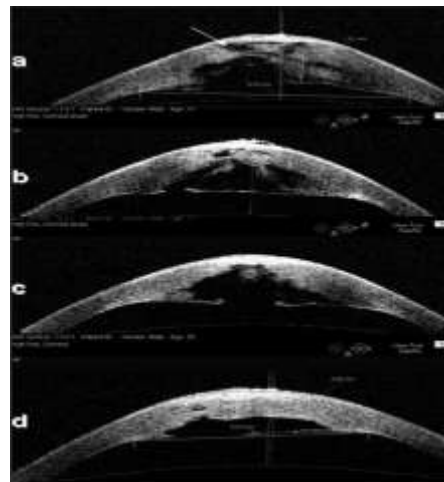
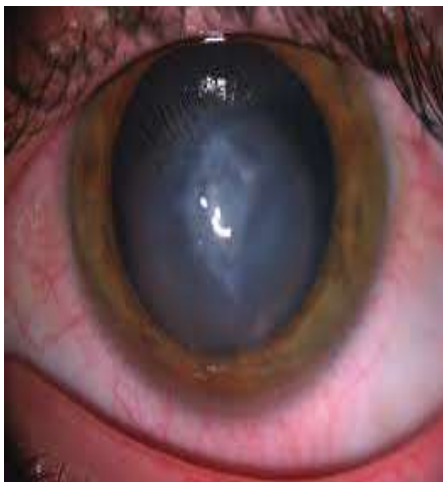Incomplete bubble



Burst bubble



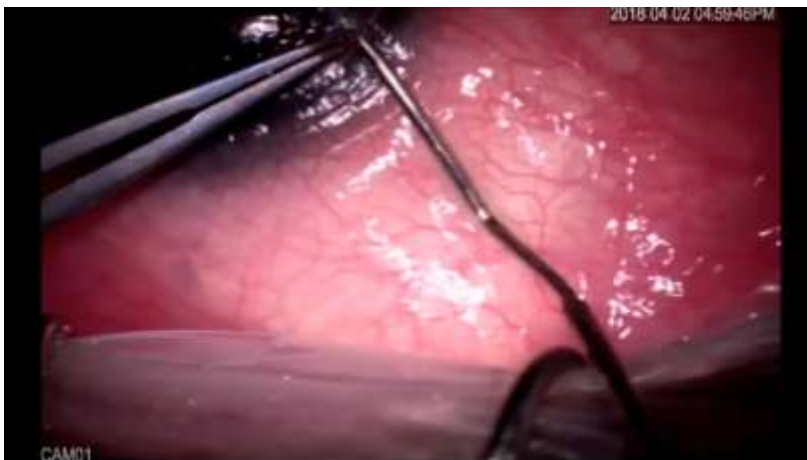Posterior corneal scars



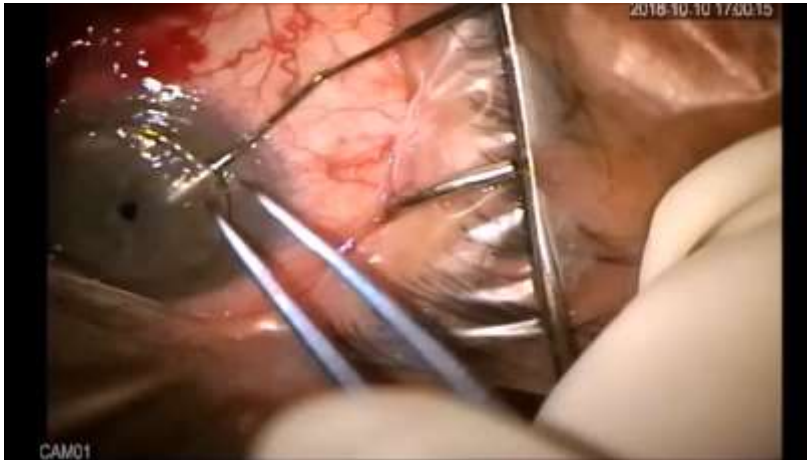
How to proceed ?



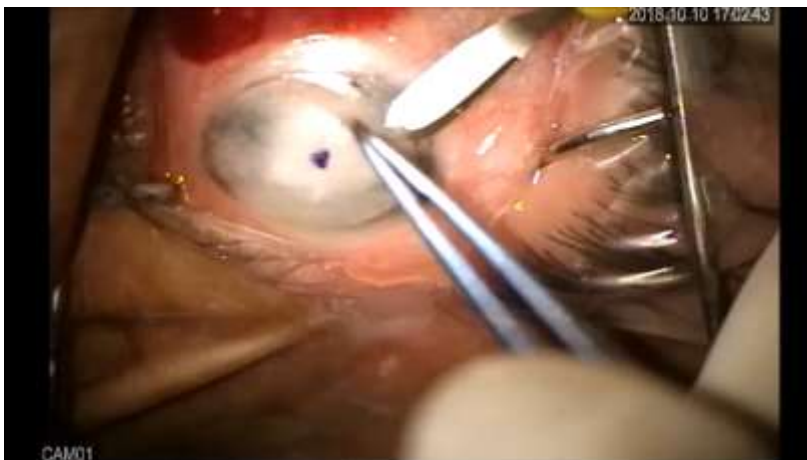Repeat injection



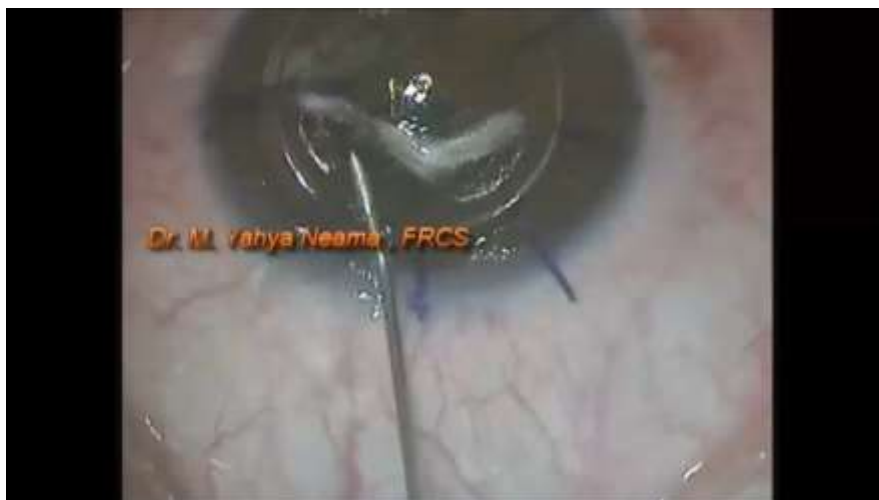Pneumo-dissection



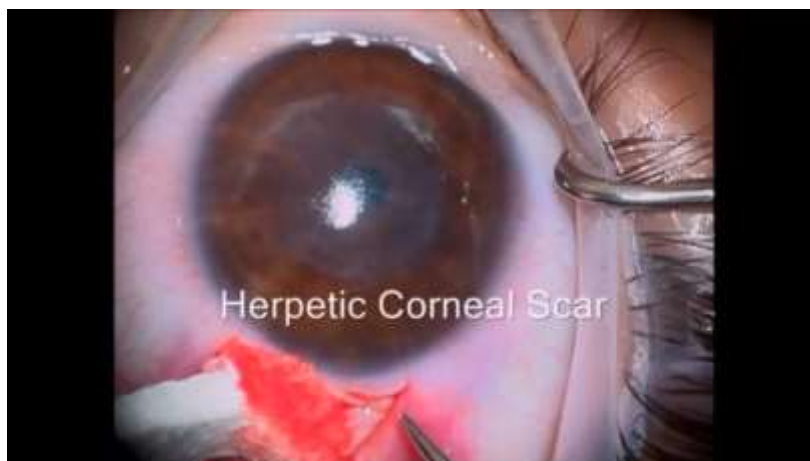
Pneumo-dissection



Hydro-delamination

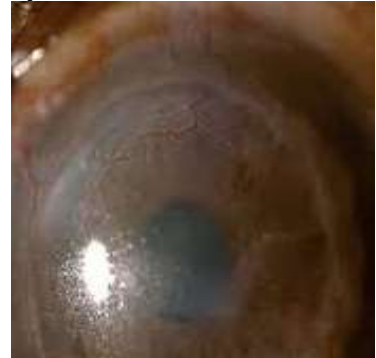
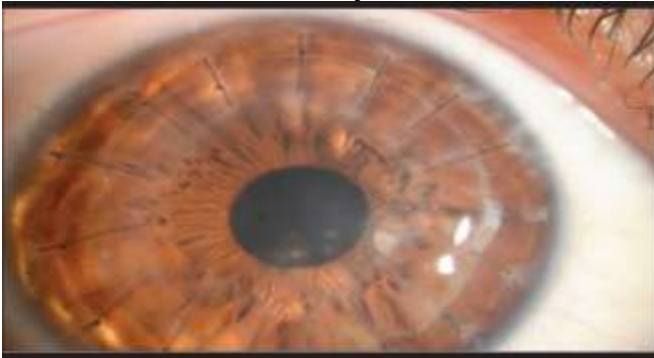
Visco-dissection



Outcomes

- Visual acuity slightly lower (1-2 lines) in pre-descemetic DALK due to scatter and mild interface haze
- No difference in astigmatic results
- Invasion of Interface by neovessels is a rare complication



Thank You

