

# DALK Extreme

Ahmed Sherif , MD

Associate Professor of Ophthalmology  
Cairo University



## DALK in advanced keratoconus

### Rationale:

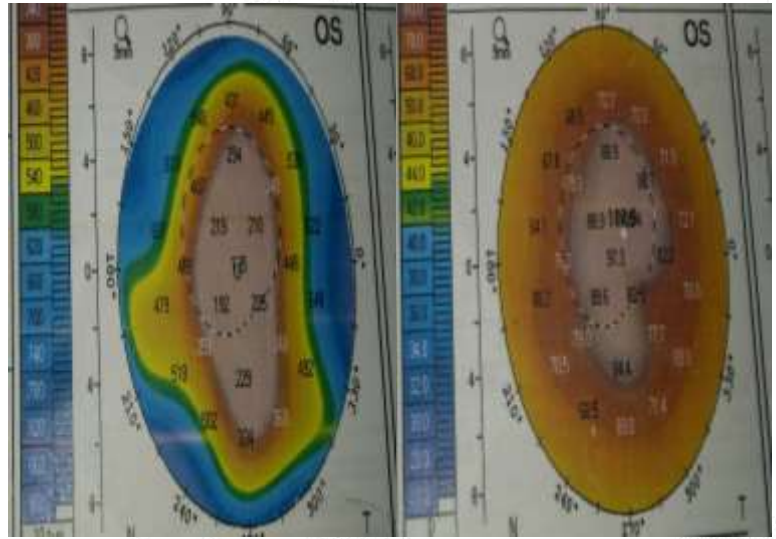
- Avoid graft rejection
- Avoid complications of open globe surgery

### Challenge:

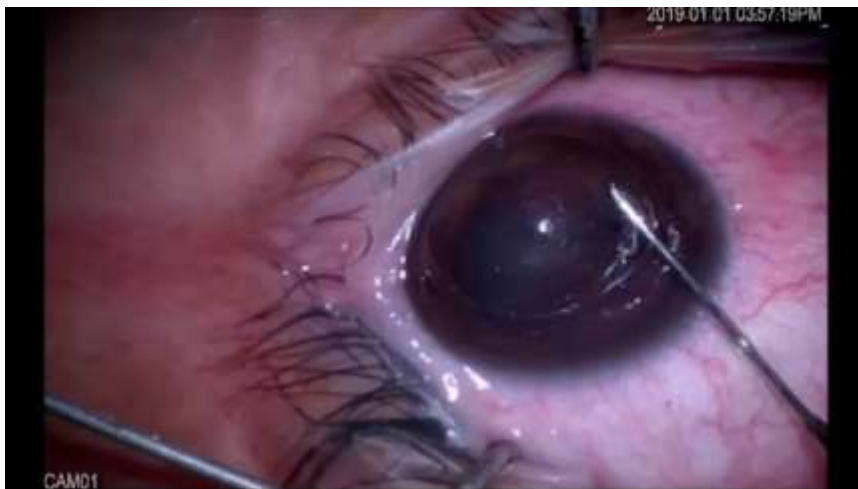- More prone to microperforation
- More prone to Descemet`s folds

## DALK in advanced keratoconus

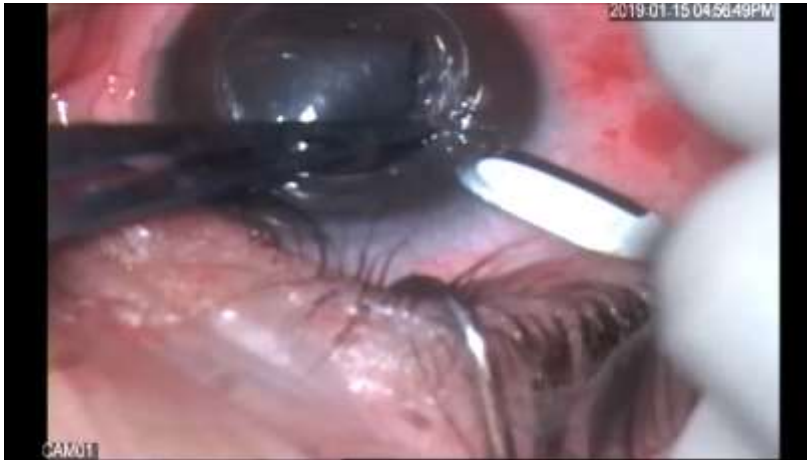- 24 years old female patient
- BCVA 1/60
- K1 : 82.2 D
- K2: 92.4 D
- Thinnest point: 135 micron



## DALK in advanced Keratoconus



## DALK after perforation during trephination



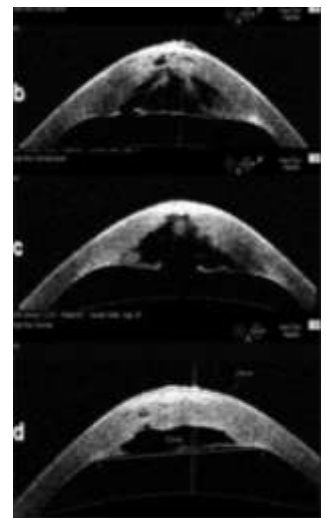
## DALK in acute hydrops

### Rationale:

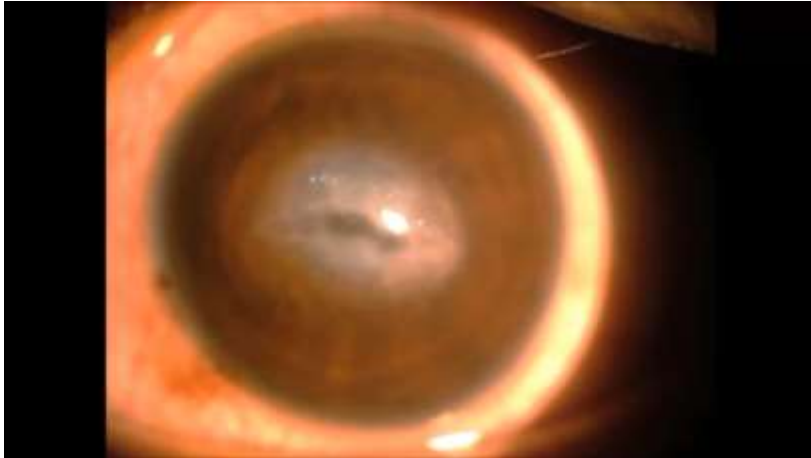
- Rapid visual recovery
- Reduce residual stromal scar

### Challenge:

- DM tear → BB will not form  
→ more prone to post-operative double AC



## DALK in acute hydrops



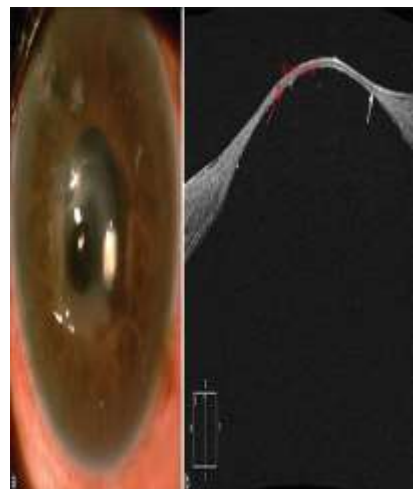
## DALK in Descematocele

### Rationale:

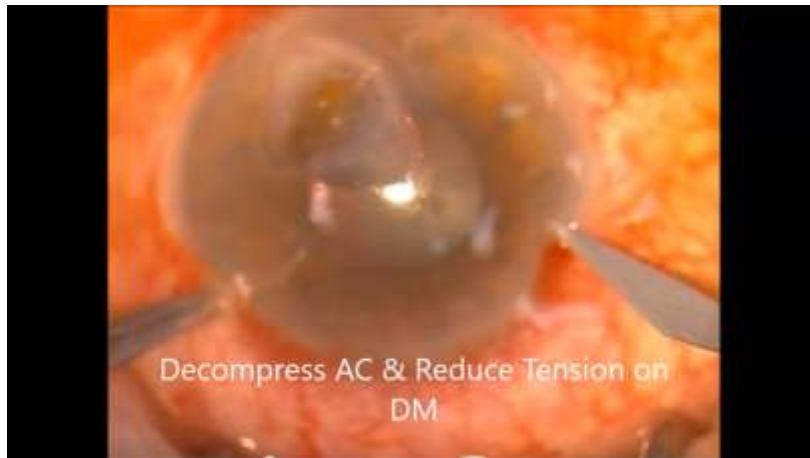
- Avoid globe perforation
- Avoid high risk PKP

### Challenge:

- More risk for macroperforation → PKP



## DALK in Descematocele



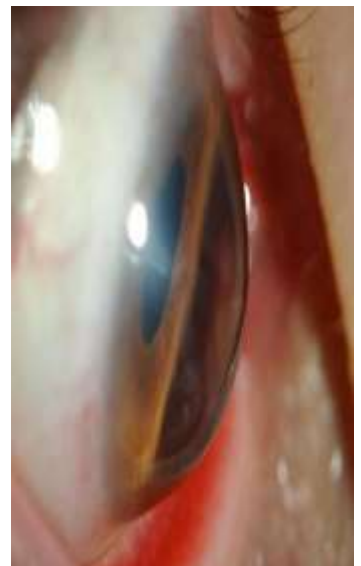## DALK in Keratoglobus

### Rationale:

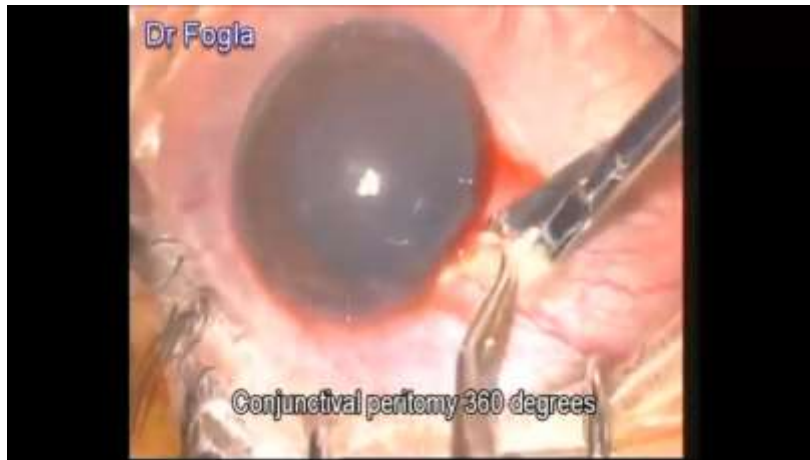- Poor PKP results due to:
  - graft-host thickness disparity → high astigmatism
  - Large diameter graft → rejection

### Challenge:


- Extreme peripheral thinning



## DALK in Keratoglobus



## DALK in keratoglobus





**MISSION:**  
**POSSIBLE**

A graphic featuring the text "MISSION:" in a bold, black, sans-serif font. A black starburst icon is positioned to the left of the word "MISSION:", with a horizontal line extending from its center to the start of the word. Below "MISSION:" is the word "POSSIBLE" in a large, bold, red, sans-serif font, slanted upwards from left to right. The entire graphic is set against a white and light gray checkerboard background.