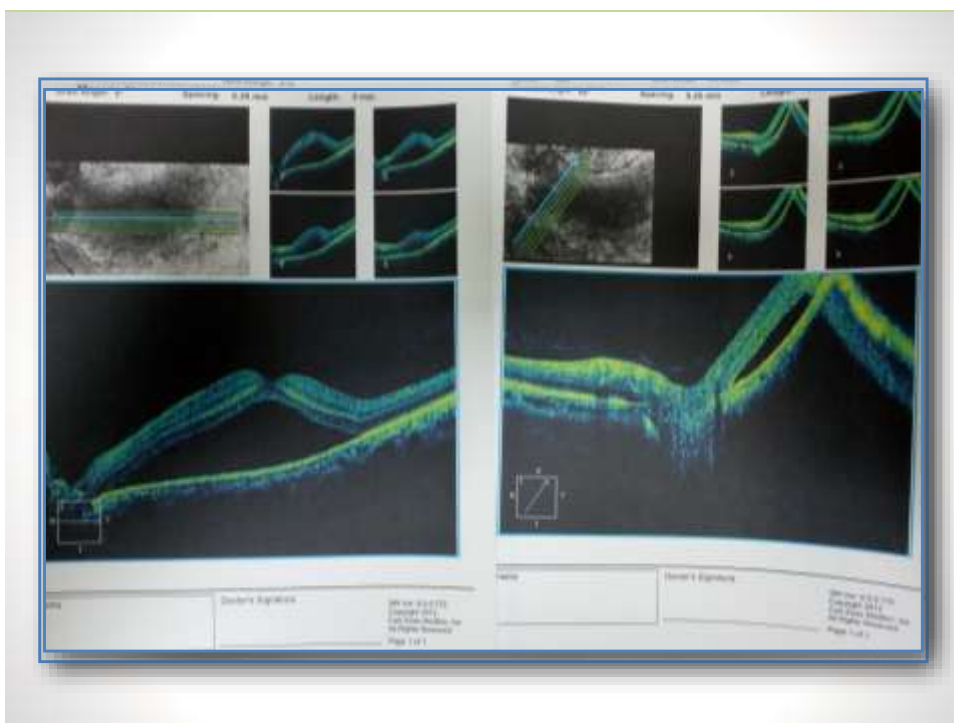
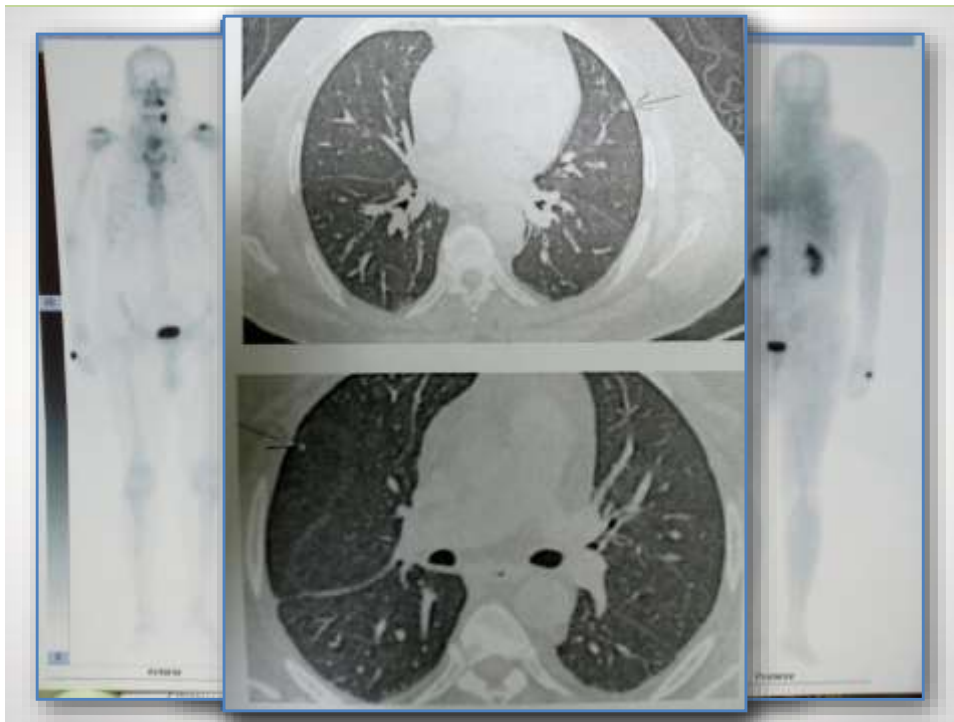



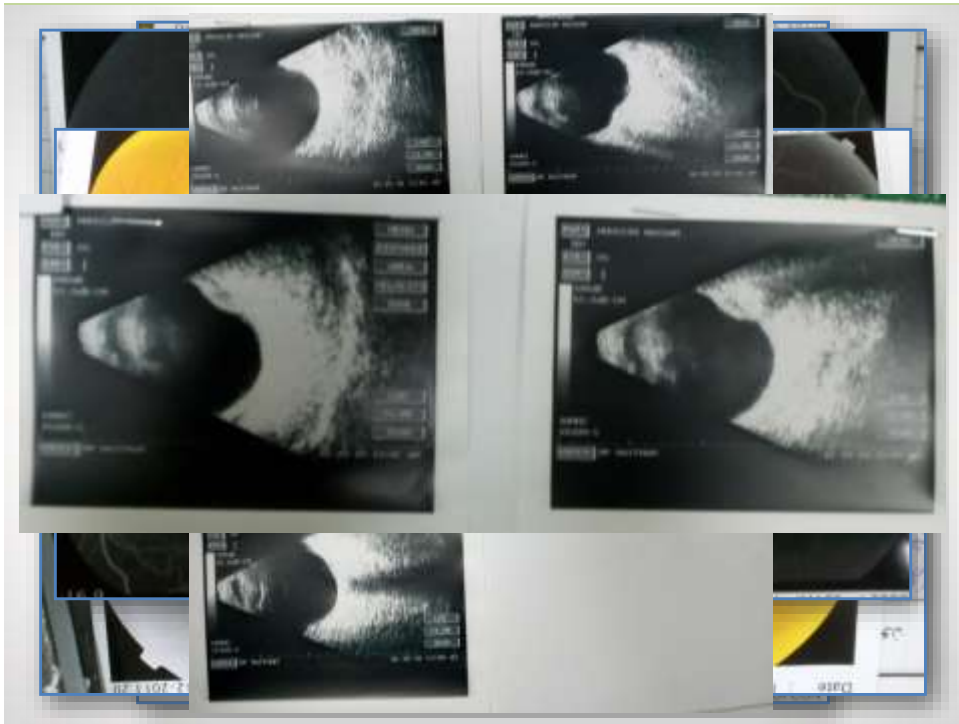
# سبحان الله

- The patient presented ? and was referred ?
- The complaint started with ?
- The complaint ? progressed over ? weeks
- Vision in ipsilateral eye ? contralateral eye ?

- **Suggests treatment steps**
- **Pain**
- **Injection (chemotherapy / Anti VEGf)**
- **Excisional biopsy technique**
- **Reconstruction**
- **Cosmesis**

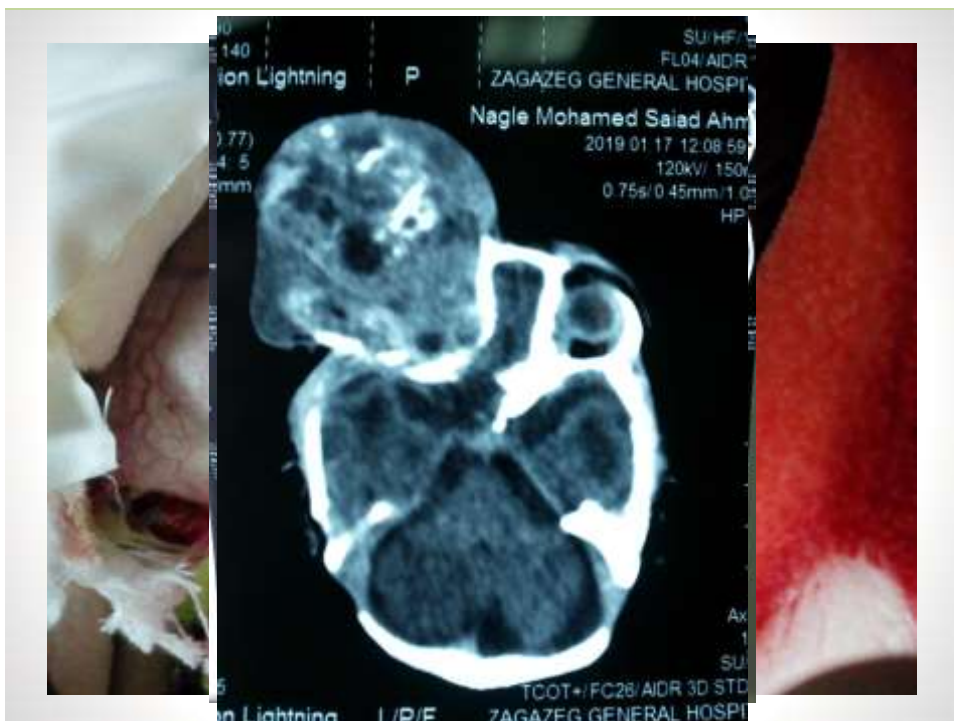- Radiotherapy external type
  - Brachy therapy
  - Brachytherapy with laser treatment
  - Brachytherapy with anti VEGF



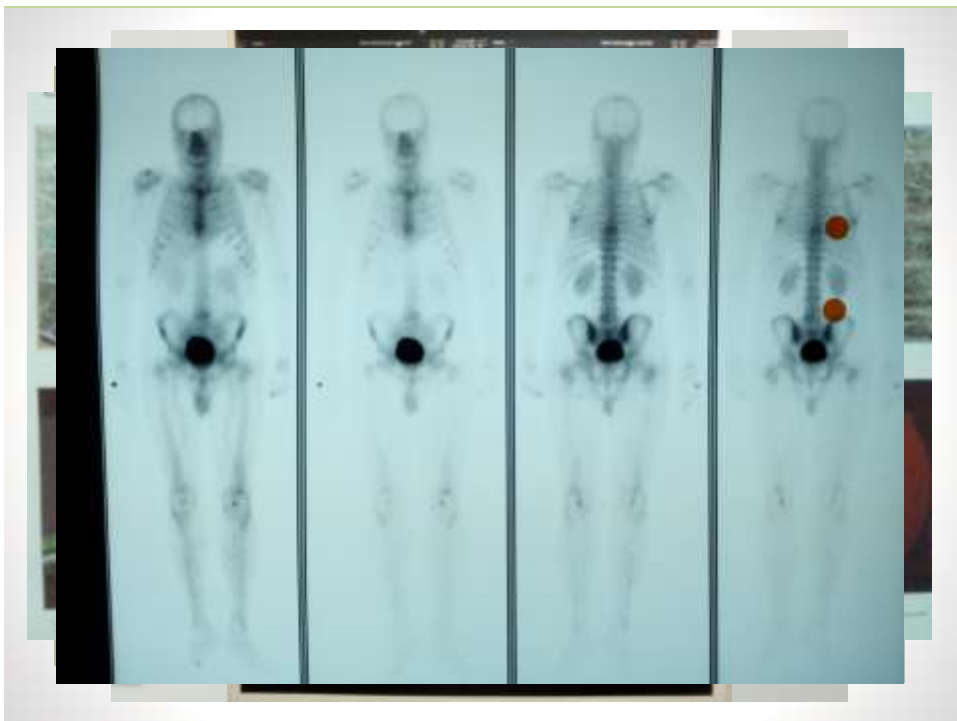


# Female new borne Right side swelling

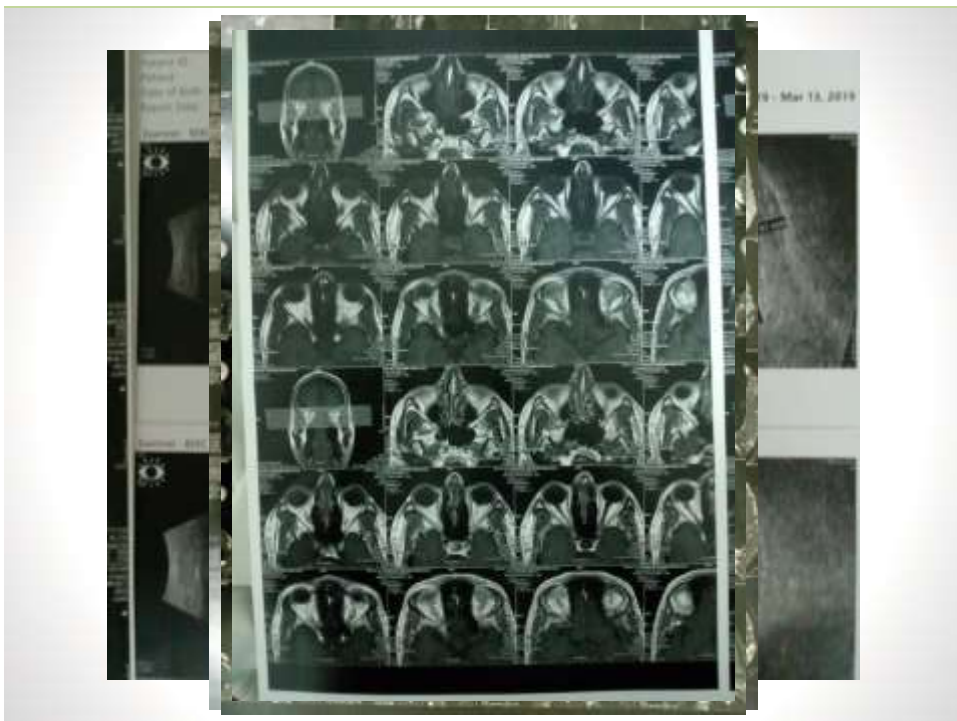Parents presented with their new born



- Patient : Mn Male 70 years



- 49 year old female
- Altered vision in her left eye since weeks



- 74 year old male
- Drop of vision
- In Right eye since a few weeks

