



Post-LASIK infections

By

Hassan Shamseldeen

Assistant Prof. of ophthalmology

AL-Azhar university – Assuit



- **LASIK** has become a common refractive procedure and is generally considered safe.

The incidence of sight threatening complications after LASIK remains low.

However post-LASIK infections can be a disastrous complication for the patient who is often just undergoing cosmetic procedure and usually has high expectations.





Risk factors :-

Infections occurring after PRK may be secondary to epithelial defect as well as the use of therapeutic contact lenses.

Unlike PRK, the integrity of Bowman's membrane and the corneal epithelium is maintained intact after LASIK; hence, the risk of microbial keratitis after LASIK is considered lower than other procedures.

Despite this, the occurrence of keratitis after LASIK is a reality.




* During surgery

The corneal stroma may come into contact with infectious agents coming from the patient's own body or from contaminants present on the instruments.

The surgeon and the operating room may also act as a source.

Breaks in the epithelial barrier and excessive surgical manipulation are other risk factors.





* Postoperatively

delayed corneal re-epithelization, the use of topical steroids and therapeutic contact lenses as well as decreased corneal sensitivity and dry eye can all contribute to post-LASIK infections.




• Clinical picture:-

Onset:-

Infectious keratitis generally present later than DLK, with which it is often confused.

It traditionally presents at least 1 week after surgery and often months later.

Fungal keratitis usually has a late onset (2 weeks after surgery), although staphylococcus epidermidis and mycobacterium may also present late.





- **Signs and symptoms:-**

A focal area of infiltrate associated with diffuse or localized inflammation, which may extend into untreated area of the cornea outside the flap. The flap may begin to melt.

There may be associated ciliary congestion, 2ry iritis, hypopyon and 2ry glaucoma.





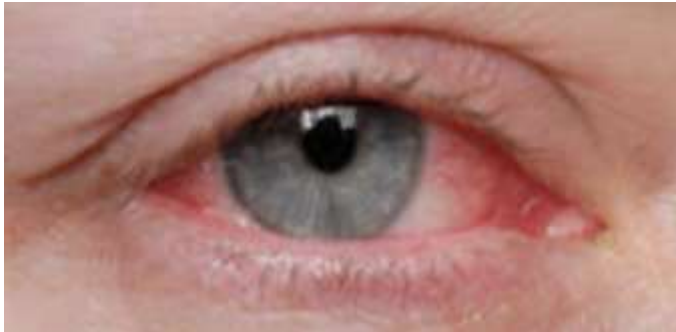- There is a loss in BCVA and UCVA.

- Pain, irritation, photophobia and lacrimation may be present.

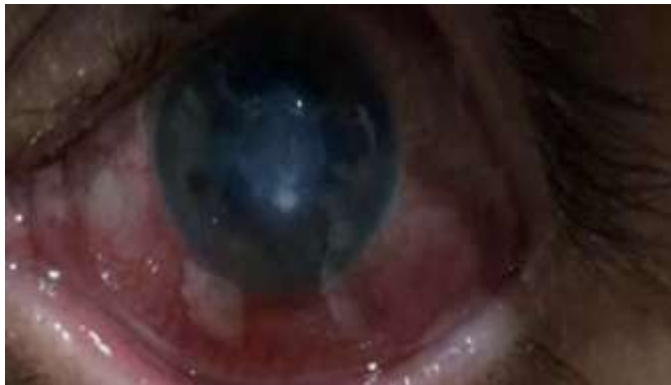- Atypical organisms such as fungi and mycobacteria often are responsible, and so there may be no response to the usual antimicrobial therapy.

- Simultaneous or sequential bilateral involvement of both eyes and infection after flap lift enhancement have also been described.

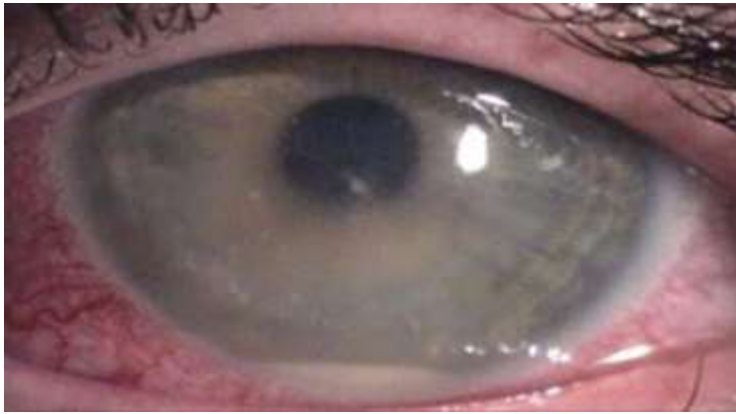



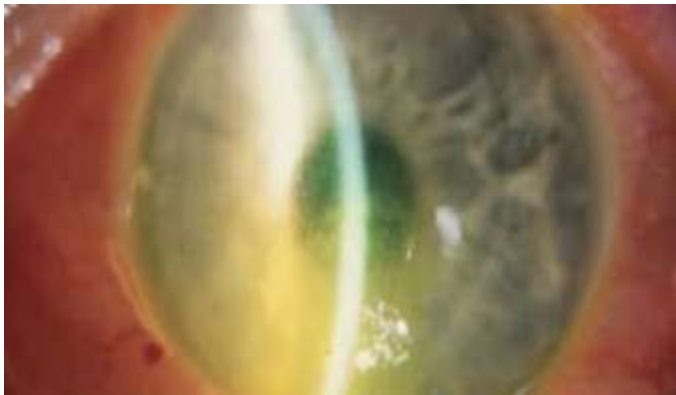
Early post LASIK infectious keratitis



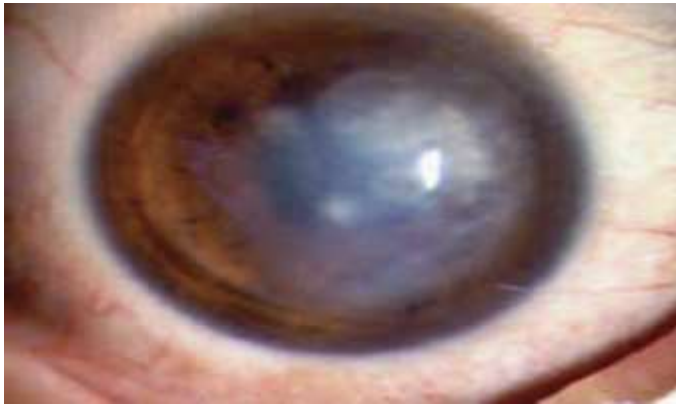
Post LASIK infectious keratitis



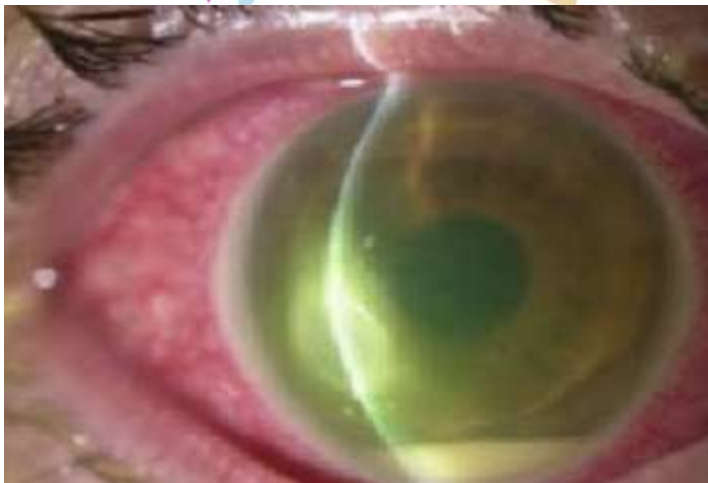Advanced post LASIK inf. keratitis



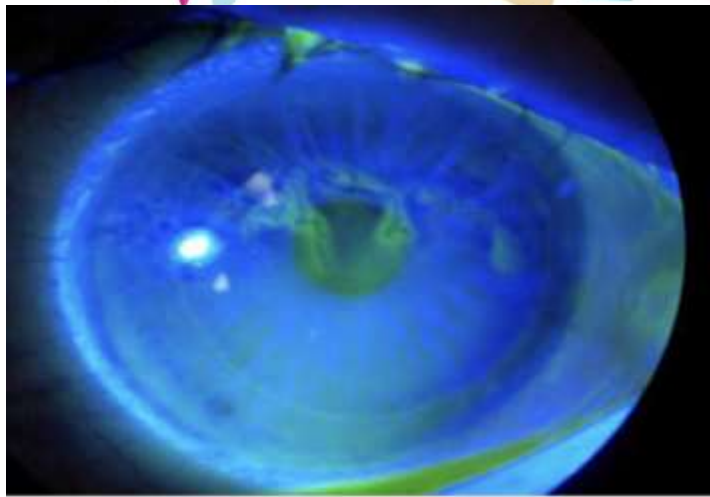
Starting post LASIK stromal scarring



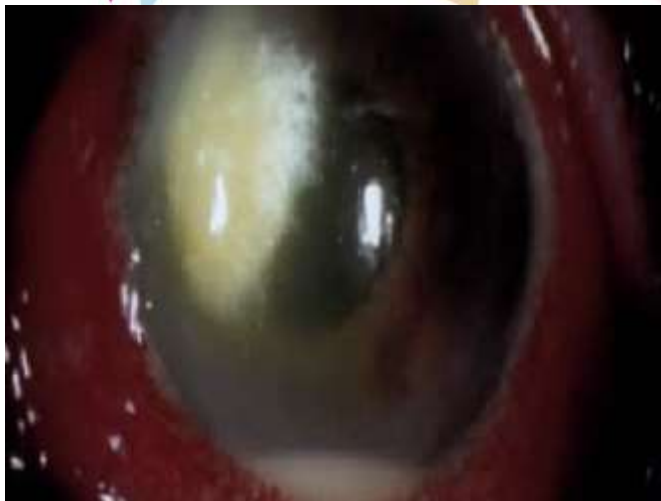Post LASIK corneal scarring



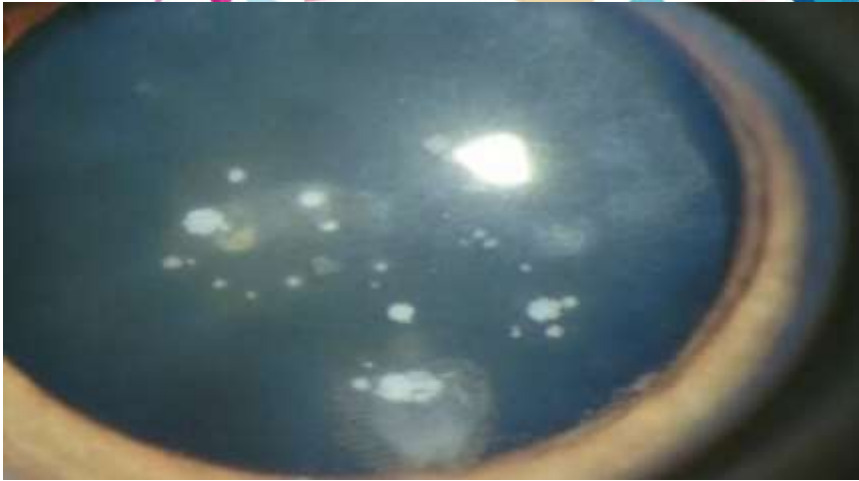
Post LASIK MRSA infectious keratitis



Post LASIK dendritic keratitis



Post LASIK fungal keratitis

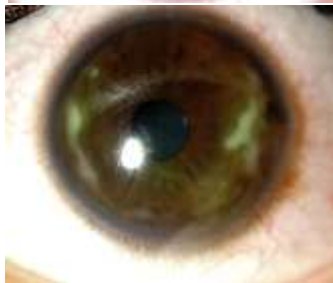
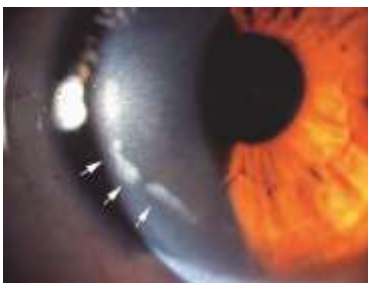
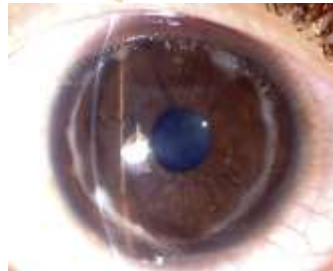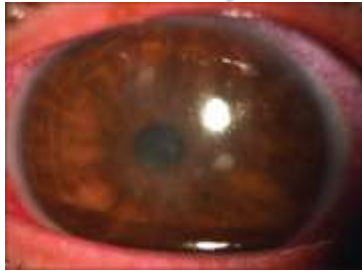Post LASIK nocardia keratitis

D.D.

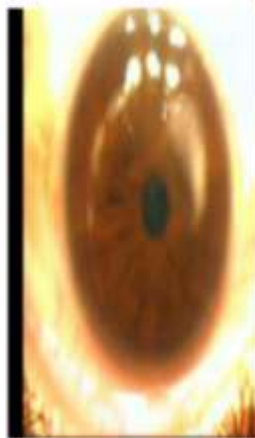Post-LASIK infectious keratitis has to be differentiated from sterile corneal infiltrates, which have been described after PRK and LASIK and present with symptoms similar to infectious keratitis.

It may be caused by staphylococcal-immune mediation 2ry to the use of topical NSAIDs without concomitant use of topical steroids and CL induced hypoxia.



Why sterile Keratitis ???

- No Pain
- No blepharospasm
- Peripheral infiltrates
- Immune ring
- White eye
- Sterile Keratitis had been reported after CXI and PRK
- Negative Lab. results





First day (Post)

Both eyes showed infiltrates at the depithelized ablated corneal center with thickened whitish masses at the margin of area of ablation.



- No blepharospasm
- No Pain





Sub epithelial white infiltrates, which may be associated with immune rings, are seen in the 1st few postoperative days and may result in stromal scarring.

Smears and cultures are negative.

The infiltrates respond to topical steroids.



Complications:-

The infection can spread to involve all layers of the cornea and can cause flap and stromal melting and scarring.

Anterior chamber reaction, hypopyon, 2ry glaucoma, anterior and posterior synechiae, irregular astigmatism, and loss of BCVA and UCVA.








Prevention:-




Preoperative evaluation of the adenexa and the lacrimal apparatus and treatment of any existing condition should become routine for all LASIK patients.

Some surgeons advocate using different instrument sets for the two eyes in case of simultaneous bilateral LASIK.





Rigid asepsis throughout the procedure including painting the lids with povidone-iodine, the use of sterile drapes.



All fluids applied to the eye before, during and after LASIK should be sterile.

Atypical mycobacteria epidemics may originate from the use of nonsterile water to clean instruments.



Diagnosis:-

The most important is the early diagnosis and appropriate therapy.

Any focal infiltrate should be considered infectious until proved otherwise.

Flap elevation and culturing should be performed as early as possible.


Smears help in deciding on immediate treatment, which is then changed according to C/S testing.

Polymerase chain reaction testing and corneal biopsy may be required in some cases.


Treatment :

Empiric therapy is not helpful, as opportunistic and atypical organisms with unusual antimicrobial sensitivities are common and don't respond to conventional therapy.

Elevation of the flap, culture and irrigation of the stromal bed with antibiotic solution (fortified vancomycin 50 mg/ml for rapid onset keratitis and fortified amikacin 35 mg/ml for delayed onset keratitis) for all post-LASIK infectious keratitis.




For rapid onset keratitis, it is recommended to use a fourth-generation topical fluoroquinolone such as gatifloxacin 0.3% or moxifloxacin 0.5% given in a loading dose every 5 minutes for 3 doses and then every 30 min., alternating with an antimicrobial that is rapidly bactericidal and has increasing activity against gram-positive organisms, such as fortified cefazolin 50 mg/ml every 30 min.




In patients in a hospital environment who faced added risk of methicillin-resistant staphylococcus aureus (MRSA), it is recommended to substitute fortified vancomycin 50 mg/ml for cefazolin every 30 min. as it is more effective against MRSA.

Oral doxycycline 100 mg twice daily to inhibit collagenase production and discontinuation of corticosteroids is also advised.


Treatment should be modified according to culture and sensitivity reports.



A decorative border at the top of the page consisting of various colored triangles (pink, blue, yellow, purple) of different sizes and orientations.

For delayed-onset keratitis which is commonly due to atypical mycobacteria, nocardia and fungi, it is recommended to begin therapy with amikacin 35 mg/ml every 30 min. alternating with gatifloxacin 0.3% or moxifloxacin 0.5% every 30 min. along with oral doxycycline 100 mg twice daily and discontinuation of corticosteroids.

This treatment is ineffective for fungal infections that often present late with more extensive keratitis.


A decorative border on the left side of the page featuring a stylized sun with rays and a pink arc, and a cluster of colorful geometric shapes (triangles) in shades of pink, blue, and purple.

Appropriate antifungal agents should be started and modified according to sensitivity reports.

Fungal infections are often difficult to treat because of lack of potent antifungal agents, low penetration through intact corneal epithelium, ocular toxicity and decreased solubility.




The flap may need to be amputated for better penetration of antifungal agents.


In unresponsive cases with extensive corneal involvement, a penetrating keratoplasty may become necessary.

A decorative border at the bottom of the page featuring a stylized sun with rays and a pink arc, and a cluster of colorful geometric shapes (triangles) in shades of pink, blue, and purple.



Take home messages

- 
- 
- 
- * Any corneal focal infiltrate should be considered infectious until proved otherwise.
 - * Flap elevation and stromal bed irrigation with fortified antibiotics should be done as early as possible.
 - * smears and culture and sensitivity testing are essential for appropriate treatment.
 - * corneal biopsy and PCR may be required in certain difficult unresponsive cases.




* Fortified cefazoline, 4th generation fluoroquinolones together with systemic doxycycline for rapid onset infections.

* Fortified amikacine, 4th generation fluoroquinolones together with systemic doxycycline for delayed-onset infections.

* Flap amputation may be required in some cases.

* Some severe unresponsive cases may end in penetrating keratoplasty.



THANK YOU

