


Modified Yamane Technique For secondary IOL implantation

Ahmed A.K. El-Massry, MD, PhD
Head of Ophthalmology Department,
Faculty of Medicine,
Alexandria University, Egypt

No Financial interest


ESO 2019

Yamane Technique in Aniridia




3:52

Management of exposed haptics in modified Yamane technique for secondary IOL implantation

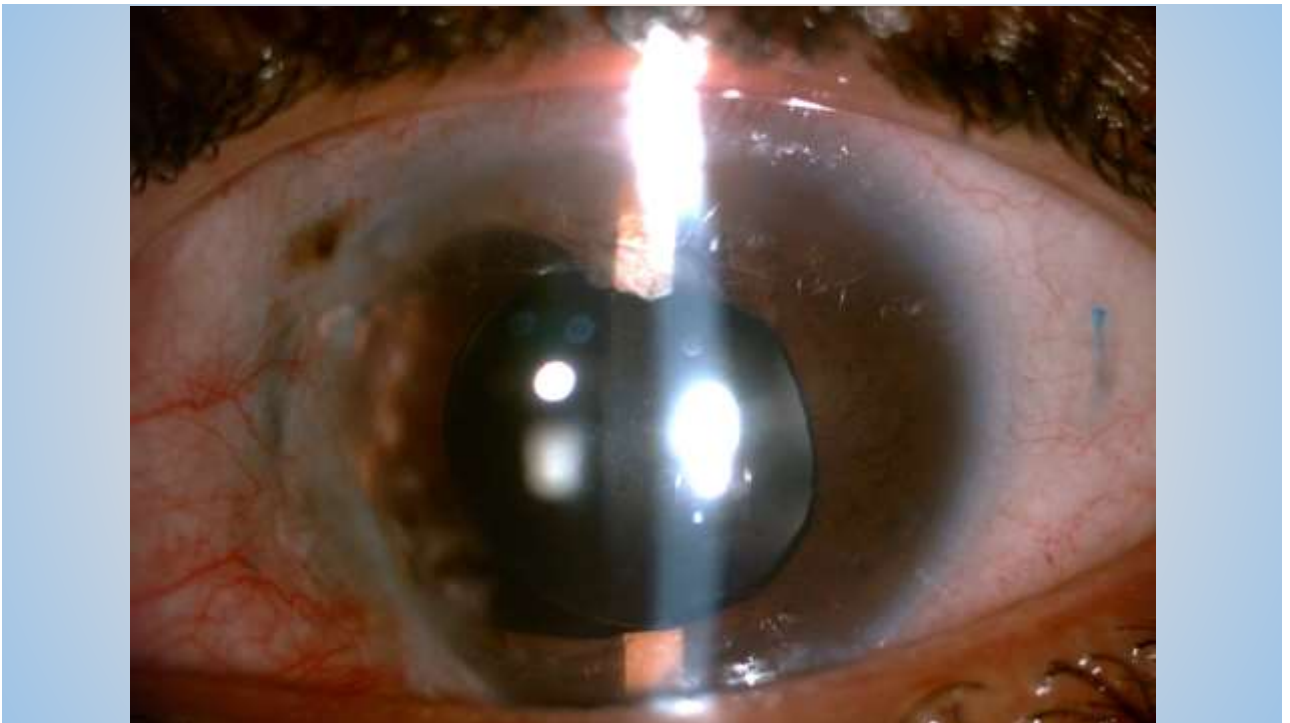
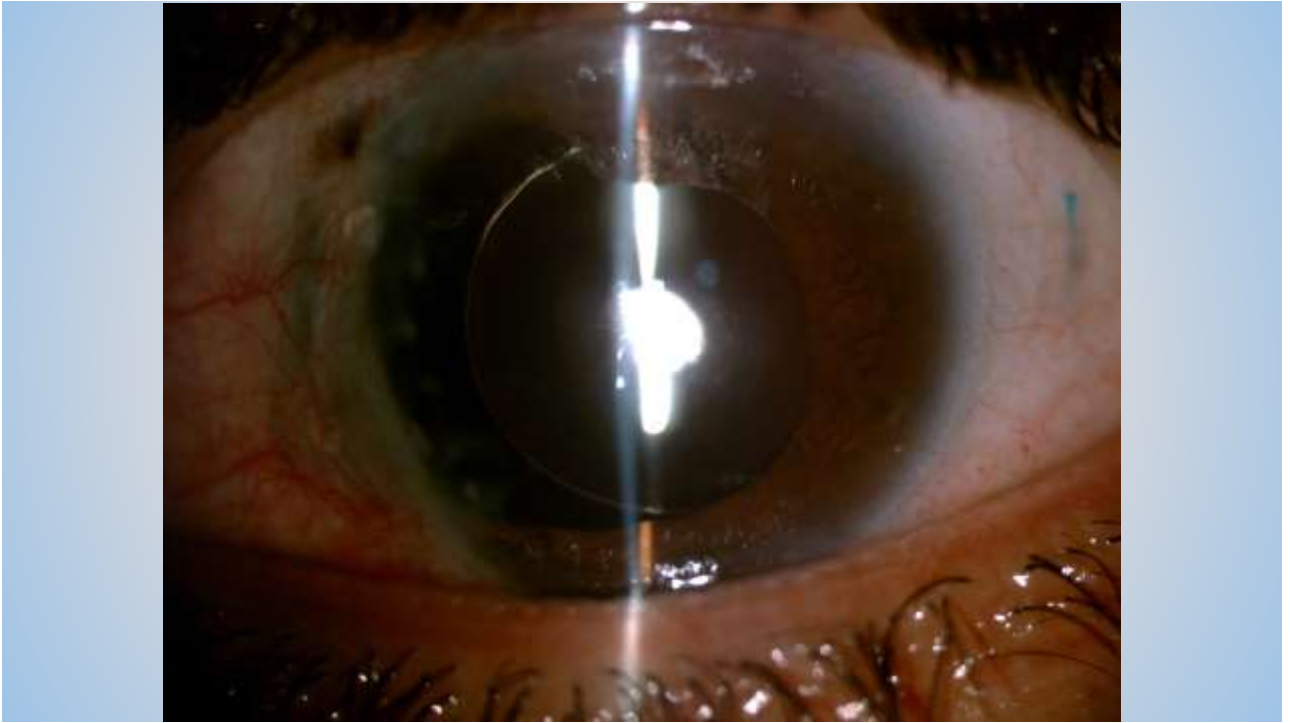


1:00


Learning curve for secondary IOL implantation by Yamane Technique.



4:24

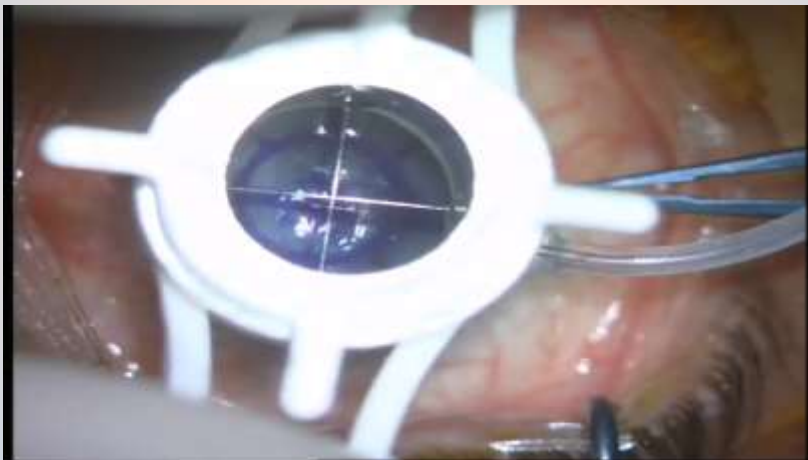


Yamane Technique Trailing Haptic first

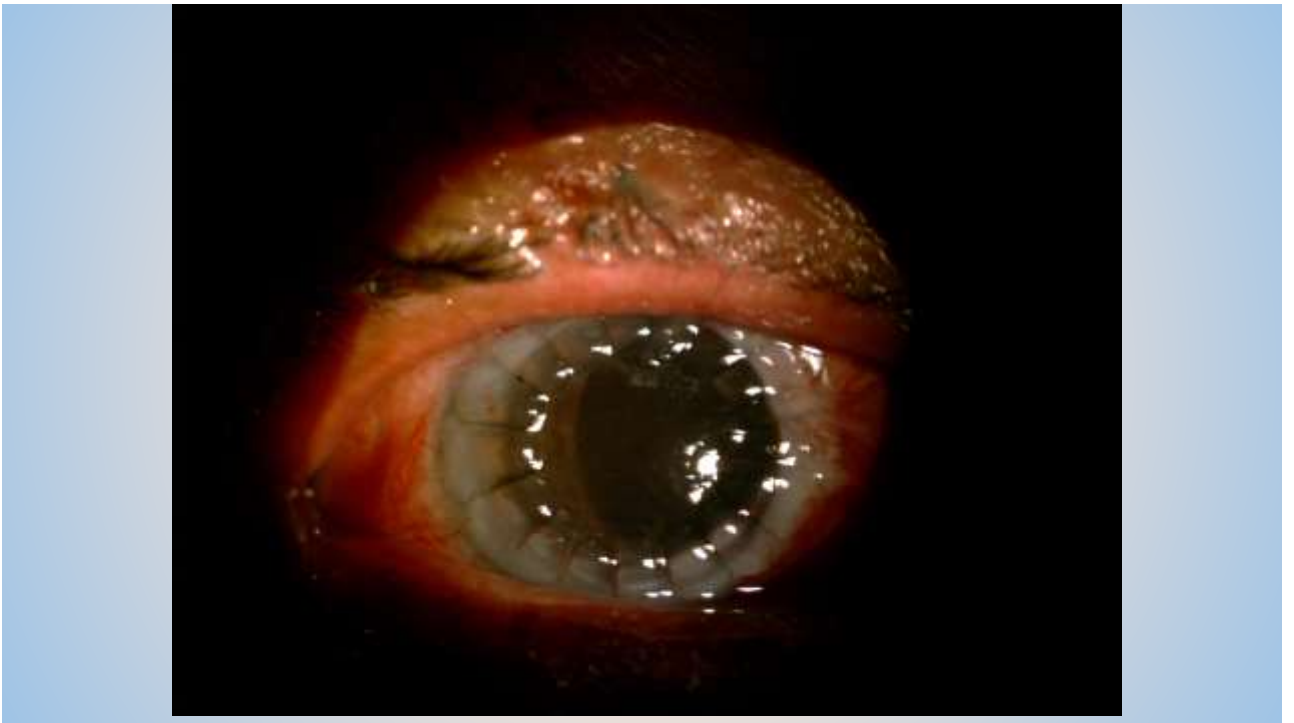
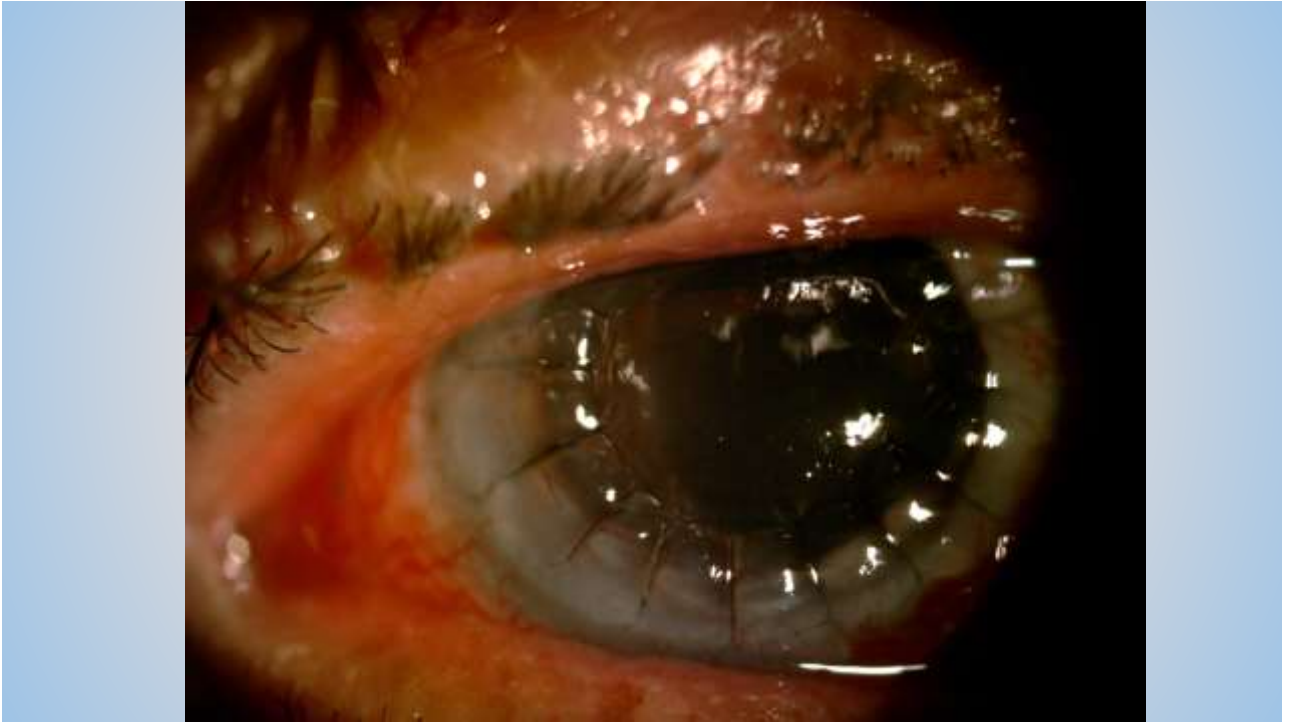

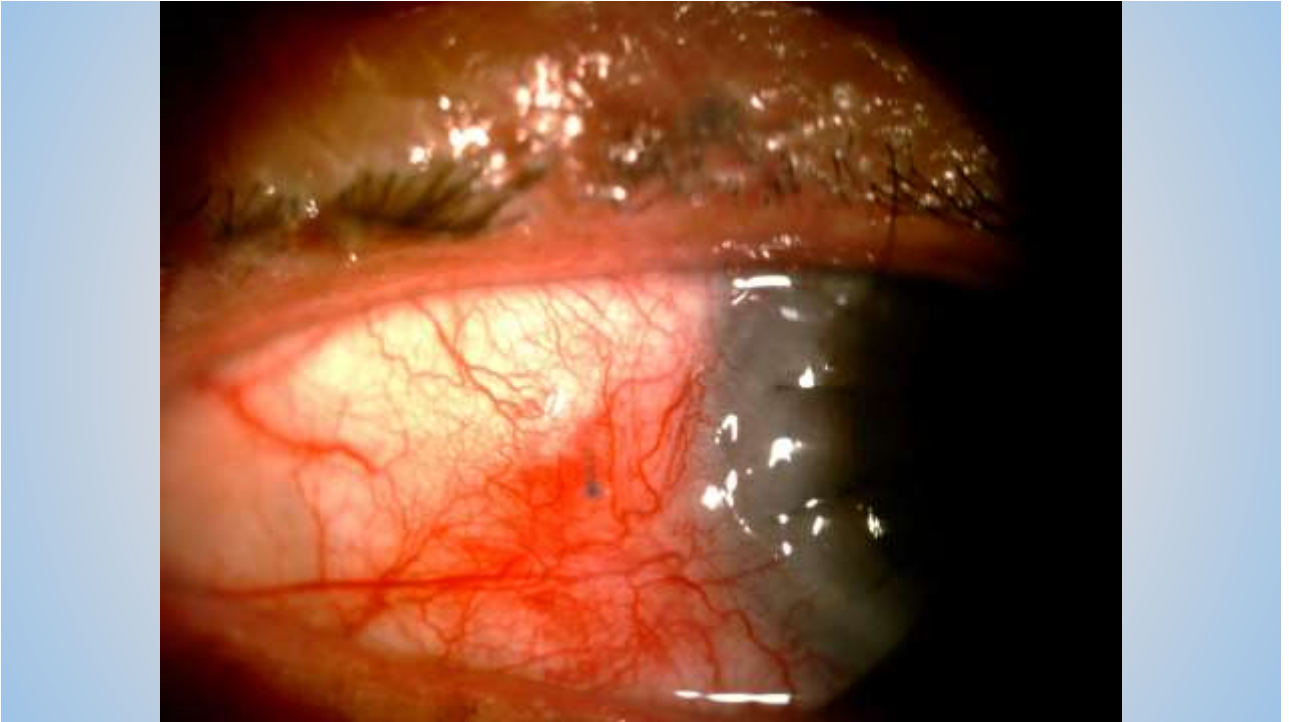
1:55

Yamane technique in PKP



2;23





Conclusions

- 1- Learning curve of this technique is steep*
- 2- Prepare all tools*
- 3 - Anterior Chamber maintainer is a must*
- 4- Trailing haptic first*

Thank You