

المؤتمر السنوي الدولي للجمعية المصرية
INTERNATIONAL CONGRESS OF THE
EGYPTIAN OPHTHALMOLOGICAL SOCIETY

EOS 2019

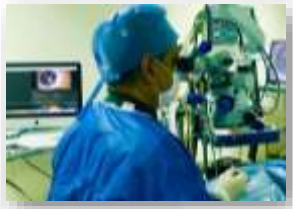27-29 March 2019
Hilton GARDHOUK

In consultation with:

- The American Academy of Ophthalmology AAO
- The Hellenic Society of Intraocular Implants and Refractive Surgery
- The Tunisian Ophthalmological Society
- Nadi AlBasar

FRIDAY 29 March, 2019	
09:00 - 09:30	Coffee Break
09:30 - 11:30	GRANITE - COURSE 1 Strabismus Course: Strabismus Surgical Techniques: Different Procedures
Moderator:	Manal Kassem

09:30 - 09:40	Surgical Anatomy: Ayman Elghonemy
09:40 - 09:47	Before You Start Sameh Glal
09:47 - 09:57	Conjunctival Incisions: Limba Ahmed Taha
	Conjunctival Incisions: Fomix Ayman Elghonemy
09:57 - 10:07	Rectus Muscle Recession: Hangback Ayman Elghonemy
	Rectus Muscle Recession: Direct Scleral Suturing Ahmed Taha
10:07 - 10:17	Rectus Muscle Strengthening: Resection Manal Kassem
	Rectus Muscle Strengthening: Plication Heba Shafik
10:17 - 10:24	LR - Y Splitting Sameh Glal
10:24 - 10:31	Adjustable Sutures Ahmed Awadein
10:31 - 10:38	Transposition Surgery Manal Kassem
10:38 - 10:45	Faden Sameh Glal
10:45 - 10:55	I O Surgery: Myectomy/Recession Heba Shafik
	I O Surgery: Anteriorization/ Resection Mohamed Fathy
10:55 - 11:05	S O Surgery: Silicon Expander Mohamed Fathy
	S O Surgery: Suture Spacer Ahmed Awadein
11:05 - 11:30	Discussion



SURGICAL ANATOMY

Ayman El-Ghonemy M.D. FRCS
Consultant; Pediatric Ophthalmology & Strabismus
Memorial Institute for Ophthalmic Research



EOS 2019

27-29 March 2019
Hilton GARDHOUK

EXTRAOCULAR MUSCLES

Recti muscles

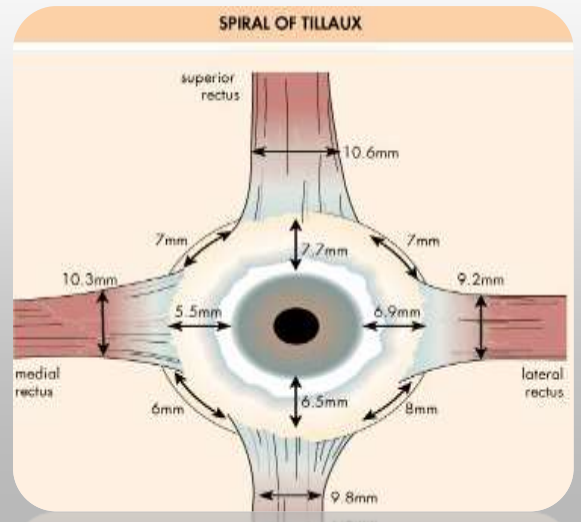
- Distance between insertions around:

7 mm

Insertion width is around:

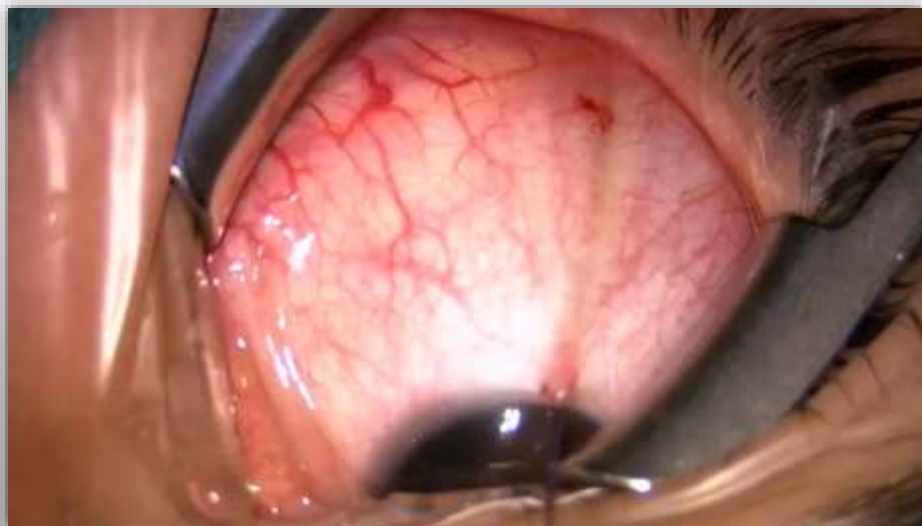10 mm

- Origin posterior, inserted anterior.
 - i.e: weakening: recessing the muscle posteriorly



Proximity of recti muscles' insertions →

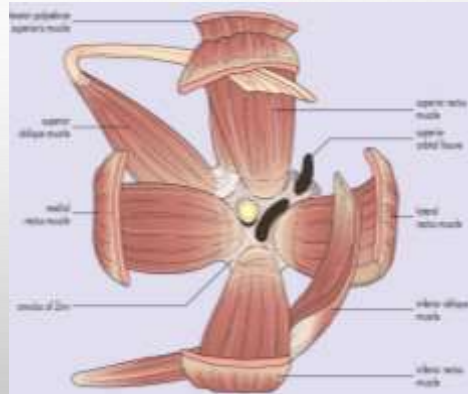
Hook the wrong muscle during strabismus surgery (fornix conjunctival incision)



EXTRAOCULAR MUSCLES EOM

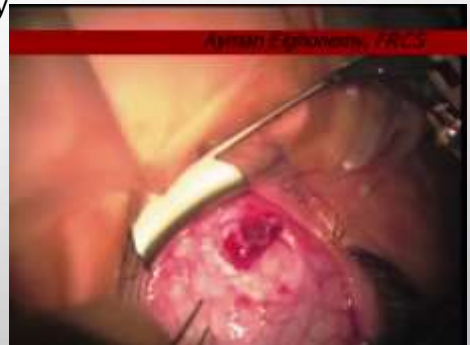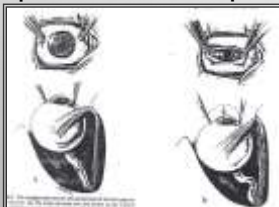
Oblique ms.

- Origin anterior, inserted posterior.



CLINICAL IMPLICATIONS

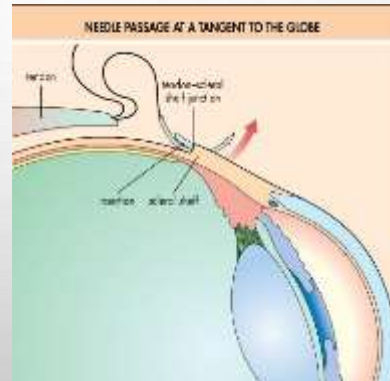
- SUPERIOR OBLIQUE → DEPRESSOR
INFERIOR OBLIQUE → ELEVATOR
- Origin posterior, inserted anterior.
 - i.e: weakening: recessing the muscle posteriorly
- Oblique muscles are not lost during surgery.
- Exaggerated FDT:
 - Recti → Globe pulled up
 - Obliques → Globe pushed down



EXTRAOCULAR MUSCLES EOM

Scleral thickness

- THINNEST OF THE EYE BEHIND THE RECTUS INSERTIONS (0.3 MM).



THANK YOU

الجمعية المصرية لطب العيون
INTERNATIONAL CONGRESS OF THE
EGYPTIAN OPHTHALMOLOGICAL
SOCIETY
EOS 2019

27-29
March
2019

Hilton
Cairo

• The Anatomy & Surgery of Ophthalmology (AO)
• The History, Control of Infection, Diagnosis and
Management of Strabismic Amblyopia
• The Causes of Phorias and Tropias
• Child Refraction

FRIDAY 29 March, 2019	
09:00 - 09:30	Coffee Break
09:30 - 11:30	Strabismus Course: Strabismus Surgical Techniques: Different Procedures
Moderator:	Manal Kassem

09:30 - 09:40	Surgical Anatomy: Ayman Elghonemy
09:40 - 09:47	Before You Start Sameh Glal
09:47 - 09:57	Conjunctival Incisions: Limba Ahmed Taha
	Conjunctival Incisions: Fomix: Ayman Elghonemy
09:57 - 10:07	Rectus Muscle Recession: Hangback: Ayman Elghonemy
	Rectus Muscle Recession: Direct Scleral Suturing Ahmed Taha
10:07 - 10:17	Rectus Muscle Strengthening: Resection: Manal Kassem
	Rectus Muscle Strengthening: Plication Heba Shaik
10:17 - 10:24	LR - Y Splitting Sameh Glal
10:24 - 10:31	Adjustable Sutures Ahmed Awadein
10:31 - 10:38	Transposition Surgery Manal Kassem
10:38 - 10:45	Faden Sameh Glal
10:45 - 10:55	I O Surgery: Myectomy/Recession Heba Shaik
	I O Surgery: Anteriorization/ Resection Mohamed Fathy
10:55 - 11:05	S O Surgery: Silicon Expander Mohamed Fathy
	S O Surgery: Suture Spacer Ahmed Awadein
11:05 - 11:30	Discussion