

المؤتمر السنوي الدولي للجمعية المصرية
INTERNATIONAL CONGRESS OF THE
EGYPTIAN
OPHTHALMOLOGICAL
SOCIETY

EOS 2019
27-29 March, 2019 | Hilton Cairo Helipolis

***Retinal expansion
and
Macular massage***

Hazem Elnashar, MD, FRCs
Memorial Institute Of Ophthalmic Research

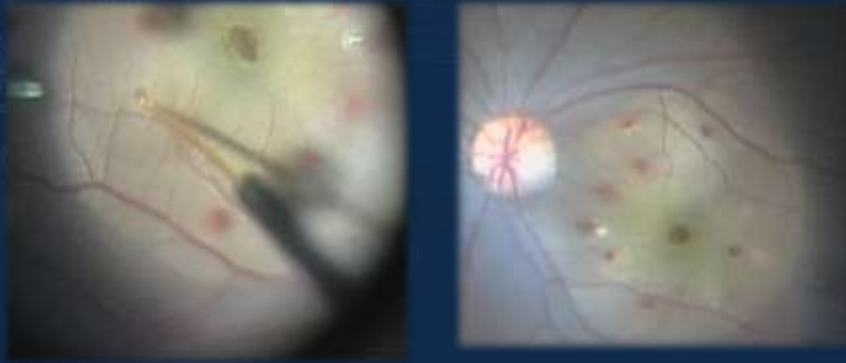
The Ota Memorial Lecture
For Cataract / February 2008



How to manage large full thickness MH ?

- Standard technique (PPV + ILM peeling)
- Adjuvant :
 - Inverted ILM flap
 - Macular graft
 - Autologous serum and platelet concentration
 - Retinal expansion technique
 - Macular massage

Retinal expansion technique (post pole detachment)



المؤتمر العgyptي للجمعية المصرية
INTERNATIONAL CONGRESS OF THE
EGYPTIAN
OPHTHALMOLOGICAL
SOCIETY

EOS 2019

27-29 HELWAN
March, 2019 CAIRO HELWAN POLIS

Retinal expansion technique

RETINA
THE JOURNAL OF RETINAL AND VITREOUS DISEASE

Wolters Kluwer

Account | Login | Register | Subscribe | Help

Macular Detachment for the Treatment of Persistent Full-Thickness Macular Holes

Fotis, Konstantinos, MD, MSc, FEBO¹; Alexander, Phillip, MBA, DM, FRCOphth¹; Sax, James, MBBS²; Reddie, Ian, LLB, MBBS, MACLM, FRANZCO, MAICD²; Kang, Chee Yiong, MBBS, FRANZCO³; Chandra, Aman, BSc(Hons), MBBS, MRCSEd, FRCOphth, PhD, MFSTEd, FRCSEd⁴

Section Editor(s): Williams, George A.

RETINA: October 31, 2018 - Volume Publish Ahead of Print - Issue - p

المؤتمر العgyptي للجمعية المصرية
INTERNATIONAL CONGRESS OF THE
EGYPTIAN
OPHTHALMOLOGICAL
SOCIETY

EOS 2019

27-29 HELWAN
March, 2019 CAIRO HELWAN POLIS

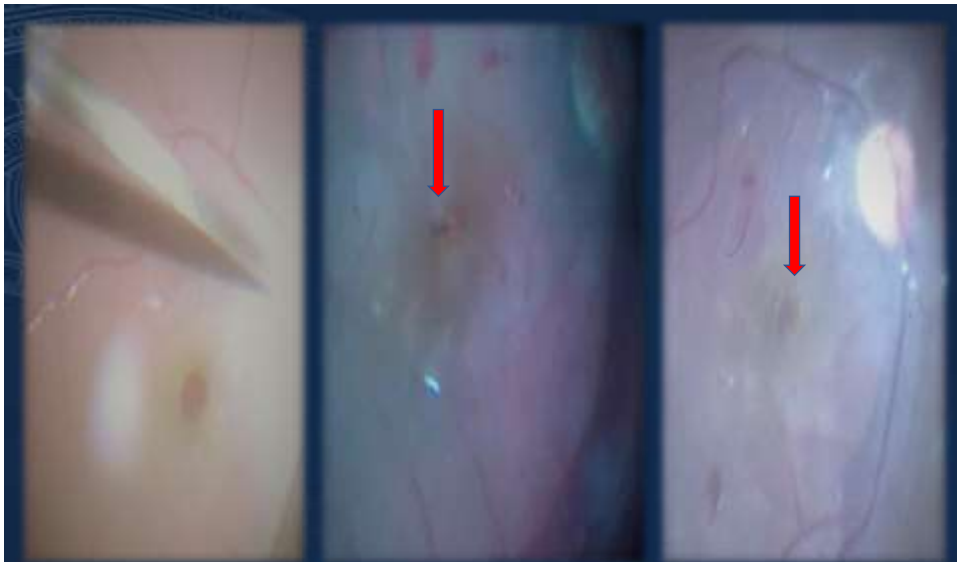
Macular massage

- After det post pole the retina is massaged gently around the hole from the periphery to the center in order to join the edges of hole mechanically.
- Hole → oval → slit-like and eventually closes at the end of the procedure.
- Scraper

المؤتمر العيوني الدولي - الجمعية المصرية
INTERNATIONAL CONGRESS OF THE
EGYPTIAN
OPHTHALMOLOGICAL
SOCIETY

EOS 2019

27-29 HELTON
March, 2019 CAIRO HELIOPOLIS

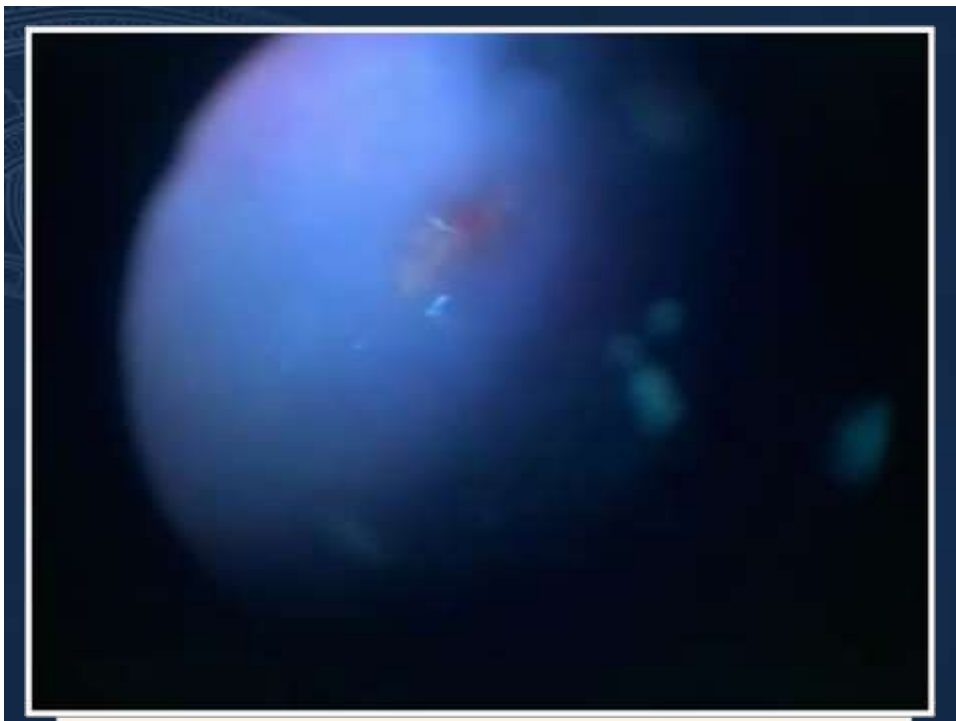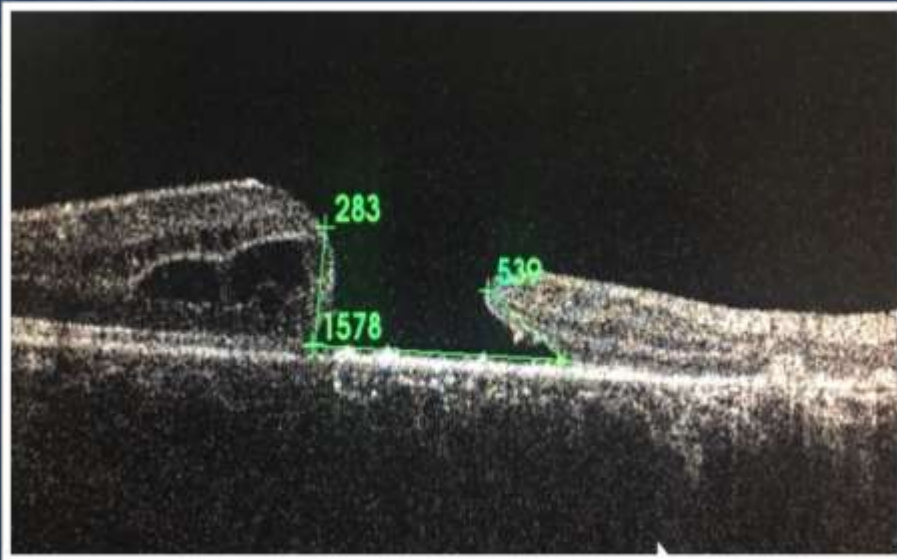


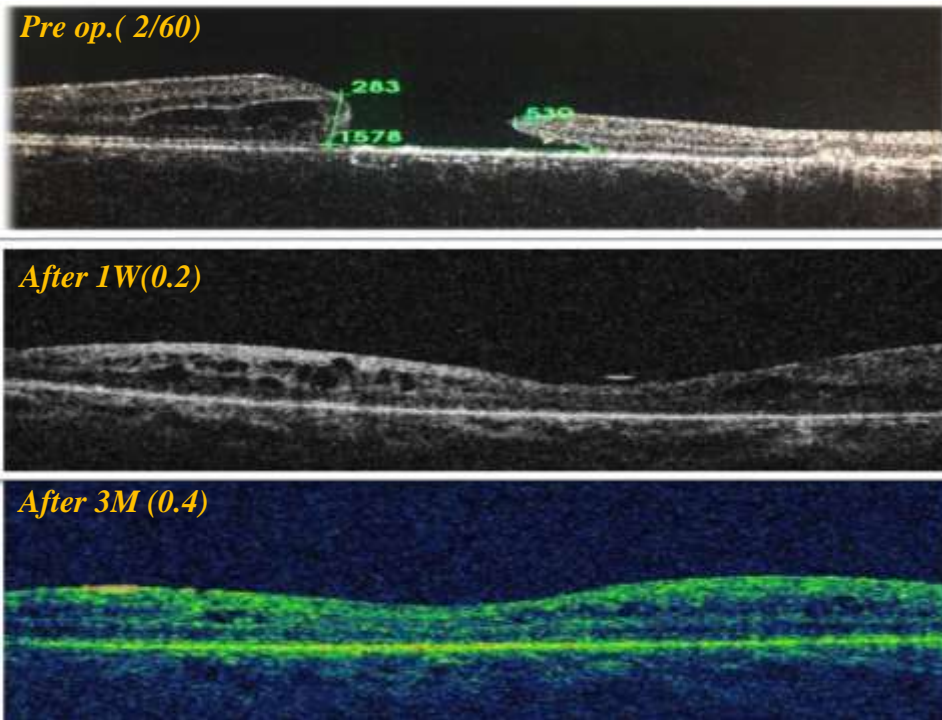
المؤتمر العيوني الدولي - الجمعية المصرية
INTERNATIONAL CONGRESS OF THE
EGYPTIAN
OPHTHALMOLOGICAL
SOCIETY

EOS 2019

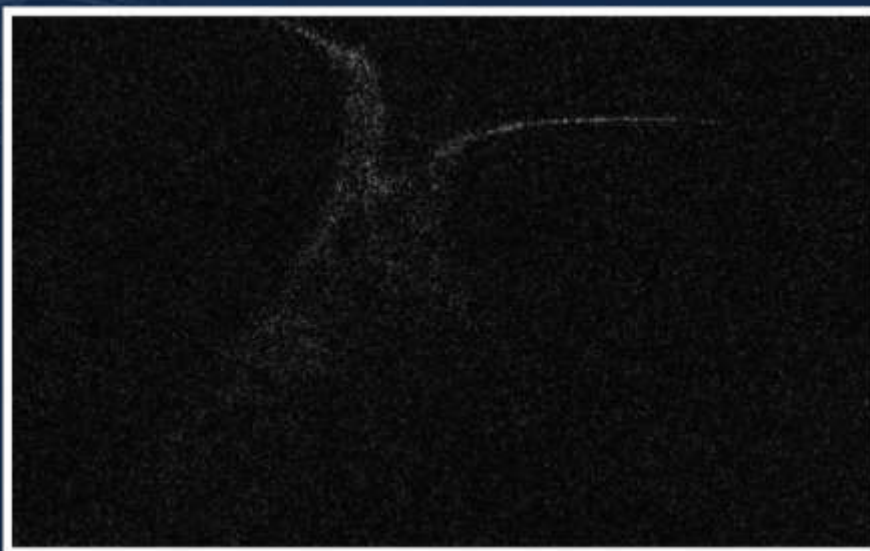27-29 HELTON
March, 2019 CAIRO HELIOPOLIS

1) Traumatic macular hole (2/60)

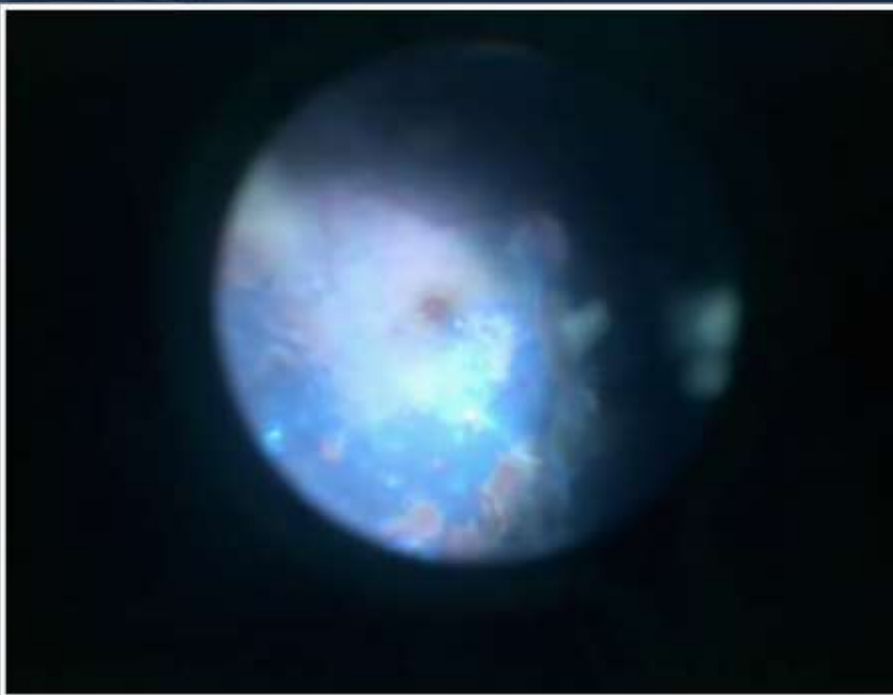



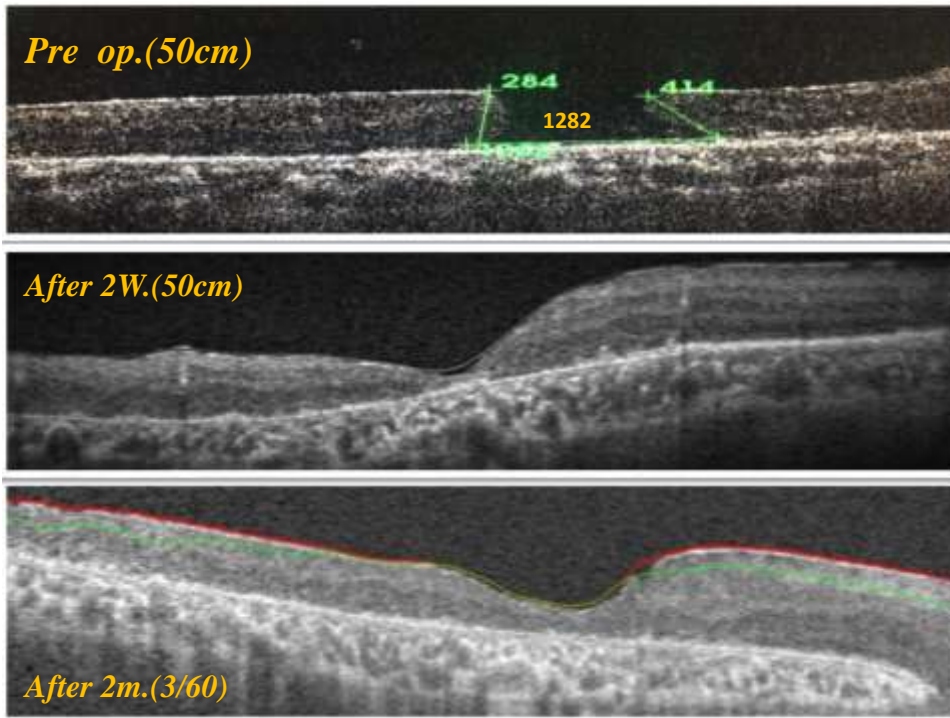


2) TRD involving macula(H.M)

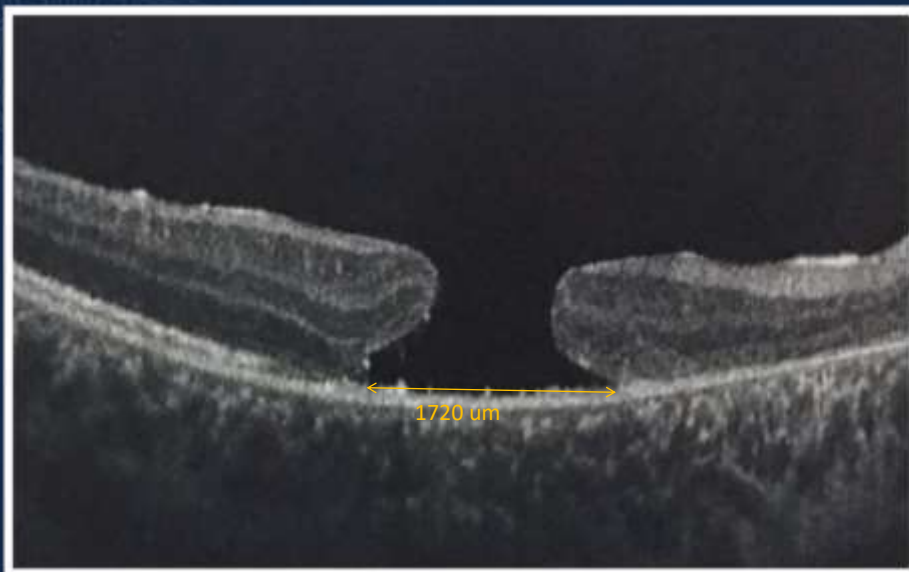


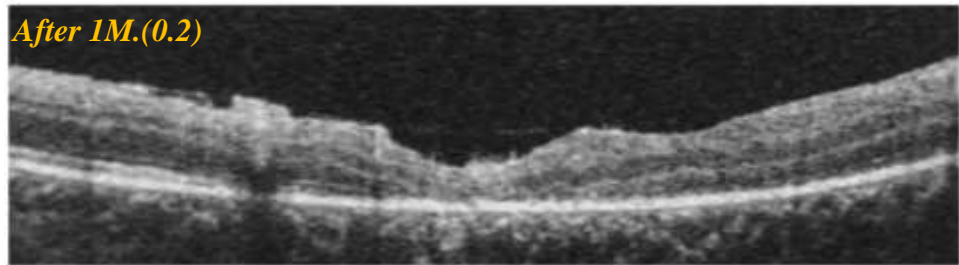
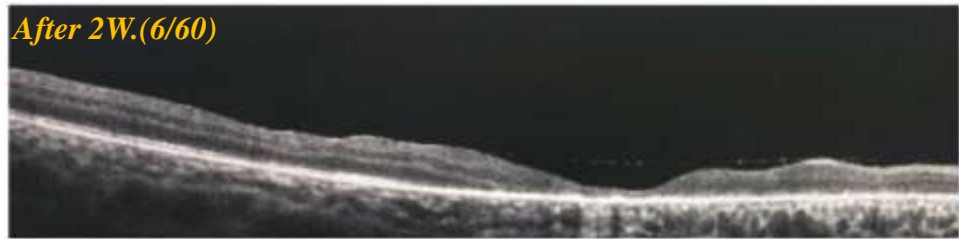
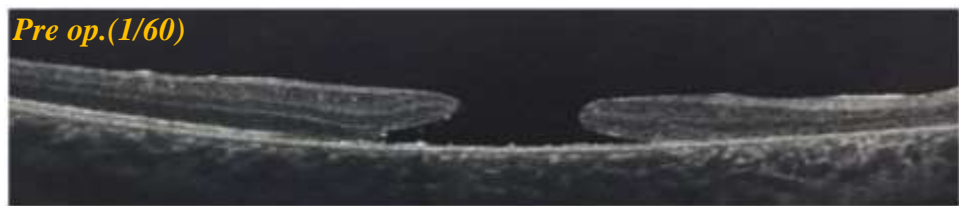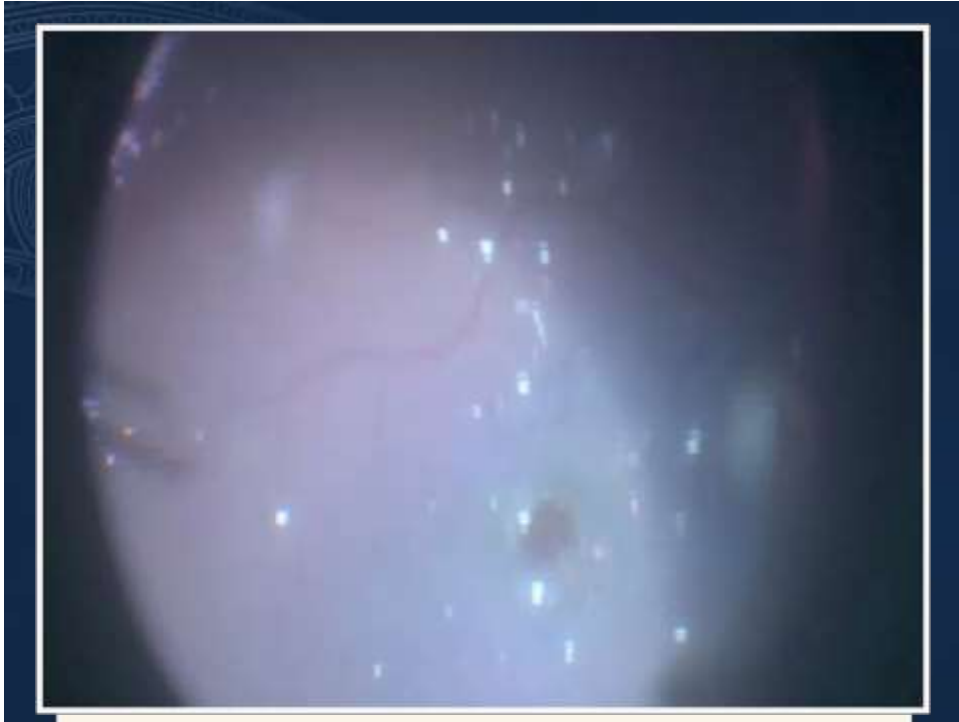8 m. post phaco-vitreectomy(50cm)



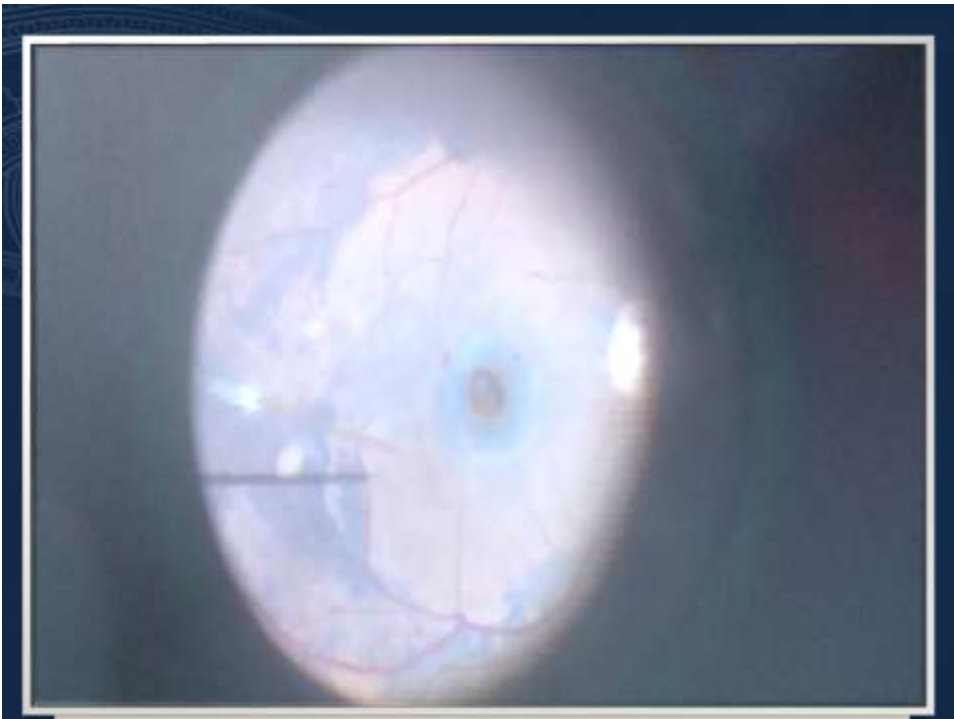
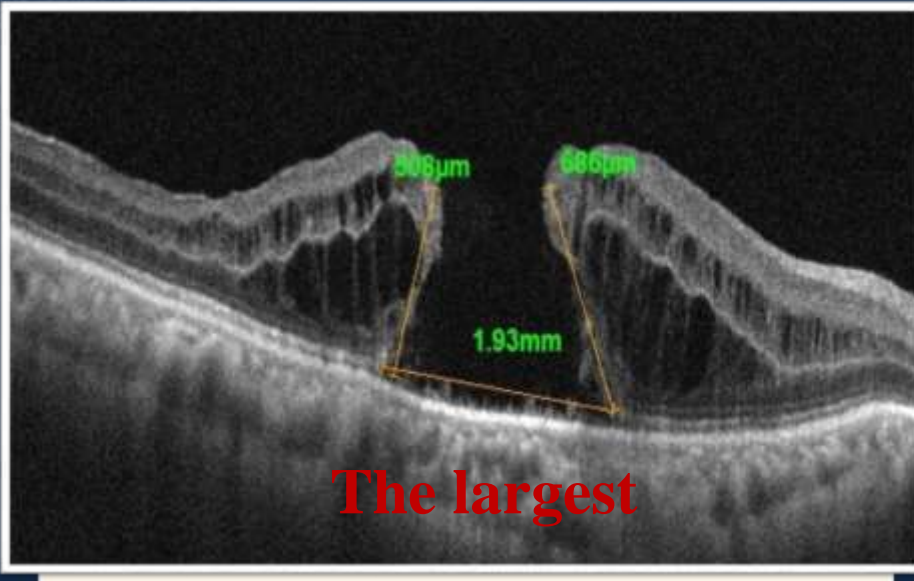


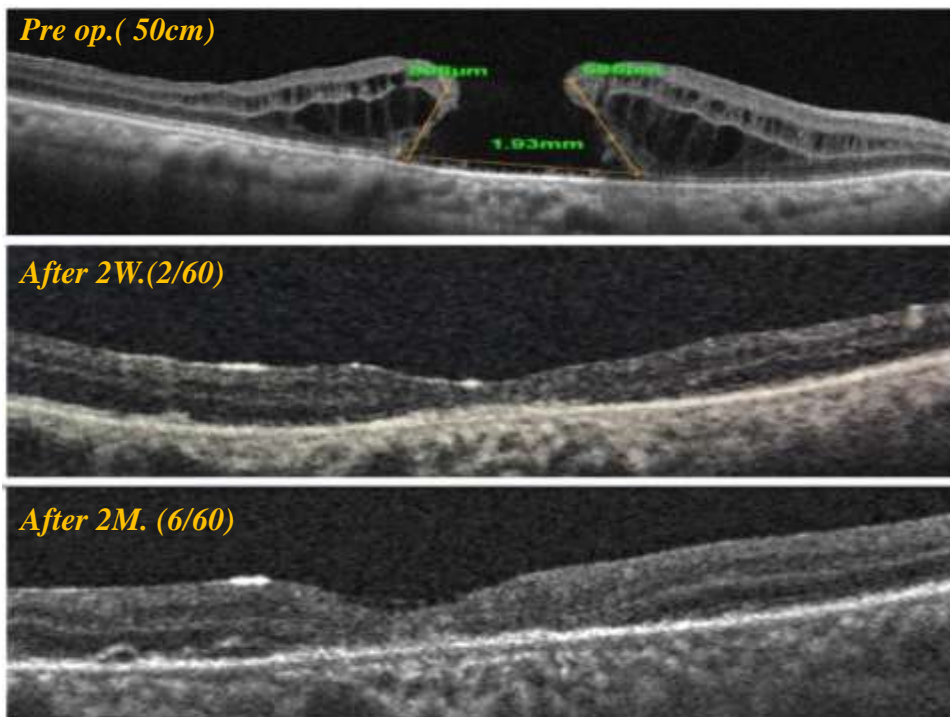
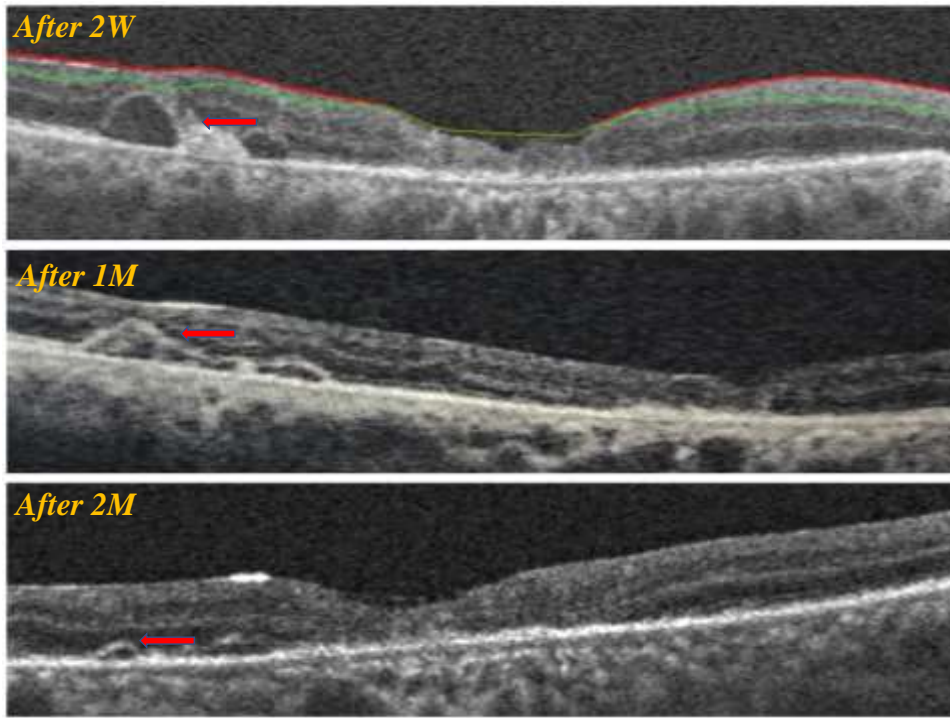
3)Traumatic macular hole (1/60)





4) Persistent macular hole (C.F50cm)





To summarize ...

- 4 patients with large MH (from 1282 to 1930 um)
 - 2 traumatic
 - 1 persistent
 - 1 post ppv for TRD
- Type 1 closure of the MH (closure **without any defect** of the neurosensory retina) and close with retinal tissue not gliosis
- rapid gain in visual acuity

المؤتمر العيوني الدولي - الجمعية المصرية
INTERNATIONAL CONGRESS OF THE
EGYPTIAN
OPHTHALMOLOGICAL
SOCIETY

EOS 2019

27-29 HELTON
March, 2019 | CAIRO HELIOPOLIS

Take home massage

- Standard technique alone Not enough .
- combining retinal expansion and macular massage techniques into one technique, can achieve promising results (more evaluation & follow up).
- We can use this technique as **1ry or 2ry treatment**

المؤتمر العيوني الدولي - الجمعية المصرية
INTERNATIONAL CONGRESS OF THE
EGYPTIAN
OPHTHALMOLOGICAL
SOCIETY

EOS 2019

27-29 HELTON
March, 2019 | CAIRO HELIOPOLIS



Thank You!