Recent diagnostic modalities of ocular surface disorders

Sihem Lazreg
Algeria

Ocular surface

- Functional unit:

- Lids (Blink)
- Conjunctiva
- Cornea , limbus
- Tear film
- Meibomian glands

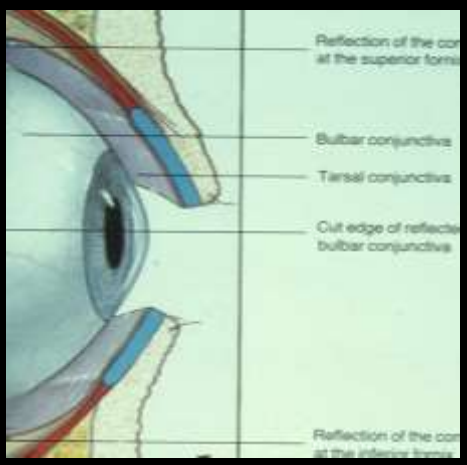

Ocular surface

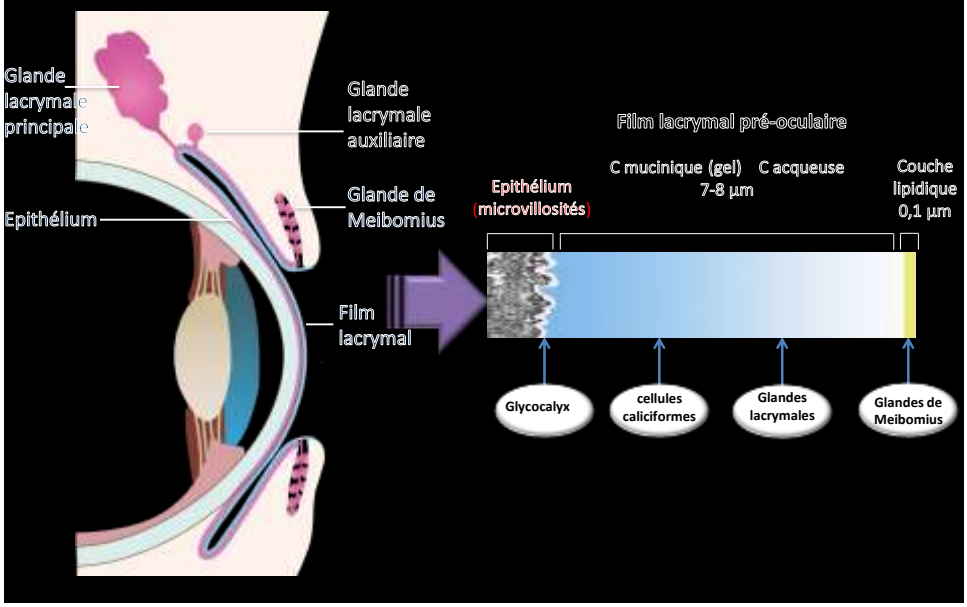

Normal tear film

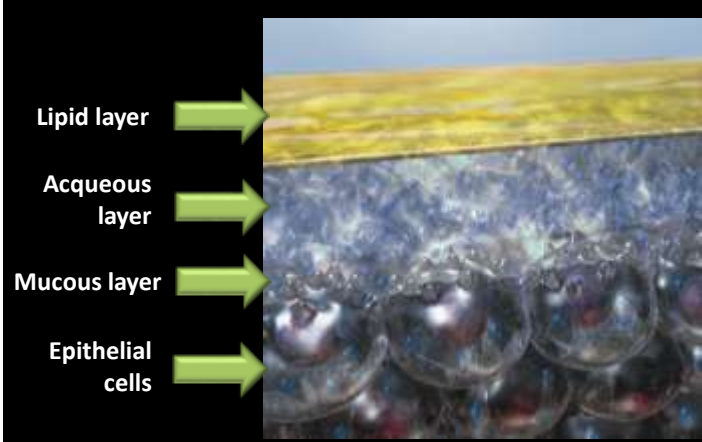

Normal evaporation rate is 33%

- Dry eye is a multifactorial disease of the ocular surface characterized by a loss of homeostasis of the tear film and accompanied by ocular symptoms, in wich tear film instability and hyperosmolarity, ocular surface inflammation and damage, and neurosensory abnormalities play etiological role.

What is the purpose of a diagnosis?

Dry Eye testing

What tests do I need to do to confirm this?

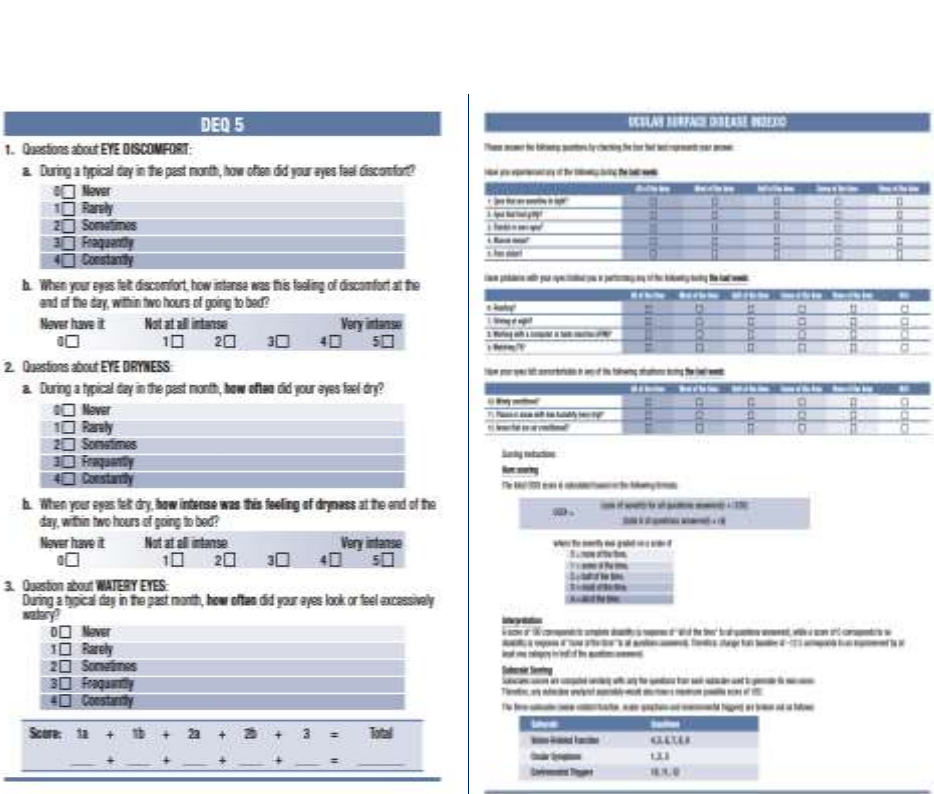

DEQ 5

1. Questions about **EYE DISCOMFORT**:
   a. During a typical day in the past month, how often did your eyes feel discomfort?
      - 0☐ Never
      - 1☐ Rarely
      - 2☐ Sometimes
      - 3☐ Frequently
      - 4☐ Constantly
   b. When your eyes felt discomfort, how intense was this feeling of discomfort at the end of the day, within two hours of going to bed?

Never have it	Not at all intense			Very intense
0☐	1☐ 2☐	3☐	4☐	5☐

2. Questions about **EYE DRYNESS**:
   a. During a typical day in the past month, **how often** did your eyes feel dry?
      - 0☐ Never
      - 1☐ Rarely
      - 2☐ Sometimes
      - 3☐ Frequently
      - 4☐ Constantly
   b. When your eyes felt dry, **how intense was this feeling of dryness** at the end of the day, within two hours of going to bed?

Never have it	Not at all intense			Very intense
0☐	1☐ 2☐	3☐	4☐	5☐

3. Question about **WATERY EYES**:
   During a typical day in the past month, **how often** did your eyes look or feel excessively watery?
      - 0☐ Never
      - 1☐ Rarely
      - 2☐ Sometimes
      - 3☐ Frequently
      - 4☐ Constantly

Score:	1a	+	1b	+	2a	+	2b	+	3	=	Total
	___	+	___	+	___	+	___	+	___	=	_____

OCULAR SURFACE DISEASE INDEX©

NIBUT

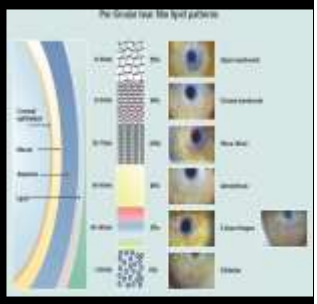

Fluorescein

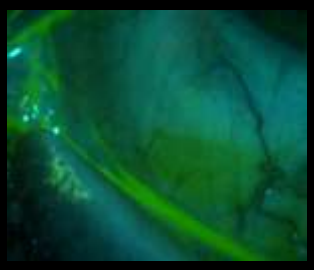

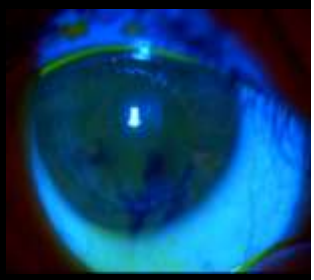

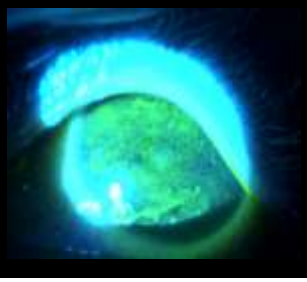

Lissamin green

Coloration of mucous, apoptotic cells and tissues.

Schirmer test I

Quantitative value of the tear film .

> 10 mm : normal

6 à 10 mm :moderate dry eye

< 6 mm :severe dry eye

Osmolarity

- Higher of both eye and difference
- Variability questioned
- Cut-offs (Sullivan et al., 2010, Keech et al., 2013):
  - normal (302.2 ± 8.3 mOsm/L)
  - mild to moderate (315.0 ± 11.4 mOsm/L)
  - severe (336.4 ± 22.3 mOsm/L)

Electrolyte	Concentration(mMol/L)
Sodium	132
Potassium	24
Bicarbonate	32.8
Calcium	0.8
Magnesium	0.61

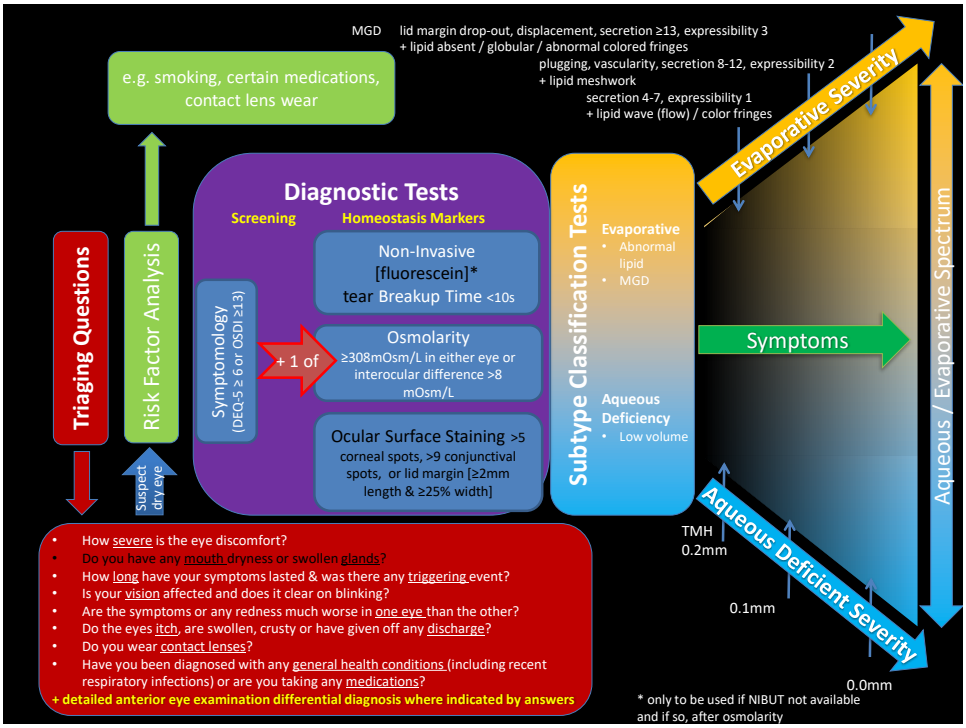

The revenge of ocular surface : imaging

The importance of ocular imaging in the diagnosis of dry eye disease

- Diagnosis /etiology
- Etiological arguments
- Severity
- Follow up and treatment

- NIBUT
- Meniscometry
- Meibography
- Interferrometry
- Blink analysis

Tear film stability evaluation

Key element in the pathophysiology of dry eye

BUT has limits ……

Can be modified by the quantity of fluorescein
> Poor reproducibility +++
> Hight variability between doctors and in the same patient;

Tear film stability

Non invasif break up time (NIBUT) : The solution ?

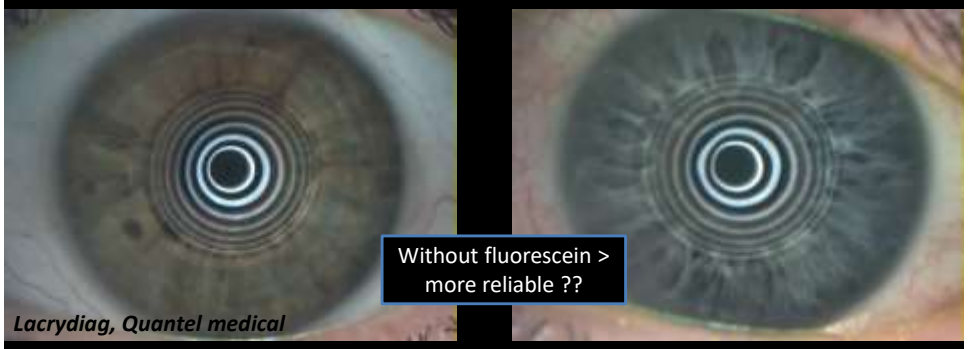

Test	SD of repeated measures	Healthy population mean	Clinical difference to detect	Minimum sample size per group
NIBUT	7.2 [38] 2.0 [36]	11.2 ± 6.8 [38] 10.4 ± 4.2 [36]	5 s	33 Tearscope 3 Keratograph 5m

- Hight deviation…
- Poor reproducibility according to devices …
- Automatic versus manual ?

NOT DEFINED YET ……

Lee et al. Clin Ophth, 2016
Wolffsohn et al. DEWS 2, 2017

Tear volume

Ménisc = tear volume + basal secretion

Variable according to the blinking interval and drops instillation (diagnosis)

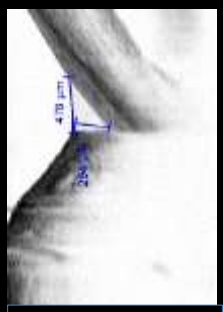

Hight +++

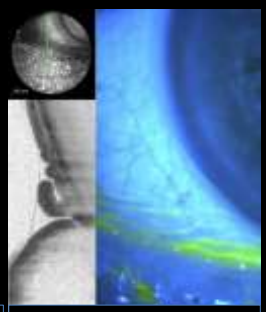

conjonctivochalasis

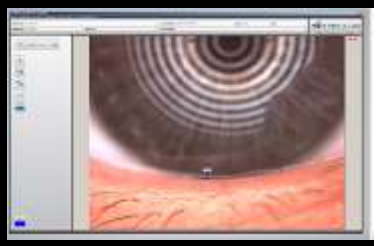

Measures on pictures (Oculus Keratograph 5M, Lacrydiag)

SD of repeated measures	Healthy population mean	Clinical difference to detect
0.03 (Keratograph 5m) [39]	0.29 ± 0.04 mm (Keratograph 4) [40] 0.27 ± 0.12 (Keratograph 5m) [39] 0.19 ± 0.02 mm (with OCT) [41] 0.34 ± 0.13 mm (with OCT) [42]	

Normal = 0,3mm

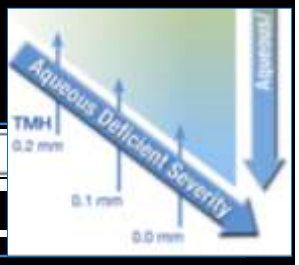

Carracedo et al. Acta, 2018; Li et al. Eye Contact lens; 2012 DEWS 2, Wolffsohn et al. Ocular Surface; 2017 Rousseau et al. JFO, 2018

Meibomian glands : Structure

Infrared meibography : what can we analyse ?

Shortening

Tortuosity

« Dropout » or meibomian gland atrophy

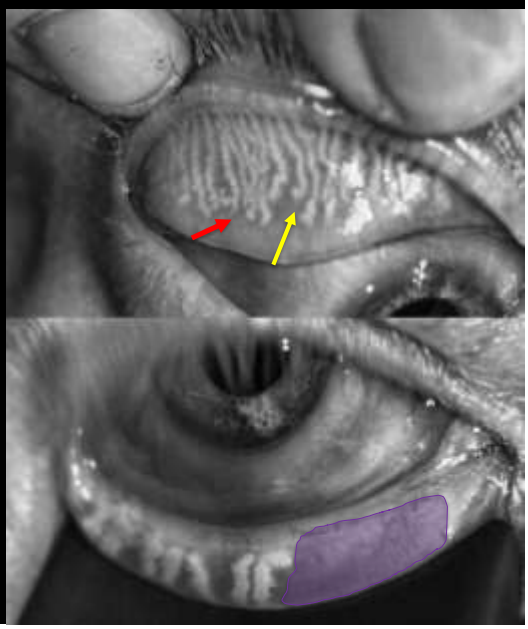

Arita et al. Exp Eye Res, 2017

Infrared Meibography : automatisation



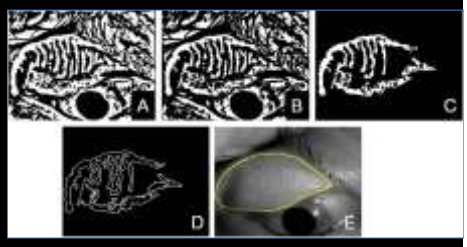

Atomated detection of MG atrophy

Age modifications +++

No normative data yet .....

Arita et al. BJO, 2013

MEIBOGRAPHY 3D

Automated and guided system to understand in a scientific way and to communicate easily with the patient

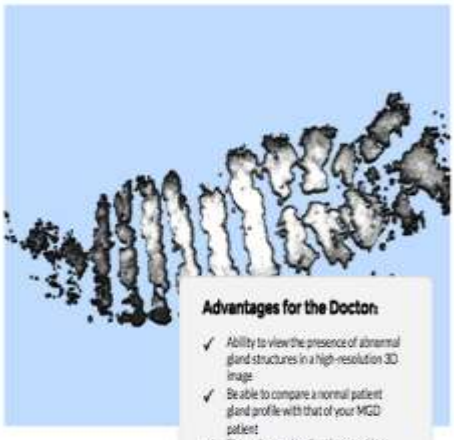

Advantages for the Doctor:

- ✓ Ability to view the presence of abnormal gland structures in a high-resolution 3D image
- ✓ Be able to compare a normal patient gland profile with that of your MGD patient
- ✓ The option to visualize these problem areas in high definition vs. that of a less clear 2-dimensional image
- ✓ The ability to potentially pin point the areas of gland abnormality in detail

Benefits for the patient:

- ✓ For the first time a 3D image can help them understand the structure of the eye lid and how their Glands are different from a healthy individual
- ✓ See for themselves, with the Doctors explanation, why they are getting eye discomfort and fluctuating vision
- ✓ Help them understand why you are recommending a specific therapy

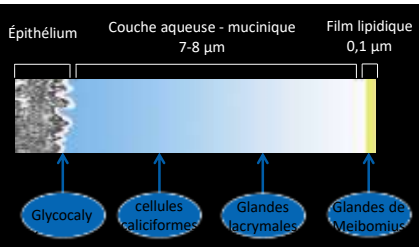

Meibomian glands :
Function = interferometry

Lipid layer reflect the function of MG

La couche lipidique forme des franges interférrométriques

Lipiview, Tearscience

Automated measure of the lipid layer thickeness : Interférometry (Normal > 75nm) Reproducible

MGD diagnosis : Sensitivity / Spécificity : 65%

Finis et al. Cornea, 2013
Arita et al. Exp Eye Res 2017

Interferometry

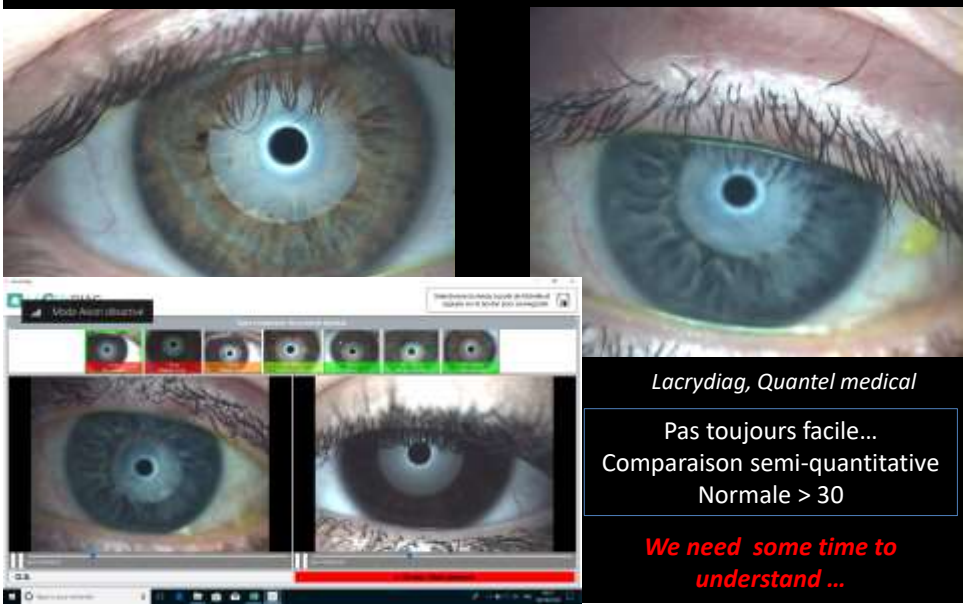

Lacrydiag, Quantel medical

Pas toujours facile…
Comparaison semi-quantitative
Normale > 30

We need some time to understand …

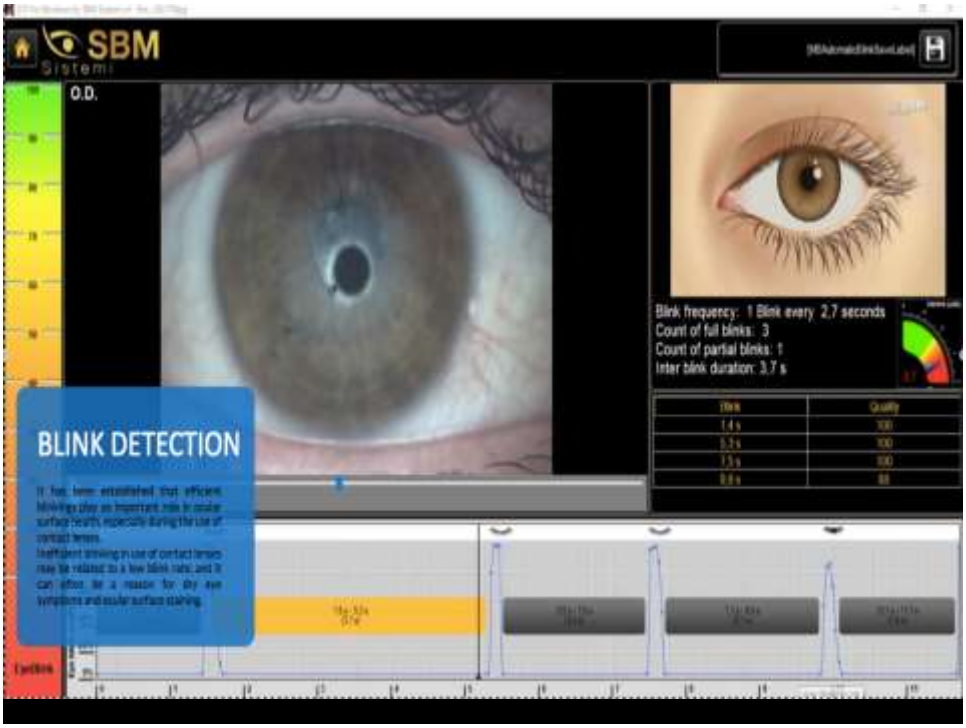

Blinking analysis : version 2.0

Blinking exercises

Daily Exercices

https://www.reseau-chu.org/article/oeil-sec-protection-desobstruction-reeducation-le-traitement-en-3-phases-de-bordeaux/

DEMODEX

Cylindrical dandruff and blepharitis

How to study inflammation of eyelids and Demodex Brevis

BLEPHARITIS

The human skin surface is known to house millions of bacteria, though some people have more than the average number. Blepharitis is an inflammation caused by some bacteria that lie at the base of eyelashes.

They produce dandruff-like flakes in the skin, which lead to infection and inflammation. Problems with the meibomian oil glands (meibomianitis) in the eyelids can also cause blepharitis. The development of inflammation is also associated with risk factors such as dandruff, dry eyes, acne rosacea, or bacteria. This is a common eye disorder affecting all age groups.
When the patient is found with blockage of the oil glands in the eyelids, poor quality of tears, and redness of the lining of the eyelids, the type is Meibomian blepharitis. If a hard, matted crust is formed on the eyelashes, and while removing these some small sores are formed on the eyelashes that ooze and bleed, it is called Ulcerative blepharitis

Management

70%

The type of blepharitis can be determined based on the appearance of the eyelid edges. If the symptoms frequently exhibited by the patients are mild sticking eyelids, thickened lid margins, and missing/misdirected eyelashes, then the type of blepharitis is said to be Staphylococcal. If the patients show mild redness of the eyelids or scales around the base of eyelashes, then it is Seborrheic blepharitis.

OTHER POSSIBLE EXAMINATIONS

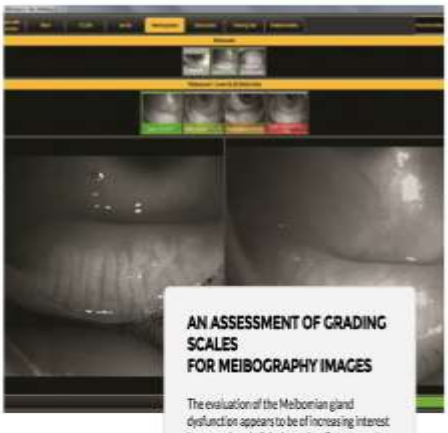

AN ASSESSMENT OF GRADING SCALES FOR MEIBOGRAPHY IMAGES

The evaluation of the Meibomian gland dysfunction appears to be of increasing interest in research and clinical practice. Consequently the evaluation of Meibomian glands morphology using meibography is of high interest for both, researchers and clinicians.

WHITE TO WHITE MEASUREMENT

Evaluation of corneal diameter from limbus to limbus (white-to-white distance, WTW).

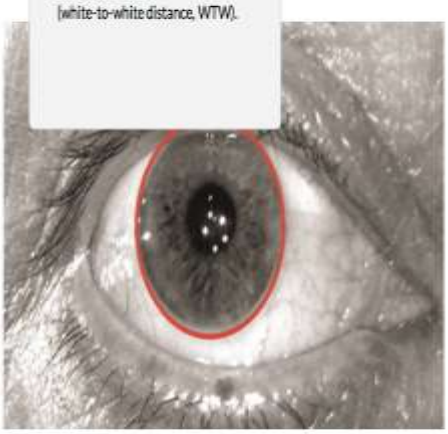

OTHER POSSIBLE EXAMINATIONS

BULBAR REDNESS CLASSIFICATION

Detected the fluidity of the blood vessels of the conjunctiva, evaluating the degree of redness, it will be possible to compare the classification sheets of the degree of redness of bulbar and limbal.

PUPILLOMETRY

The measurement of pupil diameter has become increasingly important in the field of refractive surgery. Larger scotopic pupil sizes may be partially responsible for the occurrence of postoperative symptoms such as halos, glare, and monocular diplopia.

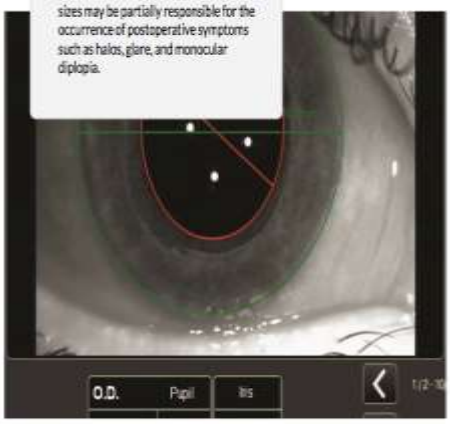

Automated diagnosis ???

Lacrydiag

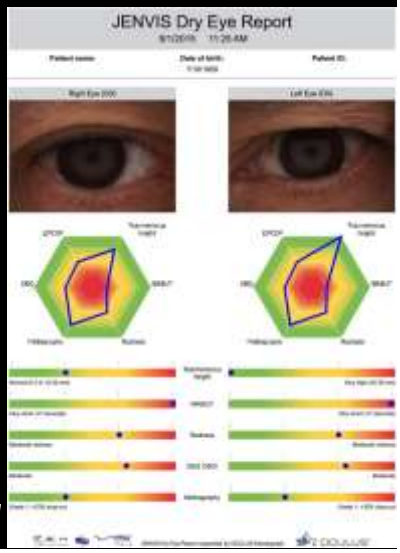

Oculus keratograph 5M

eyecarewithfocus.com

RESULT OF DIAGNOSIS

PDF report

ESCRS
24th ESCRS Winter Meeting
MARRAKECH
In conjunction with SAMIR (Moroccan Society of Implant & Refractive Surgery)
21 – 23 FEBRUARY 2020
Marrakech, Morocco
www.escrs.org