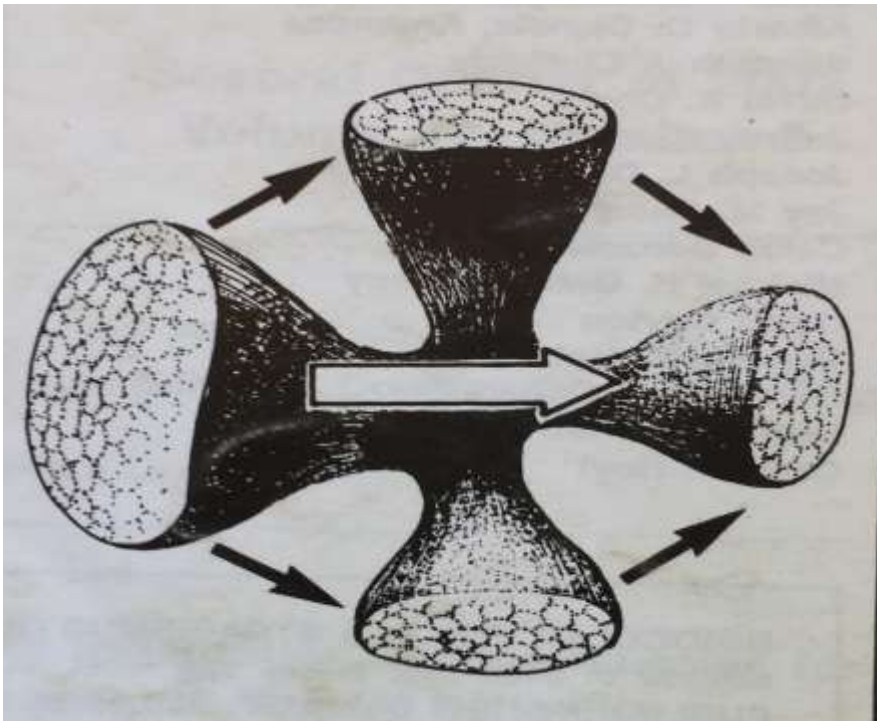


CONSECUTIVE EXOTROPIA AFTER SURGICAL TREATMENT OF RESTRICTIVE AND PARALYTIC STRABISMUS

By ElSayed Eltoukhi, MD
EOS September 2018



ABSTRACT

- Restrictive and paralytic strabismus may be indicative for surgery in selected cases.
- Consecutive deviations whether esotropia or exotropia may occur.
- The proper diagnosis and management depends on the proper preoperative evaluations.
- In all situations the goal of treatment is to improve the binocular functions of the patients and in sometimes particularly in paralytic cases create matching weakness in the other eye and minimizing the creation of new deviations.

CONSECUTIVE EXOTROPIA IN RESTRICTIVE STRABISMUS (E.G. DUANE'S RETRACTION SYNDROME "DRS")

- **A- Unilateral Eso Duane:**
surgical plan depends on:
 - The magnitude of esotropia in primary position.
 - The degree of limited abduction .
 - The degree of Co-contraction .
 - Presence of Up-shoot or Down-shoot.
 - Binocular field of Vision.
- For deviations Up to 20 prism diopter: Single medial rectus recession is still the classical Rx.

- **B- Bilateral esotropic DRS:**

not so common . Sometimes met with in long standing cases . The surgical treatment is possible but experience has shown that BMR is the preferred method of treatment .

- **C. globe retraction and overshoots:**

-when esotropia is present recess the medial more . When orthotropia is present recess the lateral more.

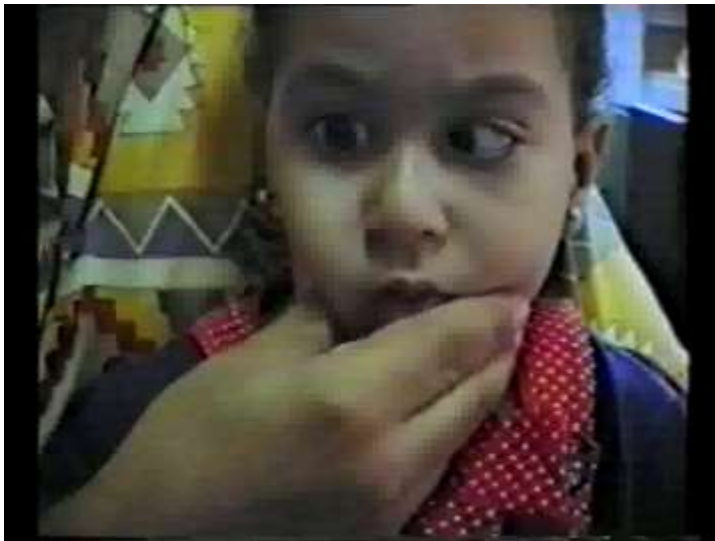○ **D- Co-contraction :**

signs:

- narrowing of the palpebral fissure of more than 1.5 mm with a noticeable enophthalmos on adduction.
- Exotropia on contralateral gaze .
- Remote near point of convergence .
- Severe Upshoot or downshoot.



VIDEO (PLEASE REFER TO THE PRESENTATION FOLDER)

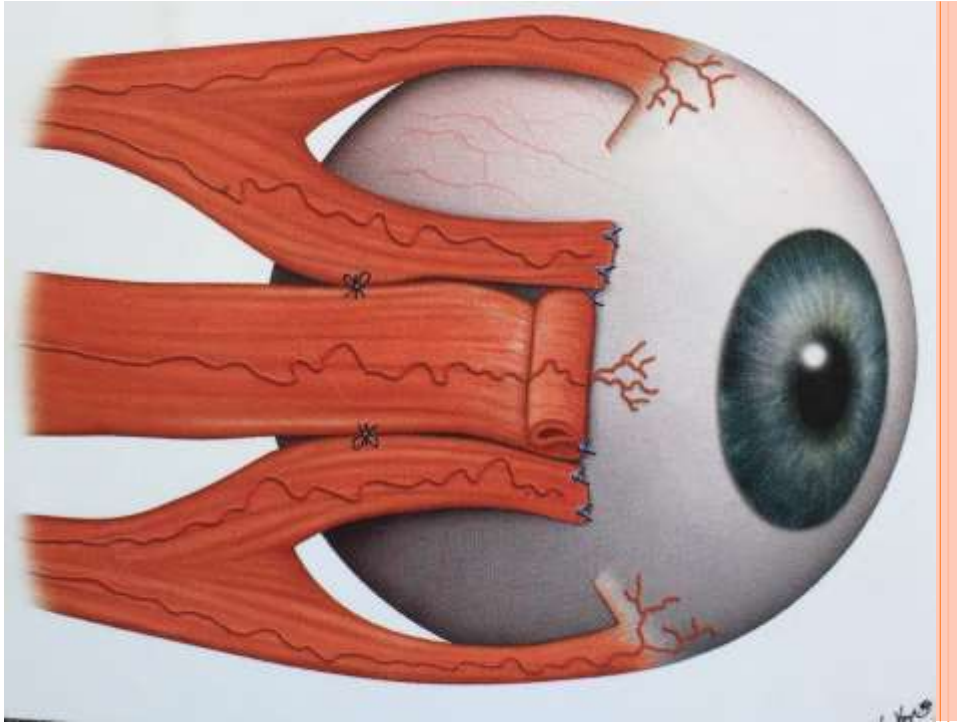


CLINICAL PEARLS

- Bilateral medial rectus recessions are kept for :
 - Large esotropia more than 20 prism diopters.
 - Severe globe retraction.
 - Contracture of the affected medial rectus.

CLINICAL PEARLS

- Forced duction test.
- Muscle elongation test.
- If the above items are normal advance the medial rectus .
- If there is a scar tissue remove any scar tissue .


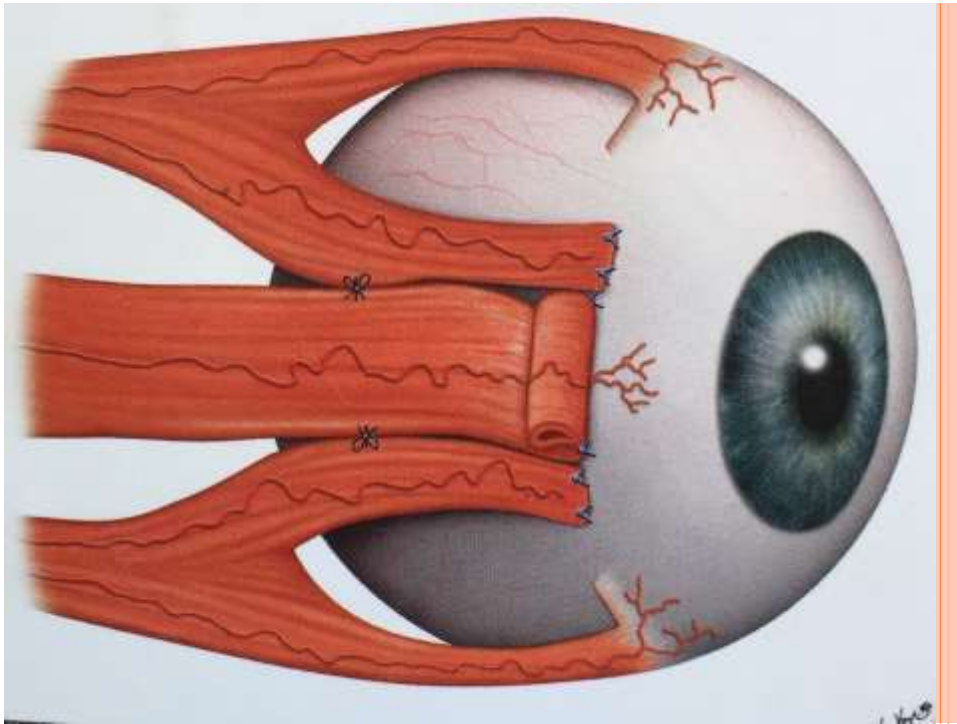


CONSECUTIVE EXOTROPIA IN PARALYTIC STRABISMUS

- The surgical treatment of paralytic strabismus aims at :
 - 1- improving the ocular rotations either through surgery on the affected muscle
 - 2- balancing the deviation by creating a matching weakness of the yolk muscle.
 - 3- minimizing the creation of a new deviation . as Consecutive esodeviations or exodeviations.

Example: 6th nerve palsy.

In milder cases of 6th nerve palsy the examiner should notice where is the greatest deviation in the gaze .



CONCLUSION

- Consecutive exotropia in restrictive and paralytic strabismus are challenging proper pre-operative evaluations are needed .
- Multiple diagnostic sessions are necessary in order to achieve satisfactory results .

- In mechanical restrictions recession of the medial rectus should be very prudent not exceeding 6 mm , guided by the forced duction test FDT and the muscle elongation test. In paralytic strabismus deliverate recessions of the medial rectus should be very cautious although it is necessary to achieve laxity of the globe but Botulinum toxin and or Fooster sutures can save the medial recti and prevent consecutive deviations. (that is in 6th nerve palsy while in other paralytic cases resection of the paralyzed muscle or adding a matching weakness to the Yolk muscle (Fadden's sutures) can prevent the occurrence of **consecutive deviations**.



THANK YOU